

Fixing a Traumatic Sternal Fracture Using Stainless Steel Wires

Hussein Elkhayat,^{1,*} and Hager Nousseir²

¹Department of Cardiothoracic Surgery, Faculty of Medicine, Assiut University Heart Hospital, Assiut University, Assiut, Egypt

²Department of Chest Diseases, Assiut Police Hospital, Assiut, Egypt

*Corresponding author: Hussein Elkhayat, Department of Cardiothoracic Surgery, Faculty of Medicine, Assiut University Heart Hospital, Assiut University, Assiut, Egypt. Tel: +20-882413773, Fax: +20-88233327, E-mail: dr_khayat@hotmail.com

Received 2015 February 26; Accepted 2015 June 28.

Keywords: Thoracic Injuries, Sternum, Fracture Fixation, Internal

Dear Editor,

Traumatic sternal fractures occur in approximately 3% to 8% of all blunt chest trauma cases (1). They generally heal with conservative treatment, but sometimes surgical fixation is necessary. There are several ways to repair them; however, the optimal surgical treatment for unstable sternal fractures is controversial (2).

Although the fixation may occur using wires, a sternal lock plating system or non-specific plate (2), provides a simple method of closure in simple interrupted or illustration-8 fashion (Figure 1). It is likely easier than the above mentioned methods to perform, readily available, and can be removed quickly if required in a life-threatening situation.

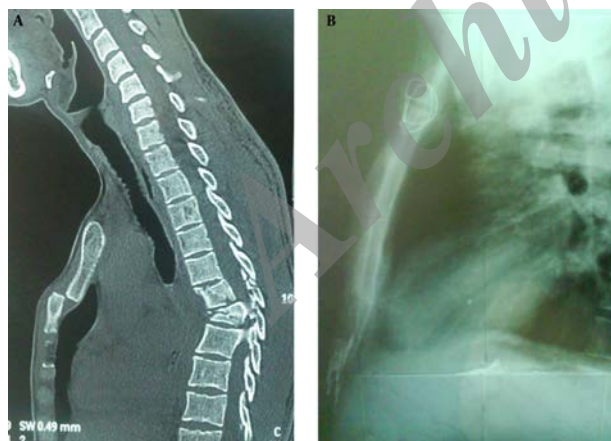


Figure 1. A, Sagittal CT scan chest showed a displaced fracture sternum at the manubriosternal junction (note the associated fracture dorsal spine); B, A postoperative chest X-ray shows a successful reduction and fixation using two simple stainless steel wires.

In addition, because of the proximity of the skin and lower profile of wires, it is less likely to cause patient discomfort and skin related complications. In fact, this is why

we consider osteosynthesis with wires the first choice for treatment of sternal fractures.

Possible Indications and Timing for Sternal Fracture Fixation

Reported indications for fixation are variable as reports started with cosmetic reasons (1) then expanded to include the severity of the fracture and the difficulty of weaning patients from mechanical ventilation. The timing of fixations was classified as either immediate (occurring within a month after the injury) or chronic (performed at least 3 - 6 months after nonunion diagnosis). The decision to perform an immediate or delayed fixation was largely determined by the comfort and confidence of the surgeon (3). We postulate a modified classification taking into consideration the associated injuries, together with the severity of the fracture.

Immediate or During the Initial Admission

Emergency Operation

- Sternal hematoma with possible internal mammary vessels injury,
- Pericardial collection.

Elective Operation

- A displaced or overlapping fracture that cannot be corrected by closed reduction,
- Sternal instability,
- Difficulty weaning from a mechanical ventilator,
- Severe pain, making respiration difficult.

Delayed

- Chronic pain,
- Fracture nonunion,
- Cosmetic reason.

General Considerations

- Echocardiography is an important preoperative workup to exclude pericardial collection.
- General anesthesia with epidural catheter,
- Supine position with a sandbag below the patient's shoulders.
- Examination under general anesthesia of the fracture site and the adjacent costochondral joints,
- Midline incision over the site of the fracture (usually 10 cm long),
- Raising a pectoralis muscle flap on both sides of the fracture to buttress the sternum,
- Identification of the fracture site,
- Use a malleable metal tongue retractor to raise the inner plate of the sternum and protect the heart and great vessels during insertion of the stainless steel wire's needle.
- Using an illustration of eight stitch or simple one stitch according to the degree of displacement and available space to approximate ([Figure 2](#)).

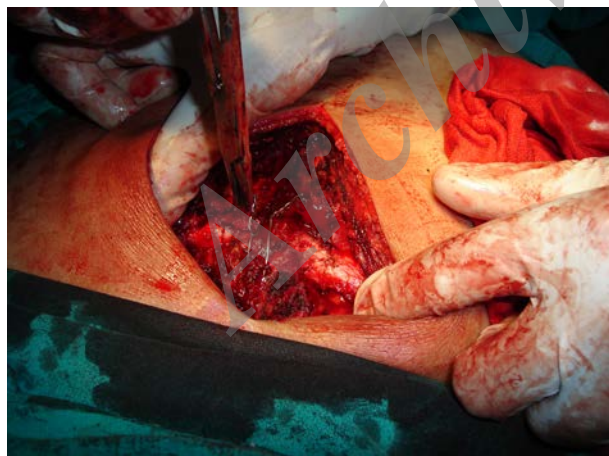


Figure 2. Intraoperative Photo of the Fracture Site With Two Simple Wires in Place

- In cases of comminuted fractures or where sliding fracture edges are reaching the inner plate of the sternum, where it will be difficult or lead to losing parts of the outer plate, one can use a No.2 delayed absorbable suture passing from the outer plate and coming up at the marrow of the

sternum without reaching the inner plate. This is likely to be less effective than a full thickness wire suture but with a buttressing of the muscle flap, one can achieve satisfactory results.

- Adjacent costochondral fractures are best sutured using delayed absorbable sutures with approximation of the two ends gently to prevent perichondrial injury.

- Put a suction drain of appropriate size just above the sternum unless you put a chest tube for the already-opened pleura during the operation.

- We routinely use a topical antibiotic above the sternum to guard against mediastinitis.

- Closure of muscle flaps in the midline to reinforce the fracture site,

- Closure of the subcutaneous tissue and skin,

- Extubation on a tabulation is the target unless there is associated lung contusion or other injuries requiring mechanical ventilation.

- Drain usually removed after 48 hours,

- Patient is discharged home after control of pain and removal of epidural catheter and drain.

References

1. Athanassiadi K, Gerazounis M, Moustardas M, Metaxas E. Sternal fractures: retrospective analysis of 100 cases. *World J Surg.* 2002;**26**(10):1243-6. doi: [10.1007/s00268-002-6511-5](https://doi.org/10.1007/s00268-002-6511-5). [PubMed: [12181604](https://pubmed.ncbi.nlm.nih.gov/12181604/)].
2. Ergene G, Tulay CM, Anasiz H. Sternal fixation with nonspecific plate. *Ann Thorac Cardiovasc Surg.* 2013;**19**(5):364-7. [PubMed: [23269267](https://pubmed.ncbi.nlm.nih.gov/23269267/)].
3. Harston A, Roberts C. Fixation of sternal fractures: a systematic review. *J Trauma.* 2011;**71**(6):1875-9. doi: [10.1097/TA.0b013e31823c46e8](https://doi.org/10.1097/TA.0b013e31823c46e8). [PubMed: [22182898](https://pubmed.ncbi.nlm.nih.gov/22182898/)].