



A Rare Cause of Fetal Neck Mass: Cervical Lymphangioma

Hicran Acar¹, Işıl Turan Bakırcı¹, Basak Baksu¹, Orkun Cetin^{2*}, Mertihan Kurdoglu³

Abstract

Introduction: Fetal neck masses are rare. In general, cystic hygroma is the most frequent form of fetal neck masses. It is essential to differentiate between different pathologies since this will affect prenatal counselling, antenatal and postnatal management. We aimed to present a case of cervical lymphangioma who was referred to our perinatology outpatient clinic with a diagnosis of an occipital encephalocele.

Case Presentation: A 26-year-old nulliparous woman was referred to our perinatology clinic at 38 weeks' gestation with an ultrasound diagnosis of occipital encephalocele so that postnatal surgery could be planned at our hospital. During obstetric ultrasonography examination, we identified a 4.7×4.5 cm, multiloculated cystic mass on the left lateral side of the fetal neck. The provisional diagnosis was lymphangioma. Fetal magnetic resonance (MR) revealed a multiloculated cystic mass with smooth contours of 4.5×3.5×3.0 cm in size, originating from the soft tissues of the left side of the neck and it was not connected with the cervical spinal canal. The pathology report confirmed cervical lymphangioma.

Conclusions: We would like to highlight the importance of differential diagnosis and follow up scans for any neck mass identified during scan to reach the final accurate diagnosis. This will enable that fetal neck masses could be diagnosed correctly in a more cautious manner.

Keywords: Differential diagnosis, Fetal, Differential diagnosis, Lymphangioma

Introduction

Fetal neck masses are rare and they are divided into two groups by their anatomic locations such as anterior and posterior neck masses (1). In general, cystic hygroma is the most frequent form of fetal neck masses. When localization is considered, the possible differential diagnosis for anterior neck masses include goiter, teratoma, hemangioma, and epignathus and those of a posterior cervical mass include occipital encephalocele, cervical teratoma, cervical lymphangioma, and cervical hemangioma (2).

It is essential to make differential diagnosis between varied pathologies because this will affect prenatal counselling, antenatal and postnatal management. Differentiating the various neck masses and reaching a final accurate diagnosis is a challenge since fetal neck masses may not be apparent during the second trimester. Even though a diagnosis is made during the anomaly scan, it should be pursued with serial scans to make sure that the diagnosis is correct since this will affect antenatal counselling and prognosis as well as the mode of delivery and postnatal management.

Here, we present a case of cervical lymphangioma who was referred to our perinatology outpatient clinic with a diagnosis of an occipital encephalocele to be planned for postnatal surgery. By presenting this case, we would like

to highlight the importance of differential diagnosis and follow up scans for any neck mass identified during scan to reach the final accurate diagnosis. This will enable that fetal neck masses could be diagnosed correctly in a more cautious manner.

Case Presentation

A 26-year-old nulliparous woman was referred to our perinatology clinic at 38 weeks' gestation with an ultrasound diagnosis of occipital encephalocele so that postnatal surgery could be planned at our hospital. She had regular antenatal visits in another medical center. The mass at the neck was first diagnosed at 18 weeks' gestation. It was reported as a 43×38mm cystic mass on fetal neck posterolaterally. Amniocentesis was done in the indication of the neck mass diagnosed as occipital encephalocele. The karyotype was normal. During obstetric ultrasonographic examination, we identified a 4.7×4.5 cm, multiloculated cystic mass on the left lateral side of the neck extending posteriorly (Figure 1a). The mass had thin walls without any solid or echogenic areas and was not connected with intracranial and neural tissues. Vascularity was not increased. There were no other major or minor structural anomalies. The amniotic fluid index was normal. The diagnosis of an occipital encephalocele was then questioned due to absence of

Received 20 May 2015, Accepted 7 October 2015, Available online 1 January 2016

¹Department of Obstetrics and Gynecology, Zeynep Kamil Education and Research Hospital, Istanbul, Turkey. ²Department of Obstetrics and Gynecology, Faculty of Medicine, Yuzuncu Yil University, Van, Turkey. ³Department of Obstetrics and Gynecology, Faculty of Medicine, Gazi University, Ankara, Turkey.

*Corresponding author: Orkun Cetin, Yuzuncu Yil University Faculty of Medicine, Obstetrics and Gynecology, Van, Turkey. Tel: +904322150407, Email: drorkuncetin34@hotmail.com



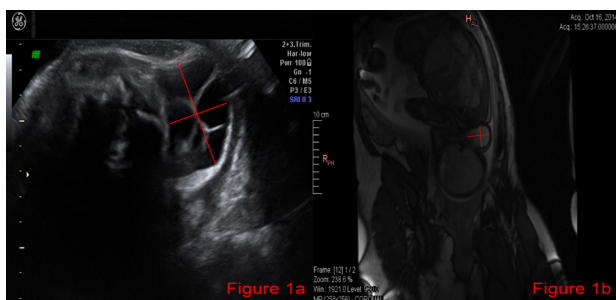


Figure 1. a) A multiloculated cystic mass of 47×45 mm in size on the left lateral side of the neck extending posteriorly. The mass had thin walls without any solid or echogenic areas present. b) Fetal MR revealed a multiloculated cystic mass with well defined, smooth counters of 4.5×3.5×3.0 cm in size originating from the soft tissues of the left side of the neck at the level of cranium and cervical vertebrae extending posteriorly up to the cervical spine showing no continuation with cervical spinal canal.

any skull or cervical bone defect and lack of any solid structure in the cystic mass. Our provisional diagnosis was lymphangioma. After consultation with pediatric surgeons, a fetal magnetic resonance imaging (MRI) was planned. Fetal MR revealed a multiloculated cystic mass with smooth counters of 4.5×3.5×3.0 cm in size, originating from the soft tissues of the left side of the neck and it was not connected with the cervical spinal canal (Figure 1b). The fetus was delivered by cesarean section due to risk of rupture of the cystic mass at a gestational age of 39 weeks. Birthweight was 3600 g. On neonatal examination, a cystic, 4.5 cm soft mass was identified on the left side of the neck. On the postpartum second day the neonate was operated without any complications and externalized on the third postoperative day. The pathology report confirmed cervical lymphangioma.

Discussion

While evaluating fetal neck masses, the first step should be subdivision of the neck mass by its anatomic location into anterior or posterior. Once the mass is exactly localized, identifying ultrasonographic structures of the lesion should be carried out. The differentiating features that should be considered are the nature of the mass like solid, cystic or mixed, the wall thickness, its blood supply or vascularization, the presence of any calcifications, septations or loculations, the laterality (unilateral or bilateral), and presence of any communication with the intracranial and/or spinal neural structures (1). In all cases identified as neck masses, searching for any other fetal anomalies, evaluating the amniotic fluid volume, looking for the presence of hydrops and noting the fetal neck position should also be carried out. Only by such a systematic and thorough approach, the ultrasound diagnosis of fetal neck masses can be most accurate.

The most common form of fetal neck mass is cystic hygroma characterized by its easily distinguishable cystic structure with thin walls and septations, without any calcification or vascularization. Cystic hygromas are bilateral, usually detected in the first trimester (2).

The current case was the firstly diagnosed as an occipital encephalocele. However, as it is evident the subdivision of localization as ‘anterior’ or ‘posterior’ is not descriptive enough for differentiating between lesions since neck masses can originally be laterally localized. Therefore, further localization as ‘lateral’ should also be included in the subdivision. Furthermore, occipital encephaloceles have thick walls and no septations, but may have both solid and cystic components. Usually, they are located posteriorly in the midline and may be accompanied with a bony defect in the calvarium (1). However, in this case, the cystic mass was unilateral, localised on the left side of the neck extending towards the posterior neck, had thin walls without any solid components. Therefore, fetal MRI was planned to confirm prenatal diagnosis. Ancillary investigations like MRI may be useful in the differential diagnosis of a fetal neck mass, especially for conflicting previous diagnosis or inadequate ultrasound examination. The fetal neck lesion turned out to be a multiloculated 4.5 ×3.5×3.0 cm cystic mass with smooth counters originating from the soft tissues of the left side of the neck at the level of cranium and cervical vertebrae without any continuation to the intracranial or cervical neuronal structures.

Generally, cystic masses of fetal neck are referred to as cystic hygromas. These fetuses usually have poor perinatal outcomes. Cystic hygromas are more common during the first trimester. They may be associated with fetal aneuploidies. Even though the fetal karyotype is normal, there is still risk for structural anomalies, intrauterine fetal demise and syndromes like Noonan syndrome with postnatal signs and symptoms (3). The poor perinatal outcome is related to increased aneuploidy risk, hydrops and intrauterine death in fetus with cystic hygroma during the first trimester. Cystic hygroma may regress or progress into generalized hydrops. Even though death is inevitable in several hydropic fetuses, there are reports of complete resolution of hydrops in some cases (4,5). As pregnancy advances, fetal outcome becomes unclear. Some case series reported better fetal outcomes in those with normal karyotype and without any structural defects (6-8). Noia et al reported 156 cystic hygromas with complete follow up of 85 cases. Spontaneous abortion occurred in 54 of these and 31 delivered. Good prognosis was observed in 21 cystic hygromas (9). Termination should not be offered in fetuses with normal karyotype before searching for any other fetal anomalies. Counselling about inconclusive prognosis should be given when karyotype is normal and no other anomaly is found.

In conclusion, even though fetal neck masses are rare, accurate diagnosis is crucial to plan for counselling, antenatal follow up and postnatal management. To differentiate among other pathologies that appear as fetal neck masses, after establishment of location as anterior, posterior or lateral, ultrasonographic structural architecture of the mass like cystic, solid or mixed, presence of septations, its vascularization and its association with neural structures should all be carefully evaluated before reaching a final ultrasound diagnosis.

Furthermore, serial scans should be done to make sure that the ultrasound diagnosis is correct. Otherwise, an occipital encephalocele like in this case report might turn out to be cervical lymphangioma after birth which requires a completely different counselling, antenatal and postnatal management and prognosis. This meticulous approach together with ancillary investigations like karyotyping and MRI will make it possible to correctly reach an accurate ultrasound diagnosis to counsel the patient about follow up, management and prognosis of condition. Moreover, fetal neck masses require a multidisciplinary team including perinatologists, neonatologists and pediatric surgeons to make sure the best outcome possible.

Ethical issues

The authors have obtained permission before using patient data and images.

Conflict of interests

The authors declared that there is no conflict of interests regarding the publication of this article.

Financial support

The authors declared that this study had received no financial support.

Acknowledgments

None to be declared.

References

1. Rauff S, Kien TE. Ultrasound diagnosis of fetal neck masses: a case series. *Case Reports Obstet Gynecol* 2013;2013:243590. doi:10.1155/2013/243590.
2. Paladini D, Volpe P, eds. *Ultrasound of congenital fetal anomalies*. Florida, USA: CRC Press; 2014:137-41.
3. Nicolaides KH, Heath V, Cicero S. Increased fetal nuchal translucency at 11-14 weeks. *Prenat Diagn*. 2002;22:308-15. doi:10.1002/pd.308.
4. Izquierdo L, Kushnir O, Sanchez D, et al. Prenatal diagnosis of Noonan's syndrome in a female infant with spontaneous resolution of cystic hygroma and hydrops. *West J Med*. 1990;152(4):418-21.
5. Cohen MM, Schwartz S, Schwartz MF, et al. Antenatal detection of cystic hygroma. *Obstet Gynecol Surv*. 1989;44(6):481-490.
6. Bernstein HS, Filly RA, Goldberg JD, Golbus MS. Prognosis of fetuses with a cystic hygroma. *Prenat Diagn*. 1991;11(6):349-55. doi:10.1002/pd.1970110603.
7. Boyd PA, Anthony MY, Manning N, Rodriguez CL, Wellesly DG, Chamberlain P. Antenatal diagnosis of cystic hygroma or nuchal pad—report of 92 cases with follow up of survivors. *Arch Dis Child Fetal Neonatal Ed*. 1996;74:F38-42. doi:10.1136/fn.74.1.F38.
8. Cullen MT, Gabrielli S, Green JJ, et al. Diagnosis and significance of cystic hygroma in the first trimester. *Prenat Diagn*. 1990;10(10):643-51. doi:10.1002/pd.1970101004.
9. Noia G, Pellegrino M, Masini L, et al. Fetal cystic hygroma: the importance of natural history *Eur J Obstet Gynecol Reprod Biol*. 2013;170(2):407-413. doi:10.1016/j.ejogrb.2013.07.043.

Copyright © 2016 The Author(s); This is an open-access article distributed under the terms of the Creative Commons Attribution License (<http://creativecommons.org/licenses/by/4.0>), which permits unrestricted use, distribution, and reproduction in any medium, provided the original work is properly cited.