



Mirena in Two-Dimensional Ultrasound

Burcin Karamustafaoglu Balci^{*}, Ahmet Gocmen¹

Dear Editor,

Recently, a case report describing a woman who had two Mirena intrauterine devices (IUDs) in uterine cavity is published (1). The patient was suffering from heavy menstrual bleeding. Clinical and ultrasound examinations, laboratory tests, cervical cytology and endometrial biopsy were normal and a Mirena IUD was inserted. Six months later, she still had the same complaints. Ultrasound scan was performed and no Mirena IUD was seen in uterine cavity. A new Mirena IUD was inserted. She did not recover and admitted to another clinic where three-dimensional (3-D) ultrasound scan revealed the presence of two Mirena IUDs. The levonorgestrel intrauterine system (LNG-IUS), often referred to by its brand name Mirena, has been approved by the Food and Drug Administration (FDA) and has been used till early nineties in many countries. Mirena has a 32 mm T-shaped polyethylene frame that releases 20 µg of progestin (levonorgestrel) daily for up to 5 years. In contrast to a copper IUD, the visualization of a Mirena IUD by ultrasound is not straightforward. The two-dimensional (2-D) transvaginal ultrasonography (TVS) is the primary method for the evaluation of the location of Mirena. The absence of copper, leads to the lower image quality visualization, therefore, the imaging of Mirena needs more operator's skills. When 2-D TVS fails, or when patients carrying Mirena have symptoms, as is seen in the case report, other diagnostic modalities are recommended. These are three-dimensional ultrasound, x-ray of the pelvis, computed tomography or magnetic resonance imaging. The use of 3-D TVS clearly display the entire LNG-IUS and its relation to the uterine cavity. Three-dimensional ultrasound has been even found to be better than 2-D ultrasound for locating and adequately visualizing levonorgestrel IUDs (2). However, many of physicians have access only to 2-D ultrasound, so, the visualization of Mirena by 2-D ultrasound is crucial. The sonographic appearance of Mirena IUDs includes both proximal and distal ends of the vertical arm of the device, which extend into the fundal region and internal cervical os, and an acoustic shadowing between both ends which defines the location of the device (3-4) (Figure 1). The proximal and distal ends are echogenic and the hormone cylinder does not show a clear audi-

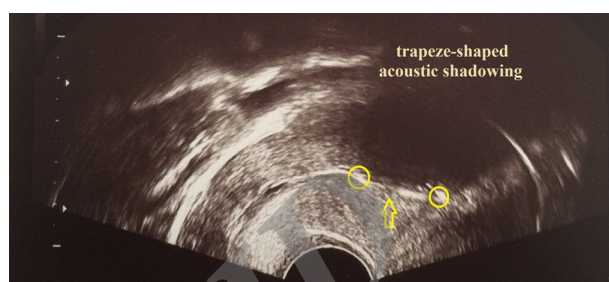


Figure 1. Sonographic Image of Mirena IUD on 2-D Transvaginal Ultrasound. The yellow circles are showing the ends of Mirena and the arrow is showing hormone cylinder.

tory reflex, in consequence, only a typical trapeze-shaped acoustic shadowing can be seen between the echogenic ends (Figure 1).

Clinicians have to be careful during the evaluation of the patients with Mirena IUD to prevent such situations that no one would desire.

Ethical Issues

Not applicable.

Competing Interests

Authors declare that they have no competing interests.

References

1. Granberg S. Are two intrauterine contraceptive devices better than one? *Ultrasound Obstet Gynecol.* 2014; 44:121.
2. Andrade CM, Araujo Júnior E, Torloni MR, Moron AF, Guazzelli CA. Three-dimensional versus two-dimensional ultrasound for assessing levonorgestrel intrauterine device location: a pilot study. *J Clin Ultrasound.* 2016;44(2):72-77. doi:10.1002/jcu.22276.
3. Palo P. Transabdominal and transvaginal ultrasound detection of levonorgestrel IUD in the uterus. *Acta Obstet Gynecol Scand.* 1997;76:244-247.
4. Zalel Y, Kreizer D, Soriano D, Achiron R. Sonographic demonstration of a levonorgestrel-releasing IUD (Mirena). *Harefuah.* 1999;137(1-2):30-1.

Copyright © 2016 The Author(s); This is an open-access article distributed under the terms of the Creative Commons Attribution License (<http://creativecommons.org/licenses/by/4.0>), which permits unrestricted use, distribution, and reproduction in any medium, provided the original work is properly cited.

Received 2 August 2015, Accepted 10 February 2016, Available online 25 February 2016

¹Department of Obstetrics and Gynecology, Goztepe Education and Research Hospital, Istanbul Medeniyet University, Istanbul, Turkey.

***Corresponding author:** Burcin Karamustafaoglu Balci, Goztepe Egitim ve Arastirma Hastanesi, Goztepe, Kadikoy, Istanbul, Turkey.

Tel: +90 2165664000, Email: burcinkaramustafaoglu@yahoo.com

