



## The effect of crocin on hippocampal lipid peroxidation and histopathology following intracerebroventricular injection of colchicine in the rat

Ensie Azadi-Ahmadabadi<sup>1</sup>, Zahra Kisolari<sup>2</sup>, Farzane Fereidoni<sup>1</sup>, Shahrame Jalalzade Ogvar<sup>1</sup>, Mehrdad Roghani<sup>2\*</sup>

1. Department of Physiology, School of Medicine, Shahed University, Tehran, Iran
2. Neurophysiology Research Center, Shahed University, Tehran, Iran

### Abstract

**Background and Objective:** Colchicine is a neurotoxin substance. Its intraventricular injection causes oxidative stress, inflammation, destruction of cholinergic and glutaminergic neurons and consequently impairs memory and learning. Crocin is an effective ingredient in saffron that has antioxidant and anti-inflammatory potential with beneficial effects on memory and learning. This study investigated the effect of crocin on lipid peroxidation and histological changes of the hippocampus following intracerebroventricular injection of colchicine in the rat.

**Materials and Methods:** 40 male rats were randomly divided into 5 groups as follows: 1-Sham, 2- Sham + crocin at a dose of 50 mg/kg, 3- Colchicine, 4- Colchicine + crocin at a dose of 10 mg/kg, and 5- Colchicine + crocin at a dose of 50 mg/kg. Cognitive disorder was induced by injection of colchicine bilaterally into the brain ventricles through stereotaxic surgery. Crocin was daily administered 2 days before surgery till day 7 after the surgery. In the third week after the surgery, malondialdehyde (MDA) was evaluated in hippocampal homogenate. The number of neurons was also studied by Nissl staining in CA1 and CA3 regions.

**Results:** The results showed that crocin treatment at a dose of 50 mg/kg significantly reduced MDA. Histopathological assessment did not show significant changes regarding neuronal number.

**Conclusion:** The findings of this study indicate the dose-dependent effect of crocin in reduction of hippocampal MDA following intracerebroventricular injection of colchicine in the rat. However, it is not effective regarding number of hippocampal pyramidal neurons after colchicine challenge.

**Keywords:** Crocin, Colchicine, Malondialdehyde, Hippocampus

## 1. Introduction

Colchicine is a lipid-soluble alkaloid with a long half-life, between 20 to 40 hours (1, 2). It is extracted from plants like those in the genus *colchicum* (2, 3). Colchicine has remedial application for gout and familial Mediterranean fever (1-3). Intracerebroventricular (i.c.v.) injection of colchicine causes strong neurodegeneration and neuroinflammation in the hippocampus of rats (4). Colchicine is also reported to be neurotoxic as it binds to tau proteins, resulting in disruption of microtubules. As a result, axoplasmic flow is affected and normal activity of the neurons gets seriously jeopardized in a manner that may result in neuronal death (4).

Toxicities of colchicine are well-known by production of free radicals and inducing oxidative stress, degeneration of cholinergic neurons, and increasing amyloid beta (5). Colchicine increases beta amyloid precursor, thereby increasing the activity of microglia and increasing the reactive oxygen species and nitrogen (4). Reactive oxygen species cause lipid peroxidation and end-products such as malondialdehyde (6, 7). Colchicine can increase tissue malondialdehyde (8).

Flavonoids have been used in traditional medicine to promote human health. Traditional medicine has shown that natural flavonoids protect the nerve cells by reducing oxidative stress activity and are recognized as a candidate for the production of new

neuronal drugs. Saffron, scientifically called *Crocus sativus* L., has been suggested in traditional medicine for the treatment of various diseases. Recent studies have shown that saffron has anti-depressant, anticoagulant, and anti-hypertensive properties and it has also beneficial effects on improving cognitive function in adult rodents. Saffron has also the ability to inhibit apoptosis. Saffron has several constituents such as polar carotenoids (crocin), small amounts of monotropin aldehydes such as picrocin, safranal, and flavonoids like comferol and crocetin (9). Crocin is a water-soluble carotenoid and its chemical formula is C<sub>44</sub>H<sub>64</sub>O<sub>24</sub>, which is in the form of monoglycosyl or diglycosyl polystyrene crostin. Crocin is a key component of saffron responsible for its red color.  $\alpha$ -crocetin (Crocetin diagentibiose ester) is the main crocin of saffron. Safety studies indicate that  $\alpha$ -crocetin at low doses has no toxic effects. The findings indicated that crocin may be useful against chronic stress induced oxidative damage by decreasing the MDA level as well as increasing the levels of GPx, GR, SOD and total antioxidant capacity. Crocin has effects against neurodegenerative diseases due to its anti-apoptotic, anti-inflammatory, and antioxidant activities with beneficial effects in models of Parkinson's and Alzheimer's diseases (10). This study investigated the effect of crocin on lipid peroxidation and histological changes of the hippocampus following intracerebroventricular injection of colchicine in the rat.

## 2. Materials and Methods

### 2.1. Animals and experimental groups

In this study, 40 male Wistar rats weighing 200-250 g were used. The animals were taken from the Neuroscience Research Center of Shahid Beheshti University of Medical Sciences (Tehran, Iran). They were purchased and kept at the Shahed University animal facility. During the study period, the animals were housed in laboratory cages made of Plexiglass at a temperature of 22-24°C with adequate and free access to water and food during 12 hours of light and 12 hours of darkness. All tests were based on international guidelines and maintenance of laboratory animals and were performed between the hours 08:00 a.m. to 04:00 p.m.

Rats were randomly divided into 5 groups: 1. sham: In this group, healthy mice had stereotaxic surgery and intraventricular aCSF injection. 2. The sham group which received crocin at a dose of 50 mg/kg: Crocin was given orally at a dose of 50 mg/kg two days before the surgery till day 7 after the surgery. 3. Colchicine group: Colchicine was injected intraventricularly and bilaterally at a dose of 15  $\mu$ g to induce disturbance. Injection coordinates were: Anteroposterior: -0.8. Lateral:  $\pm$ 1.2 and Ventral: 3.4-

3.6. and 4.5. Colchicine groups receiving crocin at doses of 10 or 50 mg/kg.

### 2.2. Histochemical study

Three weeks after starting crocin gavage, the animals were deeply anesthetized by intraperitoneal injection of ketamine (150 mg/kg) and transcardial perfusion was done. For this operation, about 100-150 ml of normal saline was circulated in the vessels. The left hippocampal block was homogenized in 0.1 M Tris buffer (pH 7.4) using a homogenizer and its supernatant was used for biochemical measurements. The right hippocampal block was fixed in fixative solution containing 4% paraformaldehyde in 0.1 M phosphorus phosphate (pH = 7.4). After tissue processing, paraffin blocks were prepared from hippocampal block and tissue sections were prepared with microtome (Leica, Germany) at a thickness of 5 micrometer. The sections were stained with 0.1% Cresyl violet.

Number of pyramidal neurons in the CA1 and CA3 regions of the hippocampus per unit area was assessed. For neuronal counts for each rat, at least four slices were selected and analyzed from the central hippocampus according to Atlas of Paxinos and Watson.

### 2.3. Malondialdehyde (MDA) assay

The MDA levels of the supernatant were measured. Briefly, trichloroacetic acid and thiobarbituric acid were added to the supernatant, and then, the mixture was placed in boiling water bath for 90 min. Afterwards, samples were cooled and centrifuged at 1000 rpm for 5 min. The absorbance of the supernatant was read at 532 nm. Standard curves were prepared using tetraethoxypropane.

### 2.4. Statistical analysis

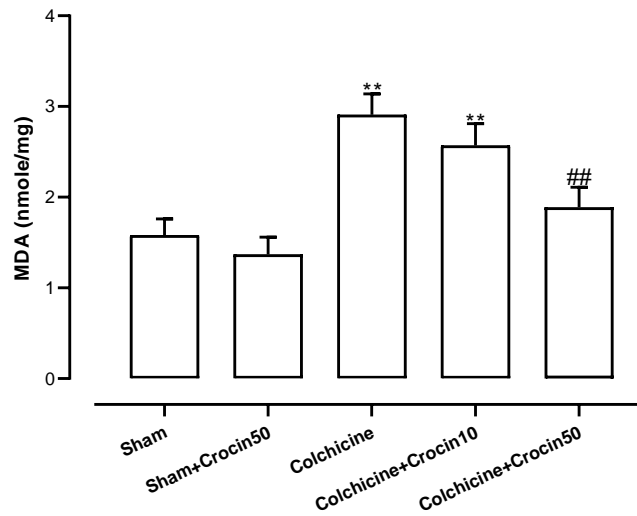
Results in the present study were expressed as Mean  $\pm$  SEM. After checking normality of data distribution using Kolmogorov-Smirnov test, one-way ANOVA and Tukey post-test were used to compare the groups. P values less than 0.05 were considered significant. Statistical analysis of the data and chart drawing were performed using GraphPad Prism software (Version 7).

## 3. Results

### 3.1. Lipid peroxidation results

Figure 1 shows the results of lipid peroxidation MDA level in the hippocampal homogenate of different groups. A slight and non-significant decrease in the sham group treated with crocin was obtained. In the colchicine group, MDA level was significantly increased as compared to the sham group ( $P < 0.01$ ), and in the colchicine group treated with 1mg/kg of crocin, a significant increase of MDA was observed relative to the sham group ( $P < 0.01$ ). In addition, a

significant decrease of MDA was observed in the colchicine group treated with crocin at a dose of 50 mg/kg ( $P < 0.01$ ) versus colchicine group.

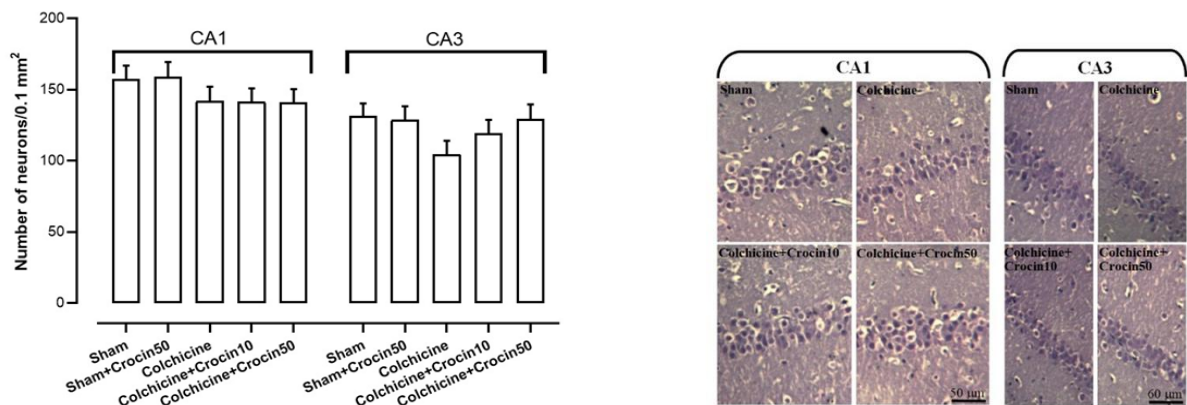


**Figure 1.** Results of MDA level as an index of lipid peroxidation in hippocampal homogenates of rats in different groups. Colchicine was injected intraventricularly (ICV) and bilaterally at a dose of 15  $\mu$ g. Crocin was administered orally at doses of 10 or 50 mg/kg/day two days before surgery till seven days after the surgery. \*\* ( $P < 0.01$ ) compared to sham group, ## ( $P < 0.01$ ) compared to colchicine group.

### 3.2. Histological findings

In figure 2, results of neuronal counting are shown in the CA1 and CA3 regions of the hippocampus. The results showed that in the colchicine group and the colchicine group treated with 10 or 50 mg/kg of crocin in the CA1 region, there was no significant neuronal decrease as compared to the sham group. In addition, in CA3 region, the results showed that there was also

no significant decrease in the number of neurons in the colchicine and crocin-treated groups. There was no significant increase in the number of neurons in the colchicine-treated group at a dose of 50 mg/kg as compared with the colchicine-treated group. Also, no significant changes were observed in CA1 and CA3 areas in the sham group treated with crocin.



**Figure 2.** Counts of CA1 and CA3 pyramidal neurons in the hippocampal area of rats in different groups. Colchicine was injected intraventricularly (ICV) and bilaterally at a dose of 15  $\mu$ g. Crocin was administered orally at doses of 10 or 50 mg/kg two days before the surgery till seven days after the surgery.

### 4. Discussion

Colchicine is a neurotoxin substance which its intracerebroventricular injection causes cognitive impairment. Colchicine increases the expression of beta-amyloid in the brain as well as generating

oxidative stress and inflammation, impairing the cholinergic and glutaminergic systems leading to loss of the neurons and synapses. Colchicine also reduces memory and learning by decreasing acetylcholine transferase and destroying cholinergic neurons (5).

In a study by Awasthi et al, intracerebral injection of colchicine increased the level of malondialdehyde

(lipid oxidation marker) as compared to the control group (11). A study by Jiang et al showed that intraventricular injection of colchicine after 21 days causes tissue damage and could be used as a model for Alzheimer's disease (4). In our study, through intracerebroventricular injection of colchicine, the level of malondialdehyde increased in line with the avalanche study, but no histological changes were observed due to intraventricular injection of colchicine, which may be because our experimental duration was about 21 days.

Research data have shown that flavonoids such as crocin can be used as an effective substance in ameliorating symptoms of cognitive impairment and neuronal damage (9).

In a study by Mohammadi et al (2018), they examined the protective effect of crocin against D-galactose-induced aging in mice. Aging is a multi-factor phenomenon that leads to various diseases and abnormalities in human body. Oxidative stress is an important factor in aging. The aging model in this study was induced by administration of D-galactose at a dose of 500 mg/kg daily for 42 days. D-galactose injection induces lipid peroxidation in brain and liver tissues. Rats were treated with doses of crocin at doses of 10, 20, and 40 mg/kg intraperitoneally during administration of D-galactose. Crocin treatment reduced lipid peroxidation and increased GSH in liver and brain tissues. Consequently, administration of crocin reduces D-galactose-induced senescence in mice by restraining oxidative stress (12). In a study by Moghaddam, crocin was shown to have antioxidant properties (13). Naghizadeh et al in 2013 examined the protective effect of oral crocin against STZ-induced spatial memory decline and oxidative stress. In this experiment, rats were injected with 2 mg/kg of bilateral STZ injection on days 1 and 2. They were

then treated with 1 mg/kg of crocin orally for 2 consecutive days. In this experiment, the cognitive function of the rats was evaluated using Morris water maze method. Mice injected with STZ showed severe memory deficits associated with high levels of malondialdehyde (MDA) and decreased glutathione peroxidase (GPx) activity. Crocin treatment improved cognitive function and significantly decreased MDA levels and increased GPx activity. This study suggests that crocin may have beneficial effects in the treatment of neurological disorders such as Alzheimer's disease (14). Altinoz et al investigated the protective effect of crocin on CCl<sub>4</sub>-induced brain injury in Wistar rats. This study found that carbon tetrachloride reduces glutathione, total antioxidant activity, and catalase activity. Since crocin has potent antioxidant properties, it is able to increase the levels of glutathione and catalase and total antioxidant capacity and to decrease the levels of malondialdehyde and superoxide dismutase activity. In this study, they found that injection of crocin via restraining oxidative stress reduces carbon tetrachloride-induced brain injury (15). Tamaddonfard et al investigated the effect of crocin on STZ induced memory impairment in diabetic mice. The results showed that crocin prevents the loss of hippocampal neurons in diabetic mice and crocin improves STZ induced learning and memory impairment through its anti-hyperglycemic, antioxidant, and neuroprotective effects (16).

To conclude, crocin at a dose of 50 mg/kg significantly reduces the amount of malondialdehyde as a lipid peroxidation by-product. However, it is not effective regarding number of hippocampal pyramidal neurons following colchicine challenge.

## References

1. Altinoz E, et al. Neuroprotection against CCl<sub>4</sub> induced brain damage with crocin in Wistar rats. *Biotech Histochem* 2018; 93(8):623-631. doi: 10.1080/10520295.2018.1519725.
2. Awasthi H, Kaushal D, Siddiqui HH. Chronic inhibition of central angiotensin-converting enzyme ameliorates colchicine-induced memory impairment in mice. *Scientia Pharmaceutia* 2012; 80(3):647-62. doi: 10.3797/scipharm.1203-06.
3. Chalatsa I, Arvanitis DA, Koulakiotis NS, Giagini A, Skaltsounis AL, Papadopoulou-Daifoti Z, et al. The Crocus sativus Compounds trans-Crocin 4 and trans-Crocetin Modulate the Amyloidogenic Pathway and Tau Misprocessing in Alzheimer Disease Neuronal Cell Culture Models. *Frontiers in Neuroscience* 2019; 13:249. doi: 10.3389/fnins.2019.00249. eCollection 2019.
4. Cheignon C, Tomas M, Bonnefont-Rousselot D, Faller P, Hureau C, Collin F. Oxidative stress and the amyloid beta peptide in Alzheimer's disease. *Redox Biology* 2018; 14:450-464. doi: 10.1016/j.redox.2017.10.014.
5. Farkhondeh T, Samarghandian S, Shaterzadeh Yazdi H, F S. The protective effects of crocin in the management of neurodegenerative diseases: a review. *American Journal of Neurodegenerative Disease* 2018; 7(1):1-10. eCollection 2018.
6. Fathimoghadam H, Farbod Y, Ghadiri A, Fatemi R. Moderating effects of crocin on some stress oxidative markers in rat brain following demyelination with ethidium bromide. *Heliyon* 2019; 5(2):e01213. doi: 10.1016/j.heliyon.2019.e01213.
7. Gella A, Durany N. Oxidative stress in Alzheimer disease. *Cell Adhesion and Migration* 2009; 3(1):88-93. doi: 10.4161/cam.3.1.7402.
8. Joy T, Rao MS, Madhyastha S. N-Acetyl cysteine supplement minimize Tau expression and neuronal loss in animal model of

- Alzheimer's disease. *Brain Sciences* 2018; 8(10):185. doi: 10.3390/brainsci8100185.
9. Leung YY, Yao Hui LL, Kraus VB. Colchicine-- Update on mechanisms of action and therapeutic uses. *Semin Arthritis Rheum* 2015; 45(3):341-50. doi: 10.1016/j.semarthrit.2015.06.013.
  10. Mohammadi E, Mehri S, Badie Bostan H, Hosseinzadeh H. Protective effect of crocin against D-galactose-induced aging in mice. *Avicenna Journal of Phytomedicine* 2018; 8(1):14-23. PMID: 29387570
  11. More SV, Kumar H, Cho DY, Yun YS, Choi DK. Toxin-induced experimental models of learning and memory impairment. *International Journal of Molecular Sciences* 2016; 17(9):1447. doi: 10.3390/ijms17091447.
  12. Naghizadeh B, Mansouri M, Ghorbanzadeh B, Farbood Y, Sarkaki A. Protective effects of oral crocin against intracerebroventricular streptozotocin-induced spatial memory deficit and oxidative stress in rats. *Phytomedicine* 2013; 20(6):537-42. doi: 1016/j.phymed.2012.12.019.
  13. Shibli R A, Daradkah NQ, Makhadmeh IM. Colchicine production from colchicum and the role of in vitro cultures: A Review. *Jordan Journal of Agricultural Sciences* 2010; 6(2):208-23.
  14. Sil S, Ghosh R, Sanyal M, Guha D, Ghosh T. A comparison of neurodegeneration linked with neuroinflammation in different brain areas of rats after intracerebroventricular colchicine injection. *Journal of Immunotoxicology* 2016; 13(2):181-90. doi: 10.3109/1547691X.2015.1030804
  15. Slobodnick A, Shah B, Pillinger MH, S K. Colchicine: old and new. *American Journal of Medicine* 2015; 128(5):461-70. doi: 10.1016/j.amjmed.2014.12.010.
  16. Tamaddonfard S, Farshid AA, Asri-Rezaee S. Crocin improved learning and memory impairments in streptozotocin-induced diabetic rats. *Iranian Journal of Basic Medical Sciences* 2013; 16(1):91-100. doi:10.22038/IJBMS.2013.253