

Screening through Temperature and Thermal Pattern Analysis in DMBA - Induced Breast Cancer in Wistar Rats

Evy Poerbaningtyas^{1,2,10*}, Respati S Dradjat³, Agustina T Endharti⁴, Setyawan P Sakti⁵, Edi Widjajanto⁶

ABSTRACT

Background: Based on thermal temperatures around the breast, thermography is considered a promising approach providing information about the condition of the breast without any side effects.

Objective: Using thermography, breast screening is highly dependent on the process of heat recognition. The angular effects in the process of thermal patterns recognition can increase false detection. The effect can be observed in breasts with growing mammary glands. This study aims to develop a system to identify breast conditions through analysis of temperature and thermal patterns.

Material and Methods: In this experimental study, analysis of thermal patterns are performed using the Canny method, specifically detection of anomalies in the breast. Twenty-four *Wistar* female rats were used as experimental animal models with group 1 (normal), group 2 (induced with DMBA), group 3 (rats with growing mammary gland). At the end of 8 weeks, all rats were sacrificed and histopathology analysis was performed. The body temperature was measured every week using the Infrared Camera type TiS20 brand Fluke camera.

Results: Histopathology indicated average temperature of 36.66 °C, 37.77 °C and above 38.87 °C in normal, growing mammary glands, and cancerous breasts, respectively. These results revealed significantly higher heat in breasts with cancerous lesions. In the analysis of thermal pattern recognition for breast, no curve was formed in the normal group, while cancerous and growing mammary glands demonstrated a perfectly closed curve and an imperfect curve pattern, respectively.

Conclusion: Breast screening through the analysis of temperature and thermal patterns can distinguish normal, cancerous and breast with growing mammary glands.

Citation: Poerbaningtyas E, Dradjat RS, Endharti AT, Sakti SP, Widjajanto E. Screening through Temperature and Thermal Pattern Analysis in DMBA - Induced Breast Cancer in Wistar Rats. *J Biomed Phys Eng*. 2021;11(4):505-514. doi: 10.31661/jbpe.v0i0.1229.

Keywords

Rats; Hot Temperature; Breast Neoplasms

Introduction

Cancer is a leading cause of death in the world. According to the estimates of the World Health Organization (WHO), there have been 18.1 million new cases and 9.6 million cancer-related deaths in this year. For humans, cancer has been the biggest barrier to increase the expectancy of life [1].

Reports of breast cancer is high and oncology therapy is an intense and very expensive research subject [2]. Biopsy is one of the techniques for

¹MT, Doctoral Program of Medical Science, Faculty of Medicine, Brawijaya University, Malang, Indonesia

²MT, Department of Informatic, STIKI, Malang, Indonesia

³PhD, Department of Orthopaedic, Saiful Anwar Hospital, Faculty of Medicine, Brawijaya University, Malang, Indonesia

⁴PhD, Department of Parasitology, Faculty of Medicine, Brawijaya University, Malang, Indonesia

⁵PhD, Department of Physics, Brawijaya University, Malang, Indonesia

⁶PhD, Department of Clinical Pathology, Faculty of Medicine, Brawijaya University, Malang, Indonesia

*Corresponding author:
Evy Poerbaningtyas
Doctoral Program of Medical Science, Faculty of Medicine, Brawijaya University, Malang, Indonesia
E-mail: evystudi@gmail.com

Received: 2 August 2019
Accepted: 20 December 2019

diagnosis of breast cancer, which aims to determine the treatment protocol. However, diagnosis using biopsy can cause several harmful side effects to the area examined, such as infection, bruises, damage to blood vessels. These changes may worsen if the patient does not continue treatment after the biopsy, with a possibility of malignant transformation of the lesion [3]. Prevention of breast cancer may be possible through periodic screening of healthy individuals and the early detection of breast cancer needs to be explored.

Screening of breast cancer is based on imaging systems such as mammography. Mammography may be considered the gold standard in early diagnosis of breast cancer owing to the advantages of high specificity (approximately 97%) and the ability to detect nodules of approximately 2 cm in size. Moreover, the procedure is less optimal for women with high-risk of breast cancer and those less than 40 years of age and false positive detection of nodules have also been reported [4-7]. The other common screening modality is MRI associated with disadvantages relating to the electromagnetic field, which can increase the temperature of the breast by approximately 0.3 °C, thereby raising the risk of development of cancer and inaccurate results. The technique may also cause allergic reaction due to use of dyes. These tests cannot distinguish between cancerous and non-cancerous lesions, but can detect objects appearing potentially cancerous [8, 9]

Owing to the disadvantages of mammography and MRI, a new and safer modality known as thermography has been introduced for screening of breast cancer. Thermography has been as an “adjunctive” tool used in conjunction with primary tests such as, mammography. The technique uses infrared sensors to detect heat and increased vascularization (angiogenesis) as the byproduct of biochemical reactions. The heat data is compiled into an image for computer analysis. The application of thermography in the diagnosis of

breast cancer is non-invasive and not associated with post-test side effects [6]. Infrared (IR) thermography has several advantages, for example, detection of breast abnormalities prior to development of cancer, identification of breast regions to ensure subsequent monitoring based on clinical evidence. Therefore, IR thermography also plays a role in screening of breast cancer. IR imaging technology has been advanced significantly from the original clinical assessments, but it's sufficient to diagnose cancer as a stand-alone test [10]. One study reported that the screening results using thermography showed 97% accuracy compared to mammography and MRI, which have 96.1% and 95.8%, respectively, which indicates superior sensitivity and specificity of thermography [11].

Symptoms of breast cancer include wrinkling, leakage of fluid from the nipple and changes in skin color and temperature around the breast associated with tissue metabolism and vascularization of the underlying tissue. An increase in temperature of the breast is indicative of breast tissue abnormalities. In normal breast tissue, heat conductivity is represented by an increase in temperature of the skin, whereas in breast cancer, lesions under the surface of skin produce more heat and subsequently increase blood flow [12].

The amount of heat in the region of the breast cancer/in the breast cancer lesion changes over time. Salhab *et al.*, collected heat data every five minutes, for 48 hours and analyzed the outcomes using statistical software SPSS 25(. The resultant graph demonstrated that there is change in heat due to changes in metabolism in every one unit graph [13]. Thermography has been used in screening of cancer based on the principle of higher metabolic activity and blood flow around cancerous than normal tissue. IR thermography is a promising technology for detection of breast cancer. Therefore, it can be used as an imaging technique to improve the efficiency of detection of breast cancer [14]. The use of thermography to classify

normal and abnormal breasts using curvelet-based texture feature approaches, can improve classification efficiency when compared with statistical features [15].

Limitations of the process of screening breast cancer using thermography displays a thermal pattern. The produced pattern is a multiresolution image, which does not have a clear edge (effect corner), particularly heat patterns caused by inflammation or mammary glands in the breast, resulting in inconsistency or false detection of lesions (false positive or negative) [16, 17]. In the present study, we aimed to identify the heat region on cancerous breasts using the edge of the heat pattern.

Segmentation or edge detection methods can be used to detect all edges or lines to form the image of an object. The purpose of edge detection is to identify objects in the image. The Canny method is able to reduce noise prior to edge detection minimizing the occurrence of corner effects in the multi-resolution process [18]. The use of Canny edge detection for image segmentation or feature extraction can increase the accuracy of pattern recognition. This approach can visually aid in segmentation of the thermal pattern, thereby enabling classification of the patterns.

Material and Methods

Materials

Animal Model

In this experimental study, breast screening was used an animal models of Wistar female rats. The experiment was carried out with 1.2 - 1.5-month-old rat purchased from Parasitology Lab. Twenty four rats were divided into 3 groups, including normal group, cancerous group, and growing mammary gland group. The rats were induced by DMBA (Dimethylbenz[a] anthracene) carcinogen compounds as much as 20 ml/body weight with 10 times repetition. After carcinogen compound induction was completed, rats were treated for 8 weeks [19]. All experiments were

conducted according to guiding principle for the care scientific purpose and approved by ethical committee University Brawijaya Malang Indonesia (884-KEP-UB).

“XY Linear” Table

“XY Linear” table was used to move an immobile object (rat) and able to slide 5 steps of left and right and also back and forth, with a very small shift with high resistance. The specifications of the “XY Linear” table, equipped with a stepper motor with 2000 steps per pulse resolution, repeatability reached 0.02, 1% of stepper motor error and were not accumulative in 1 conversion cycle with a 5 mm shift, to maintain the movement consistency of the “XY Linear” shift table, and gradual movement was controlled by a microcontroller. A microcontroller to maintain the consistency of each step motor movement control the linear table. The movement model was to get 25 of different positions, with 0.25 mm shift per step. Shift parameters were set by a maximum reference of 50% of pixel density and the width of the pixel box in the picture 0.475 mm.

Gold Standard Testing

The isolated breast tissue then tested by Pathology Anatomy (PA) as a Gold Standard test to check whether rats encountered the breast cancer. After 8-week of treatment period, surgery was performed on breast tissue and continued with histopathology using Hematoxylin-Eosin (HE) staining, to detect the presence of cancer lesions. Histopathology result was then compared between normal, cancer and growing mammary gland group. Indicating parameters were subjected in color, cell structure and cell size of breast tissue. Histopathology gold standard in this study was validated by the Pathological Anatomy Laboratory of University Brawijaya Malang Indonesia.

Analysis Methods

Breast screening through temperature analysis

“Raw of temperature” is a numerical data

resulting from body temperature measurement using infrared camera. These data show the highest temperature indicating abnormalities region (breast cancerous) [20]. Breast cancer can be determined based on information of the highest temperature and the average temperature value in the breast area. Determination and calculation of the highest and the average temperature values were performed using thermal imaging analysis software [21]. The highest temperature data for 8 weeks from each rat were analyzed using statistical method.

Breast screening through thermal pattern analysis

Breast screening was done by analyzing through the process of segmenting/detecting the edge of the image of the thermal pattern. The resulting image of thermal pattern was a multiresolution image with an unclear edge. Therefore, the process of thermal pattern segmentation requires a method eliminating the occurrence of corner effects using the Canny method. Segmentation is a process to find the different of intensity changes between pixels in an image field. The Segmentation of an image producing edges of the image object aims to mark the part leading into elaboration on images, improve blurred image details as well as effect of the image acquisition process. (d) and change 2D images into curve shapes [18].

Pre-processing was required prior to segmentation of thermal pattern in the breast separating the heat patterns from the background to acquire a heat pattern in grayscale form. In this research, the advantage of selected "Raw of Temperature", the value of each pixel was obtained from the temperature information of original. "Raw of Temperature" has a numeric value. Aim of indexing is to visualize thermal pattern of an object. The highest temperature will be visualized in white, while the cool temperature will be visualized in black. Visualization of the hot area (white) on the body of rat showed the location or position of the lesion, appropriately. That made crop of target area easier. Target area was cropped at 16-by-16

matrix and continued with RGB conversion process into grayscale color space on each pixel [20].

Subsequently, after the pre-processing stage, process of segmenting thermal patterns in the breast was done focused on recognition of thermal pattern. The thermal pattern of IR cameras is a multi-resolution image and does not have a clear edge, which frequently lead to false read-out (positive or negative false), especially in case of breast detection with growing in mammary glands. The edge of detection segmentation often creates angular effects, which is difficult to define the edge between objects and backgrounds.

Therefore it is necessary to finalize the edge segmentation of a thermal pattern by pressing all the other weak and unconnected edges to a strong edge. Using the Canny method, the segmentation of multi-resolution thermal pattern on breast cancer lesions will result clearer segmentation of thermal pattern.

Application of the Canny method was conducted in 4 steps [22] as follows: 1) Insertion of Gaussian filter to remove the noise and avoid of detecting false edge due to noise 2) Determination of image gradient intensities 3) Non-maximum suppression places to eliminate false responses in object edge segmentation. 4) Application of double threshold to determine the potential edges.

Results

Histopathology results

Histopathology was conducted to determine the malignancy level of breast using HE staining. At the end of 8th weeks, biopsy was obtained from the breast tissue and histopathology was performed using HE staining to determine the level/stage of malignancy (Figure 1).

The result of PA analysis on normal breast showed shape, structure and size cell, which were normal. Fat tissue stoma has the cabbage epithelium, partially appears cystically broad,

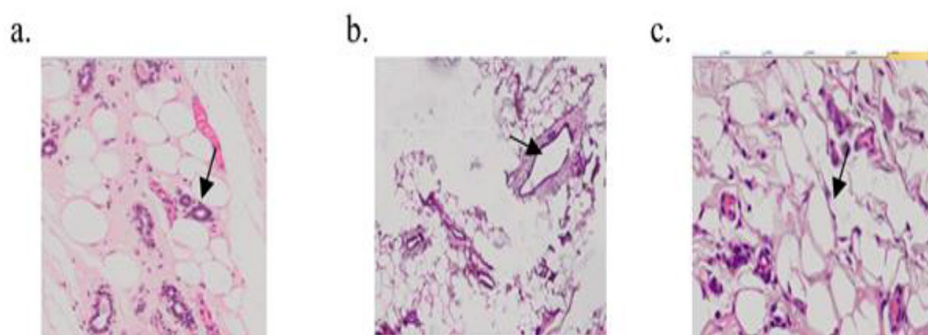


Figure 1: Histopathology Result a) Normal Breast b) Breast Cancerous c) Breast with growing mammary gland. Determination breast through morphology cell: structure, shape and size.

contains eosinophil amorphous material and focuses on chronic inflammatory cells in the fibro collagen stroma. In Figure 1b, an image like fibrocystic disease of the breast is seen.

The result of PA analysis on breast cancerous showed the changes of cell structure and the size of the cell enlarge. The appearance of hyperplasia and proliferation ductuli, some of them cystically stretched. In some area, this group of epithelium has irregular shaped within the stroma, suspicious of a malignant process.

The result of PA analysis on breast with growing mammary gland, which showed cell, has a normal shape, structure and size. Epithelial gland images with secretions inside the lumen are present, showing lactation of phase rats was maintained under normal condition with growing mammary glands.

Histopathological result can be used as the gold standard for breast screening through temperature and thermal pattern analysis.

Breast screening through temperature analysis

During DMBA inducing period, the body temperature of the rats was measured using an IR camera and the temperature changes were recorded every week. Each group showed variation in temperature change (Figure 2).

Based on temperature, the outcomes of normal group were considered as True Negative

(TN) in cases of values below 37 °C (84%), and False Negative (FN) in cases that the temperature exceeded 37 °C (16%). In group 2, thermal temperature above 38 °C was considered as True Positive (TP), as seen in 85% rats; whereas, temperature under 38 °C was considered as False Positive (FP), as seen in 15% rats. Similarly, in the group of rats with growing mammary glands, 76% and 24% were TP and FP, respectively.

There was a correlation of the incubation period with increasing temperature in the breast area of mice. The temperature in the normal mouse group was lower compared to the other groups (Figure 2). This finding can facilitate early detection of breast cancer, without side effects. The growth of lesions in each group was strongly influenced by the duration of treatment. The 8-week maintenance period had different effects on each group [Table 1].

The duration of maintenance compared to an increase in temperature of the normal group showed a negative value of 0.639, exhibiting negative and significant correlation. The duration of maintenance decreased the temperature in rat's breasts and led to the condition of normal rat. Referring to result of hypothesis test with significant value -2.034; thus, hypothesis is accepted.

The duration of maintenance compared to thermal changes in the cancer group had a positive value of 0.632 showing highly signifi-

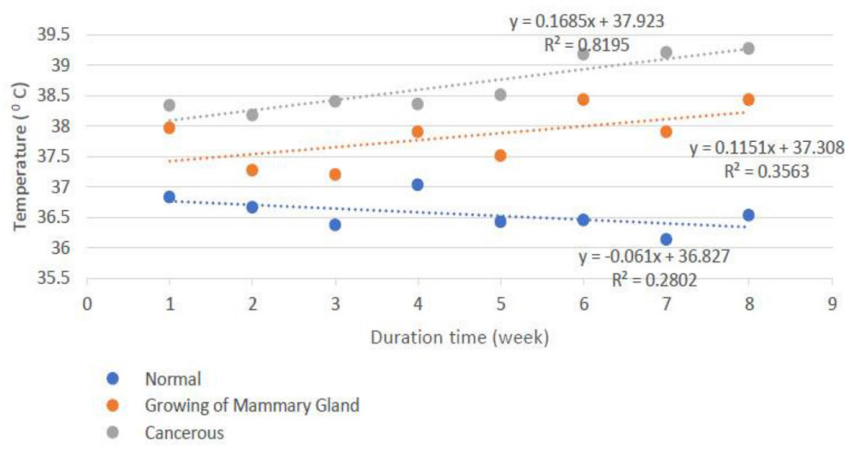


Figure 2: Temperature grouping, each group has a difference temperature range. Normal rat group has breast thermal temperature range are $t < 37\text{ }^{\circ}\text{C}$, while temperature range of rat with growing mammary glands are $37\text{ }^{\circ}\text{C} < t < 38\text{ }^{\circ}\text{C}$ and cancerous $> 38\text{ }^{\circ}\text{C}$

Table 1: Analysis Coefficients

Value	Normal Breast	Cancerous Breast	Breast with Growing mammary gland
Standardized coefficients Beta	-0.639	+0.673	-0.851
t-count	-2.034	+2.034	-3.976
Sig.	0.088	0.067	0.007

cant positive correlation, which is long-term treatment period of rat increasing the temperature in rat’s breast, and the level of malignancy as well.

The duration of maintenance compared to thermal changes in groups with growing mammary glands had a negative value of 0.851 showing highly significant negative correlation. The hypothesis was rejected by 0.007, showing that the length of period maintenance did not affect the hot temperature in the breasts of rat with growing mammary gland.

Breast screening through thermal pattern analysis

Based on temperature data, breast screening in Wistar rats cannot provide visualization of the lesions; however, the breast could provide

a clear picture through detection of thermal patterns. Analysis of thermal patterns of rat body temperature was done using the Canny segmentation method. Overall results are shown in Figure 3 from 24 research objects after verifying for 8 weeks and segmenting the thermal pattern according to the group.

No curve was found in thermal pattern of normal group, while cancerous group had perfectly closed curve and rats with growing mammary gland group had imperfect curve. The maintenance period of rats has an effect on thermal temperature both in normal and cancerous groups, but does not affect group with growing mammary glands. Thermal pattern analysis can be used as a reference or other modality for breast screening.

Breast screening through temperature anal-



Figure 3: Result of thermal segmentation with the Canny method. a) Normal breasts do not have a curve formed b) Breast cancer formed a perfectly closed curve and c) Breast with mammary gland growth, which an open and irregular curve is formed.

ysis produces 3D visual graphics, which has different peak areas. However, the normal breast has a narrow peak, cancerous breast has a wider peak indicating the extent of the cancerous lesion area since, the visual graph is flatter for breasts with mammary gland growth (Figure 4).

Discussion

Based on the results, thermography of the breasts demonstrated sensitivity, specificity and accuracy 91%, 70% and 83%, respectively. Results of breast screening through temperature analysis in Wistar rats have demonstrated low accuracy; therefore, segmentation analysis of thermal pattern is necessary as supporting data.

Segmentation result of thermal pattern in normal, cancerous breast and growing mammary gland groups show difference in thermal patterns. Based on the temperature and thermal pattern analysis [Table 2].

In the normal group, the temperature value of pixels is the same; thus, the temperature difference between pixels is zero. Differential values, which are not sharp (zero), do not form edge boundaries. There is no curve formed in the thermal segmentation of the pattern, indicating no cancer lesions in the object. The average temperature of eight normal mice is around 36.66 °C, with the lowest and highest

around 34.73 °C and 37.78 °C, respectively.

The heat pattern in the cancerous group demonstrated a distinct thermal pattern. A perfectly closed curve was formed showing the magnitude of the cancerous lesions. There were differences in the number of cancer lesions. In the cancer group, the highest temperature in a rat's body is marked in white. Temperature changes in the cropped area show variation from surrounding regions. Consequently, the temperature difference formed a sharp value gradient and a perfect curve. The average, lowest, and highest temperatures in rats in the cancerous group were approximately 38.67 °C, 37.16 °C and 41.42 °C, respectively.

The groups of rats with mammary gland growth showed high temperatures. The temperature between pixels is almost the same. This often shows "angular effects", causing false detection and cancer lesions. Using the Canny method, the results of thermal pattern segmentation cannot form a perfect curve. In the segmentation area, there is a midpoint marked white and had a different thermal temperature compared to the surrounding area. After segmentation, the value of false gradient is found, leading to the formation of an imperfect curve and showing that the heat captured is spread. Histopathological results showed the presence of mammary glands in the breast. The average, lowest, and highest temperatures

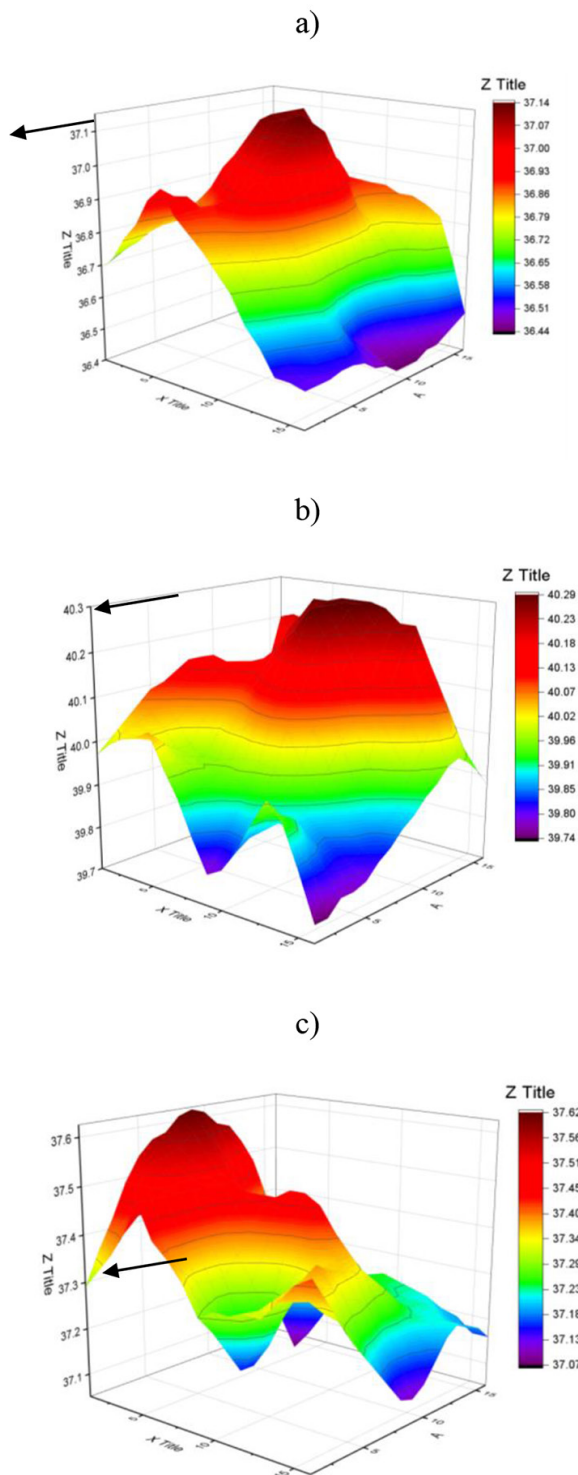


Figure 4: a) Temperature distribution in normal breasts. b) Temperature distribution in cancerous breasts. c) Temperature distribution in breast with mammary gland growth.

of group 3 are around 37.77 °C, 35 °C and 41.94 °C, respectively.

Conclusion

In this research, we investigated the correlation between thermal patterns and breast imaging. Breast screening using thermography is highly dependent on the temperature information. However, based on the highest temperature, a cancerous lesion is found or diagnosed, the thermal pattern is able to show the actual condition. Breast screening through temperature and thermal patterns analysis can distinguish normal breast, breast cancerous and breast with growing mammary glands.

Acknowledgment

Authors would like to thank to University Brawijaya laboratory staff on behalf of Mr. Didin, Mr. Lasmijan and Mr. Budi who helped to complete this research.

Conflict of Interest

None

References

1. Ferlay J, Soerjomataram I, Dikshit R, et al. Cancer incidence and mortality worldwide: sources, methods and major patterns in GLOBOCAN 2012. *Int J Cancer*. 2015;**136**(5):E359-86. doi: 10.1002/ijc.29210. PubMed PMID: 25220842.
2. Opstal-Van Winden AWJ, De Haan HG, Hauptmann M, Schmidt MK, Broeks A, Russell NS, Janus CPM, Krol ADG, et al. Genetic susceptibility to radiation-induced breast cancer after Hodgkin lymphoma. *Blood*. 2019;**133**(10):1130-9. doi: 10.1182/blood-2018-07-862607. PubMed PMID: 30573632. PubMed PMCID: PMC6405334.
3. Ozmen V, Ozcinar B, Bozdogan A, Eralp Y, Yavuz E, Dincer M. The effect of internal mammary lymph node biopsy on the therapeutic decision and survival of patients with breast cancer. *Eur J Surg Oncol*. 2015;**41**(10):1368-72. doi: 10.1016/j.ejso.2015.07.005. PubMed PMID: 26210653.
4. Bick U, Diekmann F. Digital mammography: what do we and what don't we know? *Eur Radiol*. 2007;**17**(8):1931-42. doi: 10.1007/s00330-007-0586-1.

Table 2: Result of determination breast through temperature and thermal pattern analysis.

Groups	Average Temperature (°C)	Form of segmentation curve
Normal Breast	36.66	no curve is formed
Breast with growing mammary gland	37.77	Imperfect curve formed
Breast Cancer	38.67	perfect closed curve is formed

- Rangayyan RM, Banik S, Desautels JEL. Computer-aided detection of architectural distortion in prior mammograms of interval cancer. *J Digit Imaging*. 2010;**23**(5):611–31. doi: 10.1007/s10278-009-9257-x. PubMed PMID: 20127270. PubMed PMCID: PMC3046672.
- Fletcher SW, Elmore JG. Clinical practice. Mammographic screening for breast cancer. *N Engl J Med*. 2003;**348**(17):1672-80. doi: 10.1056/NEJMcp021804. PubMed PMID: 12711743. PubMed PMCID: PMC3157308.
- Sobti A, Sobti P, Keith LG. Screening and diagnostic mammograms: why the gold standard does not shine more brightly. *Int J Fertil Womens Med*. 2005;**50**:199-206. PubMed PMID: 16468469.
- Othman E, Wang J, Sprague BL, Rounds T, Ji Y, Herschorn SD, Wood ME. Comparison of false positive rates for screening breast magnetic resonance imaging (MRI) in high risk women performed on stacked versus alternating schedules. *Springerplus*. 2015;**4**:77. doi: 10.1186/s40064-015-0793-1. PubMed PMID: 25741458. PubMed PMCID: PMC4340856.
- Salem DS, Kamal RM, Mansour SM, Salah LA, Wessam R. Breast imaging in the young: the role of magnetic resonance imaging in breast cancer screening, diagnosis and follow-up. *J Thorac Dis*. 2013;**5**(Suppl 1):S9-S18. doi: 10.3978/j.issn.2072-1439.2013.05.02. PubMed PMID: 23819032. PubMed PMCID: PMC3695543.
- Lozano III A, Hassanipour F. Infrared imaging for breast cancer detection: An objective review of foundational studies and its proper role in breast cancer screening. *Infrared Physics & Technology*. 2019;**97**:244-57. doi: 10.1016/j.infrared.2018.12.017.
- Yao X, Wei W, Li J, Wang L, Xu Z, Wan Y, Li K, Sun S. A comparison of mammography, ultrasonography, and far-infrared thermography with pathological results in screening and early diagnosis of breast cancer. *Asian Biomedicine*. 2014;**8**(1):11-9. doi: 10.5372/1905-7415.0801.257.
- Han F, Liang CW, Shi GL, Wang L, Li KY. Clinical applications of internal heat source analysis for breast cancer identification. *Gent Mol Res*. 2015;**14**(1):1450-60.
- Salhab M, Al Sarakbi W, Mokbel K. The evolving role of the dynamic thermal analysis in the early detection of breast cancer. *Int Semin Surg Oncol*. 2005;**2**(1):8. PubMed PMID: 15819982. PubMed PMCID: PMC1084358.
- Lashkari A, Pak F, Firouzmand M. Full intelligent cancer classification of thermal breast images to assist physician in clinical diagnostic applications. *Journal of Medical Signals and Sensors*. 2016;**6**(1):12-24. PubMed PMID: 27014608. PubMed PMCID: PMC4786959.
- Francis SV, Sasikala M, Saranya S. Detection of breast abnormality from thermograms using curvelet transform based feature extraction. *J Med Syst*. 2014;**38**(4):23. doi: 10.1007/s10916-014-0023-3. PubMed PMID: 24659445.
- Mamahit DJ. Detection early breast cancer by using digital infrared image based on asymmetry thermal. *Jurnal Teknik Elektro Dan Komputer*. 2012;**23**:1-8.
- Sheeja VF, Punitha N, Sasikala M. Cancer Detection in Rotational Breast Thermography Images using Bispectral Invariant. *J Chem Pharm Sci*. 2019;**9**(4):2189-94.
- Paramkusham S, Rao KMM, Prabhakar Rao BV-VSN., editor. Early stage detection of breast cancer using novel image processing techniques, Matlab and Labview implementation. 15th International Conference on Advanced Computing Technologies (ICACT); Rajampet, India: IEEE; 2013. p. 1-5.
- Kubatka P, Ahlersová E, Ahlers I, Bojková B, Kalická K, Adámeková E, Marková M, Chamilová M, Ermáková M. Variability of mammary carcino-

- genesis induction in female Sprague-Dawley and Wistar:Han rats: the effect of season and age. *Physiol Res.* 2002;**51**(6):633-40. PubMed PMID: 12511189.
20. Poerbaningtyas E., editor. Visualization of the Breast Cancer through Raw Data of Temperature on Thermal Imaging (Rat Model Animals). The 2nd International Conference on Informatics for Development 2018. UIN Sunan Kalijaga Yogyakarta; 2018.
21. Poerbaningtyas E, et al. Thermal Image Analysis Using Wavelet Method and Statistics in Ann Structure on Breast Cancer Identification (Animal Model: Rat). *Int J Adv Res.* 2018;6(11):178-84. doi: 10.21474/IJAR01/7984.
22. Sham FC, Chen N, Long L. Surface crack detection by flash thermography on concrete surface. *Insight-Non-Destructive Testing and Condition Monitoring.* 2008;**50**(5):240-3. doi: 10.1784/insi.2008.50.5.240.