



A New Method of Repairing Giant Omphaloceles with Bilateral Mesh Grafts Lateral to the Rectus Abdominis Muscles

Hamidreza Foroutan^{1,*}, Behdad Jenabali Jahromi¹, Naficeh Dastgheyb¹, Soltan Najafi¹

¹ Laparoscopy Research Center, Mother Hospital, Shiraz, IR Iran

*Corresponding Author: Hamidreza Foroutan, Laparoscopy Research Center, Department of Pediatric surgery, Shiraz University of Medical Sciences, Shiraz, IR Iran. Tel: +98-7112279711, Fax: +98-711227972, E-mail: forotanh@sums.ac.ir

ABSTRACT

Introduction: In spite of the advances in prenatal and neonatal medicine, giant omphalocele (GO) has remained as a challenge for pediatric surgeons. Although different techniques have been introduced for treating GO, the ideal treatment would be a primary closure without compromising the respiratory system or multiorgan failure. However, reaching this goal is challenging due to the high degree of viscerobdominal disproportion. This present study described the results of primary or secondary closure of five GO cases using the “bilateral mesh graft” technique.

Case presentation: Five consecutive GO patients were treated in our department. Two patients underwent a primary closure, while three other patients underwent a secondary closure using the “bilateral mesh graft” technique. When two mesh grafts were bilaterally fixed to the rectus abdominis muscles, the abdominal wall was reconstructed in the midline. All 5 patients were closely monitored for potential complications and a follow-up was also performed for each patient after they were discharged.

Discussion: The “bilateral mesh graft” technique was performed on the pediatric patients with a median age of 2.5 months (range 3 days to 6 months). The median diameter of the abdominal wall defect was 9 cm (range 7 - 10 cm). Moreover, the median was increased in bladder pressure after closure was 6.4 cm H₂O (range 3 - 10 cm H₂O). One of the patients who underwent secondary closure was diagnosed with a congenital heart condition and died postoperatively due to heart failure and respiratory insufficiency. The median hospital staying duration of the four surviving cases was 4.5 days with minimal complications. During the follow-up appointments, all four surviving patients exhibited normal weight gain and a soft abdomen with no infections or erosions detected at the site of surgery. The “bilateral mesh graft” technique yielded good clinical outcomes in both the primary and secondary closure cases. However, prior to surgery, particularly in the primary closure cases, the patients must be evaluated for respiratory function and additional congenital anomalies, such as heart conditions, in order to minimize potential complications. Nevertheless, further research is still needed in order to determine the long-term effects of the functional aspects on the abdominal wall muscles and viscera.

Keywords: Omphalocele, Synthetic graft, Patch

Copyright © 2012, Kowsar Corp.; Published by Kowsar Corp.

►Article type: Case Report; Received: 20 Feb 2013, Accepted: 02 Apr 2013; DOI: 10.5812/acr.11504

►Implication for health policy/practice/research/medical education:

This present study describes the results of primary or secondary closure of five Giant Omphaloceles cases using the “bilateral mesh graft” technique. This article may be helpful to pediatric surgeons for treating Giant Omphaloceles.

►Please cite this paper as:

Foroutan H, Jenabali Jahromi B, Dastgheyb N, Najafi S. A New Method of Repairing Giant Omphaloceles with Bilateral Mesh Grafts Lateral to the Rectus Abdominis Muscles. *Ann Colorectal Res*: 2013;1(1): 32-6. DOI: 10.5812/acr.11504

►Copyright © 2012, Kowsar Corp.; Published by Kowsar Corp.

This is an Open Access article distributed under the terms of the Creative Commons Attribution License (<http://creativecommons.org/licenses/by/3.0>), which permits unrestricted use, distribution, and reproduction in any medium, provided the original work is properly cited.

1. Introduction

Omphalocele is described as a central defect at the site of the umbilical ring resulting from a failure in the fusion of the caudal, lateral, and cephalic folds during the fourth week of gestation. The defect varies from 4 cm to 12 cm in diameter and is classified into small, giant, and ruptured omphalocele. Giant omphalocele (GO) is normally characterized by a central defect larger than 6 cm and a sac containing most of the abdominal viscera, including a part or all of the liver, which results in an underdeveloped peritoneal cavity(1, 2). Though there is still debate over what optimal the surgical treatment is in case that GO is associated with a poor prognosis, a surgical correction within 10 days of birth is believed to be necessary (2-6).

Although most of the techniques include staged repair strategies, we reported a one-stage procedure in five GO cases, which helped the abdominal domain to increase and reduce the viscera without any significant increase in intra-abdominal pressure. This technique yielded good clinical outcomes in both primary and secondary closures of GO defects in four out of the five cases.

2. Case presentation

2.1. Case 1

A baby girl was born on the 37th week of gestation with a birth weight of 3380 g. She had a 10 cm defect with a sac containing both the large and small intestines and the entire liver. However, no other congenital abnormalities and defects were detected after the infant was stabilized. Prior to the operation, the intra-abdominal pressure was measured at 10 cm H₂O via a Foley catheter. With the infant in a supine position, an incision was made on the skin just lateral to the omphalocele sac, opening a way into the abdominal cavity. In order to access the lateral margin of the rectus abdominis muscles on both sides, the liver and the intestines were dissected from the skin and the ventral abdominal wall. The next step included making an 8 cm longitudinal incision lateral to the rectus abdominis muscles, which dissected them from the peritoneum. The lateral incisions typically create a space of 5×8 cm, which provide sufficient room for the insertion of a mesh graft. The mesh graft is placed beneath intact and healthy skin, which prevents the erosion of the viscera. The mesh grafts are sutured to the muscles with an absorbable suture material (vicryl 3.0). After the reduction of the viscera in the abdominal cavity, the rectus abdominis muscles are shifted midline. However, after measuring the intra-abdominal pressure at 15 cm H₂O, the abdominal wall was closed by suturing the muscles midline with vicryl 2.0. After irrigation of the mesh grafts

with keflin, the subcutaneous and skin were closed and a dressing applied to the site. Due to hyperbilirubinemia, the infant was hospitalized for 7 days after the operation and discharged afterwards with normal food toleration and no signs of infection.

2.2. Case 2

A 6-month-old baby girl born prematurely on the 35th week of gestation with GO had undergone primary closure on the third day after birth, which disrupted after her discharge. She returned with a large abdominal mass containing small and large bowel loops and a part of the liver. The bladder pressure was measured with a Foley catheter (2 cm H₂O) before two longitudinal incisions were made on both sides of the mass. On both sides, two 7×5 cm mesh grafts were sutured with prolene 3.0 to the adjacent muscles. The abdominal wall was then closed by bringing the two abdominis muscles to the midline. The subsequent measurement of the bladder pressure showed that it had been increased to 11 cm H₂O. The patient was then discharged three days after the surgery with normal food toleration and an uneventful postoperative period. In a follow-up approximately 30 days later, she was found to be feeding normally, gaining weight, and exhibiting a soft abdomen. Most importantly, no erosions or signs of infections were detected at the site of surgery (Figure 1).

2.3. Case 3

A 6-month-old baby girl with GO since birth was initially treated with the primary closure of the defect when she was one day old. During the physical examination, she exhibited a 10x10 cm abdominal mass (10×10 cm) containing large and small bowel loops and a part of the liver. The bladder pressure was measured at 12 cm H₂O before the surgery. After an elliptical incision was made around the mass, the skin was dissected from the fascia and the omphalocele attachment. By using the above-mentioned technique, two mesh grafts measuring 8×5 cm were fixed to the adjacent muscles. Then, the muscles were separated from the external oblique muscles and approximated to the midline. In addition, the bladder pressure had increased to 15 cm H₂O. After the abdominal wall was closed with an absorbable suture material, a dressing was applied.

Because the baby was stable in the postoperative course with minor complications and normal food tolerance, she was discharged three days after the surgery. In a follow-up approximately 30 days later, she was found to be gaining weight and exhibiting a soft abdomen. Most importantly, no erosions or signs of infections were detected at the site of the surgery.

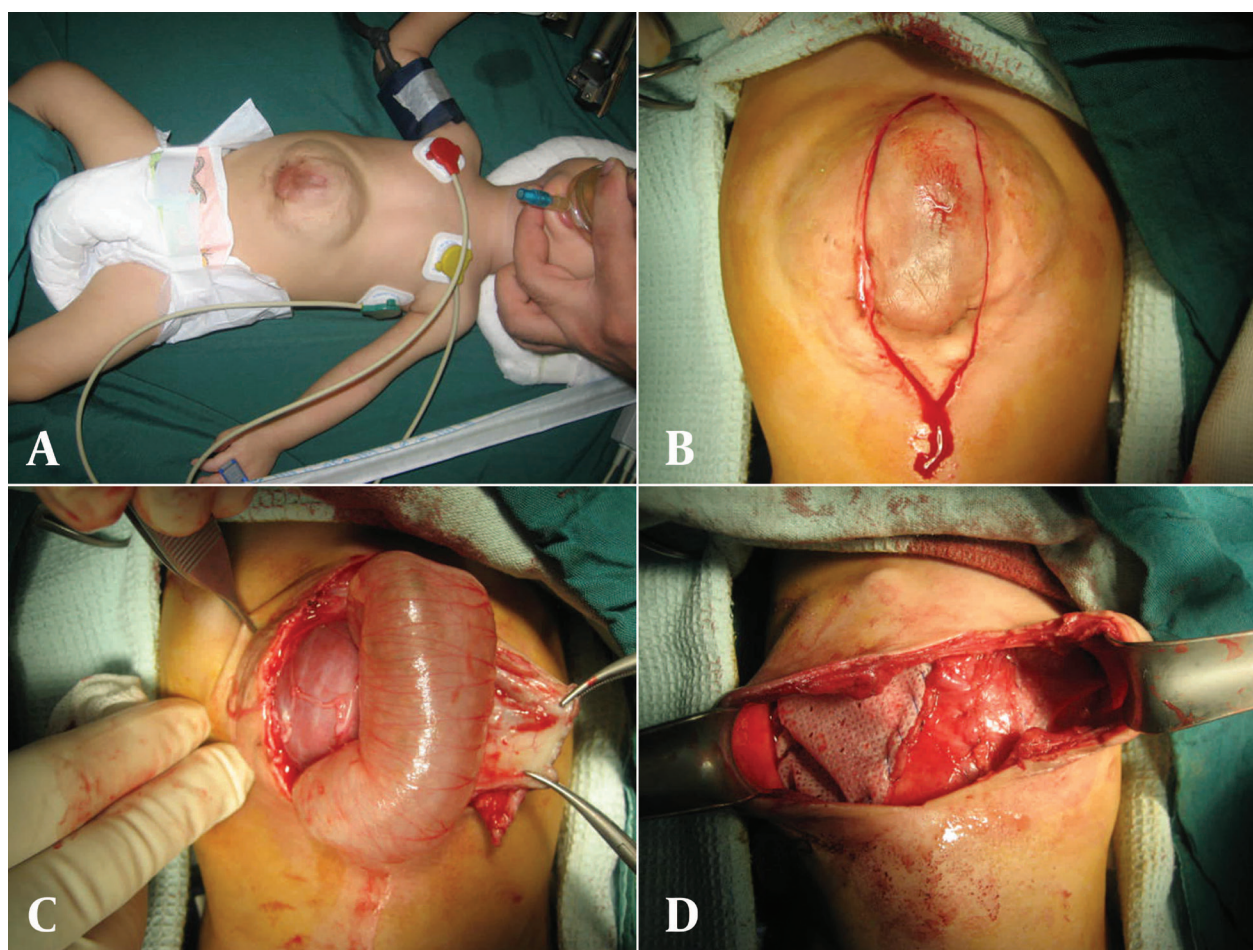


Figure 1. Ventral herniation of the viscera at the site of the abdominal defect (A), Bilateral incision on both sides of the mass (B) Part of the bowel herniating from the abdominal wall defect (C), On both sides, two mesh grafts are sutured to the adjacent muscles and the muscles are approximated in the midline (D).

2.4. Case 4

A 3-day-old baby girl born prematurely on the 36th week of gestation with a birth weight of 3200 g exhibited an 8 cm GO containing the small and large bowel and (A PART OF ALL OF THE LIVER? This was specifically specified in Cases 1-3, so for consistency purposes, it should also be mentioned here in Case 4) liver. In her workup, she was also diagnosed as having midgut malrotation. After measuring her bladder pressure at 10 cm H₂O via a Foley catheter (10 cm H₂O), the skin was dissected from the fascia and omphalocele attachment. To correct the malrotation, Ladd's procedure was used and the large bowel was brought to the left side. In the next step, the lateral longitudinal transections were made and the mesh grafts were fixed to the muscles, in this case with a prolene 4.0 suture. Then, the muscles were approximated to the midline. After the bladder pressure was measured at 15 cm H₂O, the abdomi-

nal wall was closed with nylon 4.0. Because the baby did not experience any major complications and exhibited normal food toleration, she was discharged 5 days after the surgery. In a follow-up approximately 30 days later, she was found to be feeding normally, experiencing normal bowel movement, and exhibiting a soft abdomen. Most importantly, no erosions or signs of infections were detected at the site of surgery.

2.5. Case 5

A 17-day-old baby boy was born through a caesarean operation at the 38th week of gestation with a birth weight of 2050 g. He was diagnosed with a giant omphalocele measuring 7×7 cm and congenital heart conditions (i.e. sub aortic ventral septal defect, pulmonary stenosis, and overriding aorta). He had undergone primary reconstruction of the omphocele with a mesh graft at the site

of the defect on the 7th day of birth. However, he was readmitted on the 17th day due to the disruption of the defect. Prior to the operation, because the bladder pressure was measured at 10 cm H₂O, the original mesh was removed. Accessing the lateral margin of the rectus abdominis muscles, two longitudinal incisions were made and the muscles were dissected from the peritoneum. The fascia was then released from the omphalocele sac, and after the reduction of the viscera, the fascia and muscles from both sides were approximated to the midline. The bladder pressure was measured again and found to have increased to 22 cm H₂O. After measuring the vitals, two 7x4.5 cm mesh grafts were laterally fixed to the muscles with an absorbable suture material. After irrigating the mesh grafts with keflin, the abdominal wall was closed in the midline with a non-absorbable suture material. Again, the bladder pressure was measured to be 20 cm H₂O. Unfortunately, the patient died a day after the operation due to the heart failure and the respiratory acidosis resulting from respiratory insufficiency.

3. Discussion

In spite of the advances in prenatal and neonatal medicine, GO has remained a challenge for pediatric surgeons. Up until now, various techniques have been introduced for treating GO. Some techniques, which are usually considered for at risk patients (e.g. infants with a very low birth rates or respiratory insufficiencies at birth) involve conservative management (7-9). However, the most common surgical treatments involve the staged closure techniques that have been modified since 1948. Gross (10). Attempting to treat the defect by advancing skin flaps without opening the amniotic sac, it resulted in ventral hernias which required a surgical correction later in life. Other techniques introduced afterwards modified this method by sequentially reducing the viscera in an attempt to minimize potential complications (11-13).

Nevertheless, the ideal treatment for GO would be a primary closure without compromising the respiratory system or multiorgan failure. However, reaching this goal is challenging due to the high degree of viscerabdrominal disproportion.

Because the abdominal musculature is spared in neonates with omphalocele, the rectus sheath and the rectus abdominis muscles are intact. In 1990, Ramirez et al. used a component separation technique (CST) to reconstruct the abdominal wall without using prosthetic materials in patients with midline abdominal wall defects (14). Though CST has been used successfully in adult surgery (15, 16), such patients have not exhibited the same high degree of viscerabdrominal disproportion.

In using this "bilateral mesh graft" technique, one must be aware of the blood supply of the skin to the ventral abdominal wall and try not to cut off the blood supply because the transaction of the perforating branches of the

epigastric artery interferes with the blood supply. In this study four out of the five pediatric patients experienced good clinical outcomes. This technique can be used in both primary and secondary closures of the abdominal wall defect, taking into consideration that patients must be evaluated for respiratory function and additional congenital anomalies such as heart conditions—particularly in primary closure cases—to minimize the potential complications. As in the complication observed in case five, the apparently insignificant increase in the abdominal pressure can cause more complications in patients with congenital anomalies. Therefore, the application of another technique might be required.

This "bilateral mesh graft" technique yields the advantage of the reconstruction of the normal anatomy of the abdominal wall, which helps achieve better functioning as well as cosmetic results. Second, because the mesh grafts are located beneath healthy skin, the risk of infection due to prosthetic material is reduced. Furthermore, ventral herniation and abdominal compartment syndrome are also prevented. Third, because this technique is a one-stage procedure, there is a decrease in duration of hospitalization and, thus, a decrease in the risk of hospital acquired infections and the costs accruing to hospitals and patients.

In conclusion, in the present study, the "bilateral mesh graft" technique used in treating GO patients yielded good clinical outcomes in both primary and secondary closure cases. Nevertheless, further research is still needed in order to determine the long-term effects of the functional aspects on the abdominal wall muscles and viscera.

Acknowledgements

Special thanks go to Hamidreza Foroutan, Behdad Jenabali Jahromi, Naficeh Dastghey and Soltan Najafi.

Authors' Contribution

Ideas were proposed by Hamidreza Foroutan. Study design, writing paper and data collection was done by Behdad Jenabali Jahromi and Naficeh Dastgheyb.

Financial Disclosure

No financial interest to report.

Funding/Support

The work was supported by the Vice-Chancellor of Research and Technology of Shiraz University of Medical Sciences.

References

1. Martin AE, Khan A, Kim DS, Muratore CS, Luks FI. The use of intraabdominal tissue expanders as a primary strategy for closure of. *J Pediatr Surg*. 2009;**44**(1):178-82.

2. Wijnen RM, van Eijck F, van der Staak FH, Bleichrodt RP. Secondary closure of a giant omphalocele by translation of the muscular layers: a. *Pediatr Surg Int.* 2005;**21**(5):373-6.
3. Biard JM, Wilson RD, Johnson MP, Hedrick HL, Schwarz U, Flake AW, et al. Prenatally diagnosed giant omphaloceles: short- and long-term outcomes. *Prenat Diagn.* 2004;**24**(6):434-9.
4. Oldham KT, Colombani PM, Foglia RP, Skinner MA. *Principles and practice of pediatric surgery.* 2005.
5. Pacilli M, Spitz L, Kiely EM, Curry J, Pierro A. Staged repair of giant omphalocele in the neonatal period. *J Pediatr Surg.* 2005;**40**(5):785-8.
6. Zama M, Gallo S, Santecchia L, Bertozzi E, Zaccara A, Trucchi A, et al. Early reconstruction of the abdominal wall in giant omphalocele. *Br J Plast Surg.* 2004;**57**(8):749-53.
7. Pereira RM, Tatsuo ES, Simoes e Silva AC, Guimaraes JT, Paixao RM, Lanna JC, et al. New method of surgical delayed closure of giant omphaloceles: Lazaro da Silva's. *J Pediatr Surg.* 2004;**39**(7):1111-5.
8. Reynolds M. Abdominal wall defects in infants with very low birth weight. *Semin Pediatr Surg.* 2000;**9**(2):88-90.
9. Tsakayannis DE, Zurakowski D, Lillehei CW. Respiratory insufficiency at birth: a predictor of mortality for infants with. *J Pediatr Surg.* 1996;**31**(8):1088-90.
10. Gross RE. A new method for surgical treatment of large omphaloceles. *Surgery.* 1948;**24**(2):277-92.
11. Bax NM, van der Zee DC, Pull ter Gunne AJ, Rovekamp MH. Treatment of giant omphalocele by enlargement of the abdominal cavity with a. *J Pediatr Surg.* 1993;**28**(9):1181-4.
12. Foglia R, Kane A, Becker D, Asz-Sigall J, Mychaliska G. Management of giant omphalocele with rapid creation of abdominal domain. *J Pediatr Surg.* 2006;**41**(4):704-9.
13. Schuster SR. A new method for the staged repair of large omphaloceles. *Surg Gynecol Obstet.* 1967;**125**(4):837-50.
14. Ramirez OM, Ruas E, Dellon AL. "Components separation" method for closure of abdominal-wall defects: an anatomic. *Plast Reconstr Surg.* 1990;**86**(3):519-26.
15. Bleichrodt RP, de VriesReilingh TS, Malyar A, Van Goor H, Hansson B, Van der Kolk B. Component separation technique to repair large midline hernias. *Oper Tech Gen Surg.* 2004;**6**:179-88.
16. de Vries Reilingh TS, van Goor H, Charbon JA, Rosman C, Hesselink EJ, van der Wilt GJ, et al. Repair of giant midline abdominal wall hernias: "components separation technique". *World J Surg.* 2007;**31**(4):756-63.