



Diaphragmatic Herniation of Ruptured Right Lobe of Liver with Hypertrophied Left Lobe

Mohit Kumar Joshi^{1*}, Narendra Choudhary¹, Subodh Kumar¹, Dinesh Bagaria¹, Abhinav Kumar¹, Pratyusha Priyadarshini¹

¹JPN Apex Trauma Centre, All India Institute of Medical Sciences, New Delhi-110029, India

***Corresponding author:** Mohit Kumar Joshi

Address: Division of Trauma & Critical Care, JPN Apex Trauma Centre, All India Institute of Medical Sciences, New Delhi-110029, India.

Tel: +91-11-26594430

e-mail: drmohitjoshi@gmail.com

Received: May 21, 2018

Accepted: May 28, 2018

Please cite this paper as:

Joshi MK, Choudhary N, Kumar S, Bagaria D, Kumar A, Priyadarshini P. Diaphragmatic Herniation of Ruptured Right Lobe of Liver with Hypertrophied Left Lobe. *Bull Emerg Trauma*. 2018;6(3):267-268. doi:

A 17-year-girl presented with recurrent pain in abdomen of 10-year duration. The pain used to start as dull ache on right side of her abdomen, which gradually would increase over few hours to become moderately severe. This was not associated with nausea, vomiting, abdominal distension, respiratory, bowel or urinary symptoms, jaundice or fever. The pain usually lasted for 4-6 hours and subside on its own mostly or at times with oral analgesics. Such episodes became more frequent with increasing severity of pain from last 2 years. She visited many local practitioners for same to no avail. On careful evaluation, she revealed history of significant blunt trauma to abdomen at the age of 5 years due to fall from a swing.

General physical examination, chest and abdominal examination were unremarkable. Her routine hematological investigations were within normal limits. Chest X-ray suggested right diaphragmatic hernia. A contrast enhanced CT scan showed partially fractured right lobe of liver with heterogeneous enhancement herniating into the right pleural cavity through a diaphragmatic tear. The rest of the right lobe was normal but the left lobe was peculiarly enlarged reaching the left lateral abdominal wall and then curving around the spleen (Figure 1A). Other abdominal viscera were normal.

On abdominal exploration, a significant portion of

the right lobe of liver was found fractured that had herniated into the right thoracic cavity through a diaphragmatic rent measuring 8x4 centimeters. This segment could be delivered into the abdomen by enlarging the diaphragmatic defect and adhesiolysis. The herniated segment was congested that explained its heterogeneous appearance on CT scan (Figure 1B). The left lobe of liver was hypertrophied, reaching beyond the splenic flexure and draping around the spleen. The rest of abdominal viscera was normal. The diaphragmatic tear was repaired primarily using polypropylene suture. The post-operative course was uneventful and the girl was discharged after 3 days. At 6 months of follow-up she is asymptomatic.

Right sided diaphragmatic hernias are rare due primarily to the protective effect of the liver [1, 2]. They are mostly asymptomatic and may remain undiagnosed for long. It is reported that this delay may be as long as 50 years [2]. At times they may present with non-specific symptoms like abdominal pain, respiratory difficulty and bowel symptoms after variable period from injury, so a history of trauma must be taken in such patients. This proved crucial in our case. The abdominal pain in our patient and the hypertrophy of left lobe of liver may be explained by chronic ischemia of the herniated portion of the liver. This is also supported by its congested appearance. Once diagnosed, the hernia should be repaired

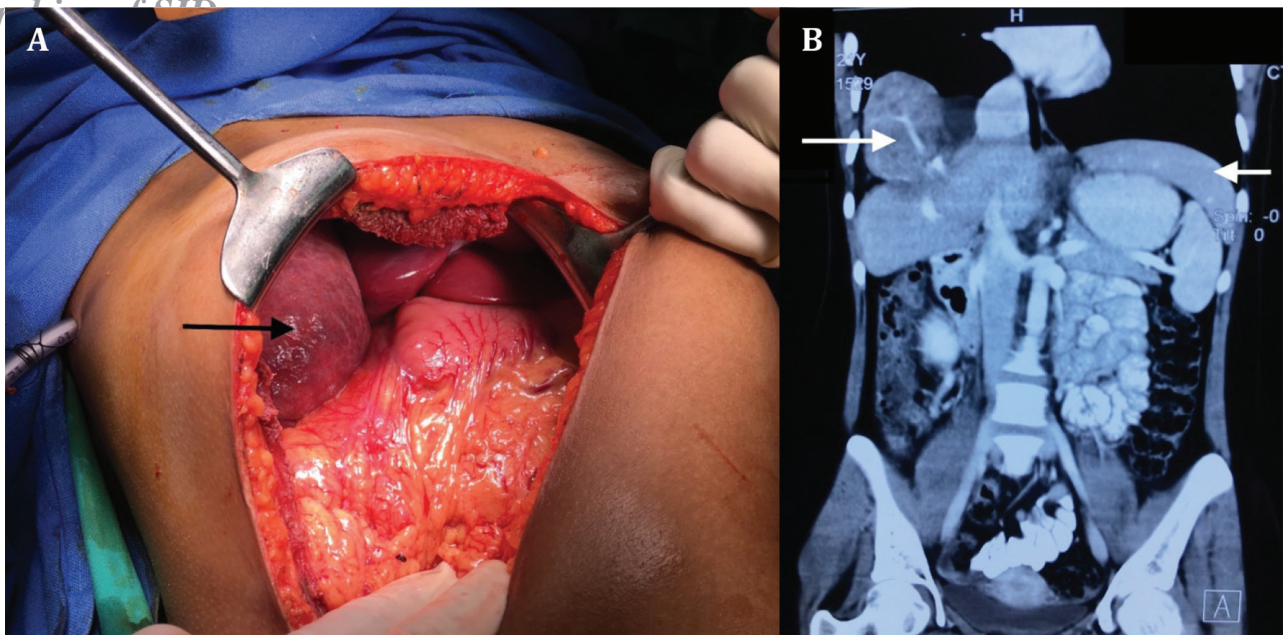


Fig. 1. Ruptured right lobe that had herniated through diaphragmatic defect (arrow) (A); Coronal abdominopelvic computed tomography (CT) image with intravenous contrast injection showing fractured right lobe of liver herniating into the right pleural cavity (arrow on right); enlarged left lobe draping around spleen (arrow on left) (B).

either primarily or using a synthetic mesh by open or laparoscopic approach [3].

Conflicts of Interest: None declared.

References

1. Rashid F, Chakrabarty MM, Singh R, Iftikhar SY. A review on delayed presentation of diaphragmatic rupture. *World J Emerg Surg.* 2009;4:32.
2. Kuppusamy A, Ramanathan G, Gurusamy J, Ramamoorthy B, Parasakthi K. Delayed diagnosis of traumatic diaphragmatic rupture with herniation of the liver: a case report. *Ulus Travma Acil Cerrahi Derg.* 2012;18(2):175-7.
3. Liao CH, Chu CH, Wu YT, Fu CY, Hsieh FJ, Wang SY, et al. The feasibility and efficacy of laparoscopic repair for chronic traumatic diaphragmatic herniation: introduction of a novel technique with literature review. *Hernia.* 2016;20(2):303-9.

Open Access License

All articles published by Bulletin of Emergency And Trauma are fully open access: immediately freely available to read, download and share. Bulletin of Emergency And Trauma articles are published under a Creative Commons license. Mandated authors will be offered CC-BY; all other authors will choose between CC-BY, CC-BY-NC and CC-BY-NC-ND.