



Intrauterine Fetal Traumatic Brain Injury Following Motor Vehicle Accident; A Case Report and Review of the Literature

Mohammad Safdari¹, Zohre Safdari², Masoud Pishjoo^{3*}

¹Department of Neurosurgery, Zahedan University of Medical Sciences, Zahedan, Iran

²Department of Radiology, Zahedan University of Medical Sciences, Zahedan, Iran

³Department of Neurosurgery, Mashhad University of Medical Sciences, Mashhad, Iran

*Corresponding author: Masoud Pishjoo

Address: Resident of Neurosurgery, Department of Neurosurgery, Ghaem Hospital, Mashhad, Iran.

Cellphone: +98-915-3628792; Tel/Fax: +98-51-38413493

e-mail: masoud.pishjoo@gmail.com

Received: May 2, 2018

Revised: June 24, 2018

Accepted: June 25, 2018

ABSTRACT

Trauma, especially traumatic injuries due to car accidents are one of the causes of maternal and fetal mortality and morbidity during pregnancy. Fetus brain injuries are usually caused fetus death. We herein report a pregnant woman in 28 weeks of gestation. The fetus was found to be normal during in-hospital. At birth, the female neonate demonstrated developmental delay and neurological deficits (hypotonicity). Neuroimaging after birth revealed extreme dilatation of lateral ventricles, hypoplasia and aplasia of the brain. In 4 months, she had multiple morbidities including developmental delay, hypotonia, blindness, oropharyngeal dysphagia and simple partial seizure. Motor and response to stimulation was normal. Appropriate seatbelt usage can protect the fetus from sustaining severe intracranial injuries.

Keywords: Fetal injury; Traumatic brain injury; Pregnancy.

Please cite this paper as:

Safdari M, Safdari Z, Pishjoo M. Intrauterine Fetal Traumatic Brain Injury Following Motor Vehicle Accident; A Case Report and Review of the Literature. *Bull Emerg Trauma*. 2018;6(4):372-375. doi: 10.29252/beat-060417.

Introduction

Trauma is the main non-obstetric etiology of mortality in pregnant woman [1]. Motor-vehicle accidents still are the main causes of trauma-associated injuries in pregnancy followed by falls and violence [2]. Maternal traumatic injuries are most common during the third trimester leading to fetal skull fractures and intraparenchymal hemorrhages [3]. However, still there less concordance between

severity of maternal trauma and computerized tomography (CT) of the fetal brain [3]. However, it is well established that significant intracranial pathologies such as subdural hematoma (SDH) is associated with severe maternal abdominal trauma [4]. Fetal trauma in pregnant women who have suffered from blunt trauma is very rare but if the damage reach to fetus head, it is usually fatal [5]. Also about penetrating traumas, however is accompanied with low mother mortality but usually

the fetus mortality is high [6].

The survival of fetus that are suffered from head injuries depends on type of injury, intrauterine asphyxia, maturity and postnatal period. Followed to fetus brain trauma, if fetus survive, with high risk, it likely to develop encephalopathy, cerebral palsy, development delay [7]. There is a paucity of the literature on the subject which makes the evidence-based approach more difficult. We herein report a case of 28th week fetus brain injury secondary to inappropriate use of seatbelt during a motor-vehicle accident.

Case Report

A primigravid pregnant woman at 28 weeks of gestation was brought to the hospital due to car-accident. The accident had occurred at suburban road, and two cars had collided at high speed from the front. The pregnant woman was sitting at the front seat next to the driver using the seatbelt while the belt was not suitable for pregnancy. During the transport of the mother to the hospital to prevent of supine hypotension syndrome, a roll was placed under the backboard to allow for 15-degree rotation to left. At Hospital, the mother's vital signs were normal and no obvious injury was recorded in the mother. All the physical examinations and laboratory tests were unremarkable. Before accident, the fetus was normal in all of screening surveys. In fetus survey that conducted immediately on admission, the fetal heart rate (FHR) showed no changes and fetus movements and fetus amniotic liquid was normal and there was no evidence of bleeding behind the placenta. The survey was repeated 3, 6 and 24 hours later and had normal results, so the decision was taken to continue the pregnancy. The mother was discharged in good condition with caution sign and symptoms.

After discharge, she was checked in outpatient clinic routinely. In the last ultrasound that was performed at 39 weeks of gestation, fetal brain lateral ventricles' diameter in the trigon area was 25mm and the remaining thickness of cerebral hemispheres parenchyma was 4mm which indicated severe brain atrophy. In 39 weeks of gestation, term female infant was born with Apgar score in 1 and 5 minutes, being recorded as 8. Her birth weight was 2800 grams and head circumference was 30 cm. In appearance, hypotonicity and microcephaly was significant. Brain CT-scan (Figure 1) and magnetic resonance imaging (MRI) (Figure 2) was done after birth that extreme dilatation of lateral ventricles, hypoplasia and aplasia of the brain were observed. Because of skull deformity and neurological deficits, the patient was transferred to neurosurgical service and was assessed constantly. After 10 days on in-hospital evaluation and assessment the patient was discharged and was assessed in an outpatient basis. In 4 months, she had multiple morbidities including developmental delay, hypotonia, blindness, oropharyngeal dysphagia and simple partial seizure. Motor and response to stimulation was normal. According to the patient's condition, phenobarbital elixir was administered with partial improvement. After one year that we followed up the patient, there was no new sign in the patient, but the patient still had a developmental delay, hypotonia and dysphagia but patient's seizures were controlled.

Discussion

Most traumatic injuries to the fetus occurs due to car accidents, suicide, violence and war [7]. Car accidents is the most common form of trauma in pregnant women which occur in 2.8% of pregnant women in the USA [8]. After introduction of the airbags, the injury to the fetal head has increased

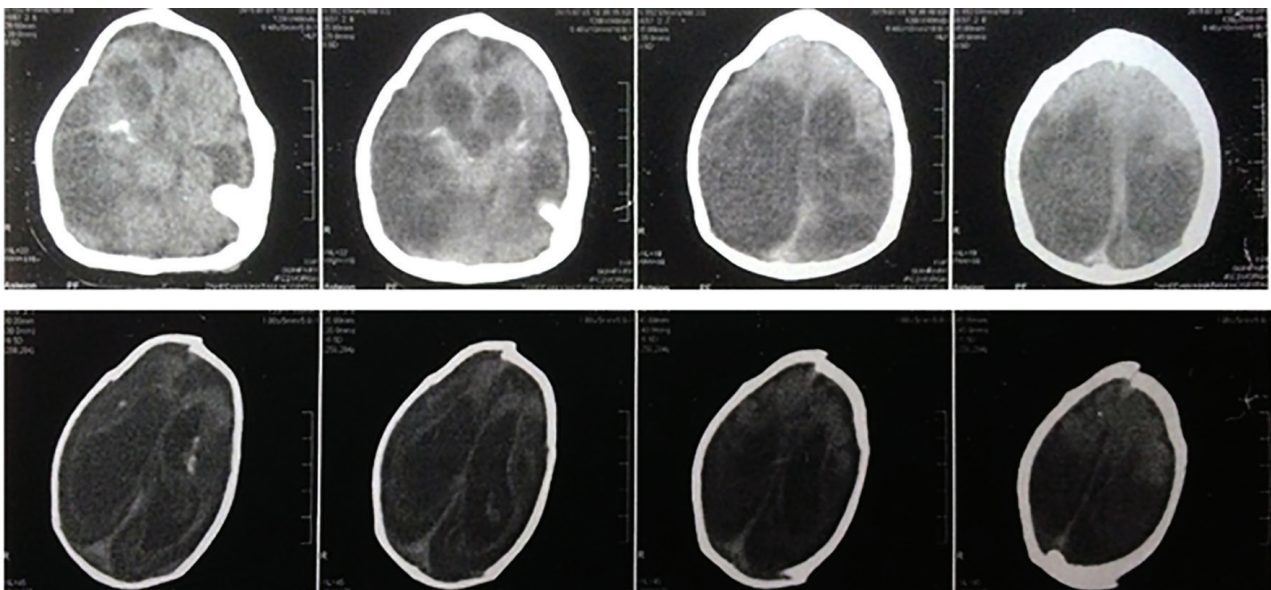


Fig. 1. Axial brain CT-scan of the fetus demonstrated multiple skull fracture, interhemispheric SDH, intraparenchymal contusions and hemorrhage, intraventricular hemorrhage and loss of white-gray differentiation.

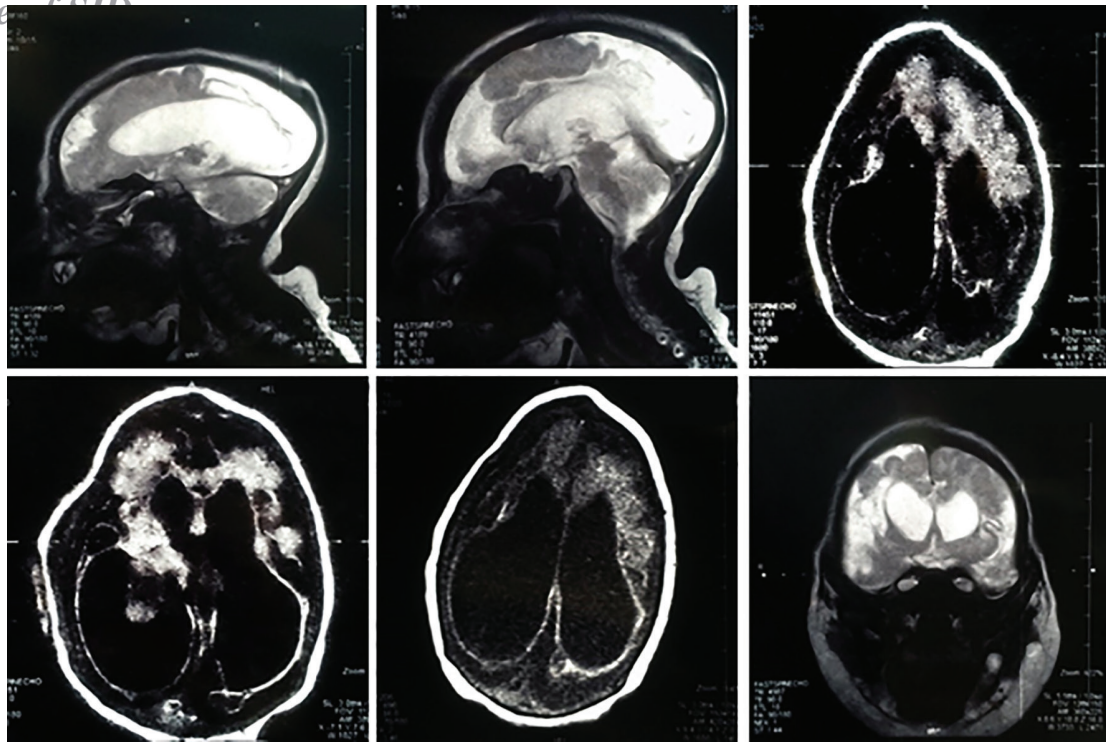


Fig. 2. Sagittal T2-weighted MRI demonstrating the severe encephalomalacia along with brain atrophy (A,B); Axial fluid-attenuated inversion recovery (FLAIR) demonstrating ventriculomegaly and multiple intraparenchymal hemorrhages.(C,D,E); coronal T2-weighted MRI demonstrating right frontoparietal brain atrophy.

probably because of the different mechanism of injury. It is recommended that the pregnant women use seatbelt appropriately during pregnancy which is associated with reduced burden of maternal and fetal morbidity and mortality [9].

Of note the position of the lap belt should be placed below the prominence of the pregnant abdomen, with the shoulder harness off the side of the uterus, between the breasts and over the midline of the clavicle. The mother should sit at least 10 inches from the steering wheel [10]. It is also important that during transport of pregnant woman, after 20 weeks of gestation the supine position should be avoided due to compression of the inferior vena cava [11].

FHR monitoring after trauma is a suitable method for checking the fetus health and FHR changes usually occur prior to fetal brain damage [12]. Placental abruption occurring in 5-50% of maternal trauma [13]. On ultrasound, abruption can be missed in up to 50% of cases. Most abruptions occur within 2-6 hours after injury, and almost all within the first 24 hours post injury [14]. In previous studies, CT scan was stated the best way to assess the fetus brain injury after trauma, and has advised if there

is a doubt for fetus brain injury, CT scan must do at the first time because damages due to radiation is much less than the damages caused by the delay in diagnosis. Even though a CT can be performed relatively safely, so MRI would be much safer and more detailed [12, 15].

In conclusion, fetal traumatic brain injury can result in severe brain atrophy, intraparenchymal and intraventricular hemorrhages, subdural hematoma and skull fractures leading to neonatal developmental delay, hypotonia, blindness, oropharyngeal dysphagia and seizures. Appropriate seatbelt usage can protect the fetus from sustaining severe intracranial injuries.

Acknowledgment

We would like to thank the patient and her family who provided us with the consent of publishing the manuscript with the images. We would like to acknowledge the editorial assistance of Diba Negar Research Institute for improving the English and style of the manuscript.

Conflicts of Interest: None declared.

References

1. Saatian M, Ahmadpoor J, Mohammadi Y, Mazloumi E. Epidemiology and Pattern of Traumatic Brain Injury in a Developing Country Regional Trauma Center. *Bull Emerg Trauma.* 2018;6(1):45-53.
2. Abbasi HR, Mousavi SM, Taheri Akerdi A, Niakan MH, Bolandparvaz S, Paydar S. Pattern of Traumatic Injuries and Injury Severity Score in a Major Trauma Center in Shiraz, Southern Iran. *Bull Emerg Trauma.* 2013;1(2):81-5.
3. Kopelman TR, Bogert JN, Walters JW, Gridley D, Guzman O, Davis KM, et al. Computed tomographic imaging interpretation improves fetal outcomes after maternal

- trauma. *J Trauma Acute Care Surg.* 2016;**81**(6):1131-5.
4. Piastra M, Pietrini D, Massimi L, Caldarelli M, De Luca D, Del Lungo LM, et al. Severe subdural hemorrhage due to minimal prenatal trauma. *J Neurosurg Pediatr.* 2009;**4**(6):543-6.
 5. Sadro CT, Zins AM, Debiec K, Robinson J. Case report: lethal fetal head injury and placental abruption in a pregnant trauma patient. *Emerg Radiol.* 2012;**19**(2):175-80.
 6. Muzumdar D, Higgins MJ, Ventureyra EC. Intrauterine penetrating direct fetal head trauma following gunshot injury: a case report and review of the literature. *Childs Nerv Syst.* 2006;**22**(4):398-402.
 7. Leroy-Malherbe V, Bonnier C, Papiernik E, Groos E, Landrieu P. The association between developmental handicaps and traumatic brain injury during pregnancy: an issue that deserves more systematic evaluation. *Brain Inj.* 2006;**20**(13-14):1355-65.
 8. Hyde LK, Cook LJ, Olson LM, Weiss HB, Dean JM. Effect of motor vehicle crashes on adverse fetal outcomes. *Obstet Gynecol.* 2003;**102**(2):279-86.
 9. Schultze PM, Stamm CA, Roger J. Placental abruption and fetal death with airbag deployment in a motor vehicle accident. *Obstet Gynecol.* 1998;**92**(4 Pt 2):719.
 10. Grossman NB. Blunt trauma in pregnancy. *Am Fam Physician.* 2004;**70**(7):1303-10.
 11. Pearlman M, Faro S. Obstetric septic shock: a pathophysiologic basis for management. *Clin Obstet Gynecol.* 1990;**33**(3):482-92.
 12. Matsushita H, Harada A, Sato T, Kurabayashi T. Fetal intracranial injuries following motor vehicle accidents with airbag deployment. *J Obstet Gynaecol Res.* 2014;**40**(2):599-602.
 13. Pearlman MD, Tintinalli JE, Lorenz RP. A prospective controlled study of outcome after trauma during pregnancy. *Am J Obstet Gynecol.* 1990;**162**(6):1502-7; discussion 1507-10.
 14. Shah KH, Simons RK, Holbrook T, Fortlage D, Winchell RJ, Hoyt DB. Trauma in pregnancy: maternal and fetal outcomes. *J Trauma.* 1998;**45**(1):83-6.
 15. Brunel H, Girard N, Confort-Gouny S, Viola A, Chaumoitre K, D'Ercole C, et al. Fetal brain injury. *J Neuroradiol.* 2004;**31**(2):123-37.

Open Access License

All articles published by Bulletin of Emergency And Trauma are fully open access: immediately freely available to read, download and share. Bulletin of Emergency And Trauma articles are published under a Creative Commons license. Mandated authors will be offered CC-BY; all other authors will choose between CC-BY, CC-BY-NC and CC-BY-NC-ND.