



CrossMark



## Stereological Comparison of Imbided Fibrinogen Gauze versus Simple Gauze in External Packing of Grade IV Liver Injury in Rats

Shahram Paydar<sup>1</sup>, Golnoush Sadat Mahmoudi Nezhad<sup>1</sup>, Mohammad Yasin Karami<sup>1</sup>, Hossein Abdolrahimzadeh<sup>1</sup>, Mojtaba Samadi<sup>1</sup>, Alireza Makarem<sup>2</sup>, Ali Noorafshan<sup>3</sup>

<sup>1</sup>Trauma Research Center, Shahid Rajaee (Emtiaz) Trauma Hospital, Shiraz University of Medical Sciences, Shiraz, Iran

<sup>2</sup>Department of Urology, Shiraz University of Medical Sciences, Shiraz, Iran

<sup>3</sup>Department of Anatomy, School of Medicine, Shiraz University of Medical Sciences, Shiraz, Iran

\*Corresponding author: Golnoush Sadat Mahmoudi Nezhad

Address: Trauma Research Center, Shahid Rajaee (Emtiaz) Trauma Hospital, Shiraz University of Medical Sciences, Shiraz, Iran.

e-mail: golnooshm.mahmoodi@gmail.com

Received: June 23, 2018

Revised: August 20, 2018

Accepted: September 23, 2018

### ABSTRACT

**Objective:** To evaluate the effect of imbided fibrinogen gauze on survival, bleeding and healing in liver trauma.

**Methods:** This animal experimental study was conducted on 20 adult male Sprague-Dawley rats; with a mean weight of 300±50 gram; divided into two groups. Grade IV injury was induced to the subjects' liver. Then, the bleeding site was packed with simple gauze in the control group, and imbided fibrinogen gauze in the experimental group. All animals were re-evaluated for liver hemostasis 48 hours after the initial injury. Bleeding in the intra peritoneal cavity was measured using Tuberculosis Syringe in the first and second operations. Subjects were followed-up for 14 days. Eventually, the rats were sacrificed and their livers were sent to a lab for stereological assessment. Statistical comparisons were performed via Mann-Whitney U-test using SPSS. P-Values less than 0.05 were considered to be statistically significant.

**Results:** Half of the rats in the control group died, while all the rats in the imbided fibrinogen gauze group survived after two weeks ( $p=0.032$ ). Bleeding in the imbided fibrinogen gauze was significantly less than control group, 48 hours' post-surgery ( $p<0.001$ ). According to the stereological results, granulation tissue in the imbided fibrinogen gauze group were more than the control group ( $p=0.032$ ). Also, fibrosis in the imbided fibrinogen gauze group were more than the control group ( $p=0.014$ ).

**Conclusion:** Our study indicated that imbided fibrinogen gauze can potentially control liver bleeding and improve survival through increasing granulation tissue and fibrosis in injured liver.

**Keywords:** Fibrinogen; Wounds and injuries; Rats; Liver.

Please cite this paper as:

Paydar S, Mahmoudi Nezhad GS, Karami MY, Abdolrahimzadeh H, Samadi M, Makarem AR, Noorafshan A. Stereological Comparison of Imbided Fibrinogen Gauze versus Simple Gauze in External Packing of Grade IV Liver Injury in Rats. *Bull Emerg Trauma*. 2019;7(1):41-48. doi: 10.29252/beat-070106.

### Introduction

Blunt abdominal trauma (BAT), a common form of trauma, is responsible for considerable

morbidity and mortality rate [1]. Liver is an intra-abdominal organ, frequently injured in blunt and penetrating trauma, and managing its injury has evolved significantly [2]. Although major hepatic

trauma (grades IV and V) based on the American Association for the Surgery of Trauma (ASST) grading, is a rare event, even in trauma centers with high patient volume they are associated with a high rate of morbidity and Mortality [3-5].

Bleeding is still the leading cause of mortality in patients with liver trauma [6]. Despite advances in damage control studies, minimizing bleeding from parenchymal tissue of the liver is still one of the foremost challenges amongst surgeons while trying to save human lives, especially among patients with higher grade of liver injury and higher Injury Severity Score (ISS) [7]. Massive blood loss are associated with the increased rates of morbidity and mortality, which might be related to blood transfusion or blood products [6]. In other words, massive transfusion along with acidosis and hypothermia might result in coagulopathy, leading to death [8]. In addition to blood loss, the lengthy period that requires to control bleeding is another factor associated with the increased mortality [9, 10]. Developing new ways to control hemorrhage results in introducing numbers of hemostatic dressings and applications that were developed and tested in trauma-relevant animal models. The topical hemostatic agents are frequently used when standard surgical technique are unsatisfactory. Currently, plenty of products are available with moderate success level. Some examples are gelatin, collagen, oxidized regenerated cellulose, fibrin sealant glues, and synthetic glues [11-13].

Fibrinogen has been used in surgery since 1940s in which neurosurgeons and plastic surgeons used it for different applications in tissue and nerve repair, wound closure, and skin grafting [14, 15]. An intravenous injection form of Fibrinogen supplementation is currently being used as a therapeutic agent for hemostatic management of trauma related bleeding as part of massive transfusion protocol [16]. It is suggested as the initial procoagulant therapy for patients with massive hemorrhage or in cases that significant bleeding is accompanied by signs of fibrinogen deficiency [17]. To the best of our knowledge, no study has ever evaluated or compared the efficacy of external usage of fibrinogen on liver injury. We aimed to compare intraoperative and postoperative findings on rats that were packed with imbibed fibrinogen gauze after inducing grade IV injury.

## Materials and Methods

### *Ethical Approval*

The study protocol was approved by the local ethics committee of Shiraz University of Medical Sciences, Shiraz, Iran (No IR.SUMS.MED.REC.1396.s146), and in accordance with the international conventions on animal experimentation. All procedures were performed under general anesthesia. We did our best to minimize the animals' suffering during the

experiment. The animals received care in which they were kept in separate clean wire-bottomed cages. Their environment was temperature controlled ( $22^{\circ}\text{C} \pm 2^{\circ}\text{C}$ ) and humidity controlled ( $55\% \pm 15\%$ ), with 12hrs light/dark photo cycles. They had free access to equal amounts of standard rodent chow and water. They were allowed to adapt to their environment for one week prior to the experiment. Before laparotomy, the rats were anaesthetized with intramuscular injection of ketamine (50 mg/kg; Alfasan International, Woerden, the Netherlands), and xylazine (10 mg/kg; Alfasan International). Anesthesia lasted about 20-30 minutes. After inducing laceration, we administrated warm isotonic saline ( $<10\text{ml/kg}$ ) for resuscitation [18]. To control hypothermia, we used rectal temperature (Tr) and the temperature was maintained at  $38.0^{\circ}\text{C} \pm 0.5^{\circ}\text{C}$  with a heating lamp and resuscitation with warm isotonic saline [19, 20].

### *Animals and Hepatic Injury Model*

After consulting with a biostatistician to determine the sample size, a total of 20 healthy adult male Sprague-Dawley rats (with a mean weight of  $300 \pm 50$  gram) were used in this study. The rats were stratified into two groups using a simple randomization method (10 rats per each group); group A: those for which simple gauze was applied to their liver laceration (control group); group B: rats for which imbibed fibrinogen gauze was applied on the liver laceration (case group). Fibrinogen Haemocomplettan, CSL Behring GmbH, 35041 Marburg, Germany) was applied via 70mg/kg. Before laparotomy, the rats were anaesthetized with intramuscular injection of ketamine (50 mg/kg), and xylazine (10 mg/kg). We initiated the surgical procedure after anesthesia. After shaving the abdomen, the incision site was disinfected using alcohol ethylic solution. In the next step, with surgical knife, a vertical incision was made starting from the xiphoid process at about three centimeters long. After opening the abdominal wall, we placed a small orthostatic retractor and identified the liver. After that standardized trauma with knife (20mm in diameter and 5mm in depth) was done in the parenchyma of the major (middle) lobe of the liver and this part of liver was removed by clamp (Figure 1). All surgical procedures were performed by one surgeon in order to minimize the bias. After 2 minutes of uncontrolled bleeding, the bleeding in the intra peritoneal cavity was measured using Tuberculosis Syringe. Then, the packing applied on the injured liver was done according to the group they belonged to. After 15 minutes, the intra peritoneal bleeding was reassessed. Meanwhile, intra peritoneal resuscitation was done with normal saline. Also, the packing remained in both groups after the first operation.

Then, fascia and skin were sutured with PDS 3.0 string. After surgery, the animals were kept in their

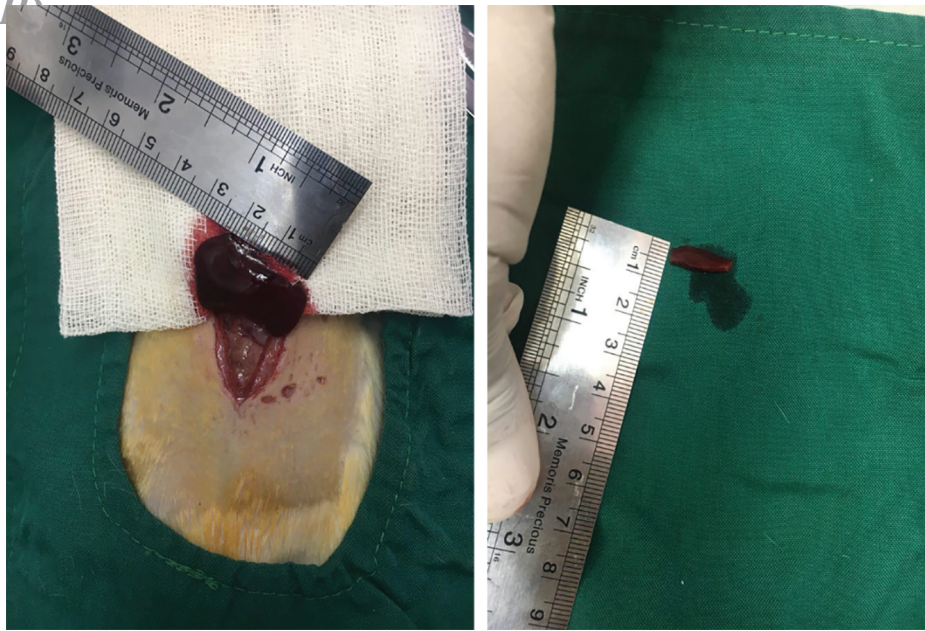

Fig. 1. A laceration model in the middle lobe of the liver.

cages under the care of a veterinarian and standard care including food and water.

After 48 hours, laparotomy was performed again (second look), and hemostasis and the need for repacking were evaluated. To do so, we removed hemostatic agent and gauze to see whether the bleeding had stopped. In the case, which bleeding still remained, we stopped the bleeding by it packing with finger and cauterization. Finally, we closed the abdomen. Also, during the second look, we measured the intra peritoneal bleeding for the third time. From the first day of first operation, we followed the subjects for 14 days. Eventually, we sacrificed the rats and sent their liver for pathology assessment via stereological method. All the specimens were fixed via formalin. The variables collected for the study, were the intra peritoneal bleeding 2 min, 15min and 48hrs after laparotomy, the occurrence of deaths and any histological changes (assessed by stereology method via an operator who was blind to the groups allocation).

#### *Histopathological Evaluation of Liver Injury (Stereology)*

After 14 days, to determine the effect of fibrinogen on healing of the injured liver, we measured the volume and weight of lacerated major-liver lobe. We also measured the normal liver tissue, granulation tissue, amorphous tissue and fibrosis with proportion of lacerated area to total area of liver (via measuring volume density). Livers were fixed in neutral buffered formaldehyde for at least one week. The major middle lobe of liver was separated and the weight and volume measured (according to the immersion method) [21-24]. Coronal sections with equal distances were made through the entire context of major lobe. Then, 10-12 sections for each part of major lobe were sampled through systemic uniform

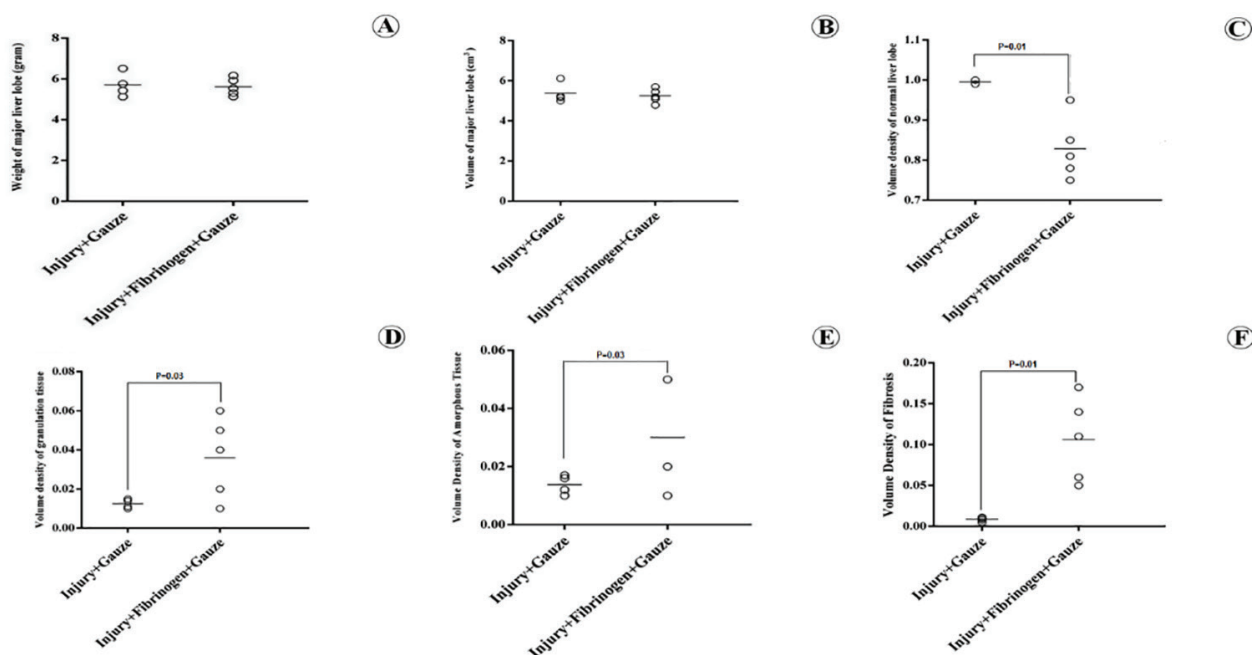
random sampling. The sampled sections were then processed and embedded in the same paraffin block. Four micrometer sections were prepared and stained using Heidenhain's azan trichrome and hematoxylin and eosin.

#### *Estimating the Volume of the Normal Liver Tissue, Granulation Tissue, Amorphous Tissue and Fibrosis*

The microscopic evaluations were done using a computerized video-microscopy system. The stereological counting equipment consisted of a Nikon E-200 microscope (Nikon, Japan) with a motorized stage linked to a computer. To perform stereological counting, the stereological grid of points was generated using a software designed at Shiraz University of Medical Science, Shiraz, Iran, and stereological probes (point grids and counting frames) were superimposed onto the live images of each section. Volume density ( $V_v$ ) refers to fraction of the unit volume of tissues occupied by the structure of interest [21-24]. The volume density of normal liver tissue, granulation tissue, amorphous tissue, and fibrosis (the fraction of unit volume of the liver occupied by normal liver tissue, granulation tissue, amorphous tissue and fibrosis) were estimated using the point counting method [24-27]. Briefly, a grid of points was superimposed on the liver image sections, viewed on the monitor at a final magnification of 180. The density was computed according to the following formula:

$$V_v(\text{structure, reference}) = P(\text{structure}) / P(\text{reference})$$

where "P(structure)" and "P(ref)" represent the total number of the points hitting the structures of interest (normal liver tissue, granulation tissue, amorphous tissue and fibrosis) and the total number of points laid on the profiles of the liver section, respectively (Figure 2) [28-30].



**Fig. 2.** The dot plots of the difference among weight (A) and volume (B) of major liver lobe between the control (gauze packed) and imbibed Fibrinogen gauze groups are shown. Also, dot plots showed volume density of the normal liver lobe (C), granulation tissue (D), amorphous tissue (E), and fibrosis (F) in the injured site of the major liver lobe in the two groups. The differences among the groups is indicated on the plots.

**Statistical Analysis**

Statistical analysis was done by a statistician who was blinded to the study. The results are shown as mean ± standard deviation (SD). Statistical comparisons were performed via Mann–Whitney U-test (version 22; SPSS Statistics software, Chicago, IL). P-Values less than 0.05 were considered to be statistically significant. The results are shown as standard dot plots. Additionally, power analysis was done to find the power of study via Stata software, version 11.2 (Stata Corporation, college station, TX, USA).

**Results**

**Bleeding**

There was no statistically significant difference among intra peritoneal bleeding between group A and B 2 min and 15 min post-liver surgery. However, there was a significant difference between group A and B in intra peritoneal bleeding 48hrs post-liver injury (Table 1).

**Need for Repacking After 48 hours**

In total, 30% (3/10) of rats in gauze packed group

required repacking after 48hrs. Their bleeding was controlled with finger and cauterization (As explained in the method).

**Mortality**

While 50% (5/10) of the rats in group A died, 100% of rats in group B survived after 14 days, which was statistically significant ( $p=0.032$ ). All 5 rats in group A died after 48hrs (second laparotomy).

**Stereological Results**

As shown in Figure 2, there was no significant difference in weight and volume of major lobe between the two groups. Also, volume density of fibrosis, granulation tissue, and amorphous tissue in group B was significantly more than group A (Figures 2 and 3). In contrast, normal liver tissue in group B was less than group A (Figures 2 and 3). Table 2 shows the result. The mean power of our study was 94.5% (the lowest=85%).

**Discussion**

Fibrinogen, the final component of the coagulation pathway, is used in major bleeding [31]. Two main

**Table 1.** Difference in bleeding between control (gauze packed) and imbibed fibrinogen gauze groups.

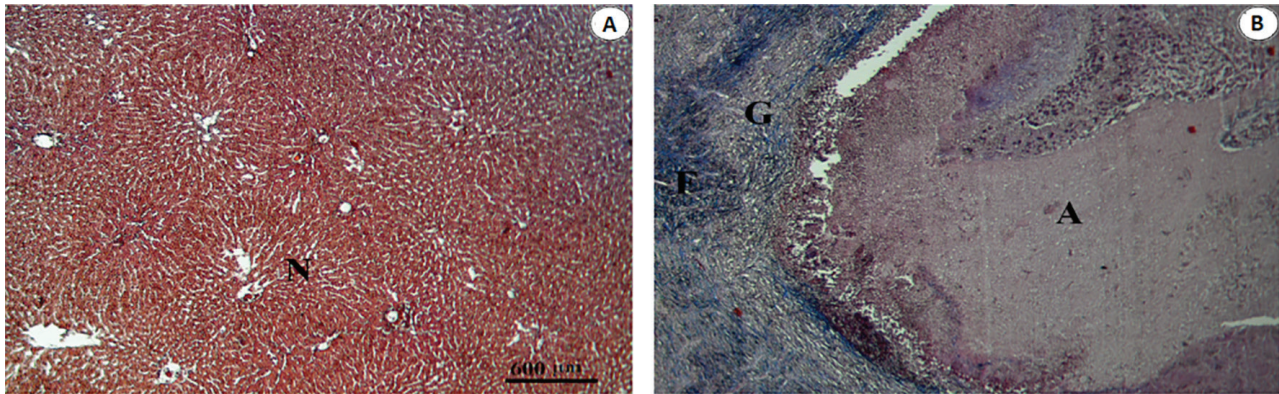
Groups/time	Bleeding in Simple gauze group (mean±SD) <sup>a</sup>	Bleeding in imbibed fibrinogen gauze (mean±SD) <sup>a</sup>	p value
2 min post-surgery	1±0.13	0.95±0.11	0.392
15 min post- surgery	0.15±0.05	0.18±0.06	0.282
48 hours post-surgery	0.79±0.05	0.57±0.06	<0.001

<sup>a</sup>ml

**Table 2.** Comparison between control (gauze packed) and imbibed fibrinogen gauze groups according to stereological results.

Group (Mean±SD)	Simple gauze (N=4)	Imbibed fibrinogen gauze (N=5)	p value
V <sub>v</sub> <sup>a</sup> Normal Liver Tissue	0.994±0.007	0.830±0.076	0.014
V <sub>v</sub> <sup>a</sup> Fibrosis	0.005±0.007	0.10±0.054	0.014
V <sub>v</sub> <sup>a</sup> Granulation Tissue	0.0001±0.0001	0.034±0.022	0.032
V <sub>v</sub> <sup>a</sup> Amorphous	0.0001±0.0001	0.027±0.020	0.032

<sup>a</sup>V<sub>v</sub>=Volume density



**Fig. 3.** The microscopic photomicrograph of the liver in the gauze packed (A), imbibed Fibrinogen gauze (B) groups. A, G, F and N stands for Amorphous, Granulation, Fibrosis and Normal liver tissue.

sources of fibrinogen are currently available in clinical applications; cryoprecipitate and fibrinogen concentrates. Fibrinogen concentrate is easier to store, administer, and safer than cryoprecipitate; however, it is more expensive [17]. Today, it is used in massive transfusion in case of critical bleeding [16]. As a hemostatic agent, it is used in combination with other agents. Frederico Michelino *et al.* used collagen-based adhesive associated with fibrinogen and thrombin in experimental liver injury in Wistar rats, which resulted in controlling hemorrhage with little adhesion [32]. We used pure fibrinogen concentrate and chose simple gauze as a basis for applying it on the injured liver.

Despite the small sample size, we were able to show a trend toward lower blood loss and better healing as well as increasing survival rate after liver packing.

Liver is a common organ injured following abdominal trauma [2, 33], and its injury is a major obstacle in providing successful treatment due to frequency, location and size. Delay in controlling hemorrhage has negative impact on the outcome, leading to high morbidity and mortality [34, 35]. Surgical techniques, such as manual pressure and thermal methods like electrocauterization might lead to scar and necrotic tissue as well as increasing the probability of infection [36, 37]. Additionally, conventional methods are less effective in controlling bleeding in complex injuries, especially when there is difficulty accessing the injured area [37, 38]. Despite numerous endeavors to reduce the related mortality, but it is still inevitable. Mortality rate was reported 30% in the management of complex liver injury with resection [39] and 66% following grade IV and V liver trauma [40]. Furthermore, cirrhosis-

related coagulopathy, blood loss and prolonged surgery might lead to a vicious circle of acidosis, hypothermia and coagulopathy (lethal triad). Hence, finding a new method might help to stop this cycle [41, 42]. According to aforementioned reasons and difficulties, topical homeostatic agents might be particularly useful in such situations.

Until now, several agents have been identified to be applied on injured liver. Hemostatic agents, such as surgicell, thrombin-soaked gel foam, or fibrin glue are useful adjuncts [43]. However, these favorable agents have their own complications like bile leakage and rebleeding [44, 45]. Moreover, Banihashemi *et al.* showed the effectiveness of fibrin packing on stab wounds of the liver, which resulted in the survival of all injured rats [46]. Fibrinogen molecules have two sets of disulfide-bridged Aa-, Bb-, and c-chains. Each molecule has two outer D domains connected to a central E domain by a coiled-coil segment. Fibrin is formed after cleavage of fibrinopeptide A (FPA) from fibrinogen Aa-chains via thrombin, resulting in initiating fibrin polymerization [47]. In addition, Rosselli *et al.* investigated the use of topical bovine-derived thrombin solution as a hemostatic agent in a rodent model of hepatic injury and found this agent to be insufficient in controlling injured liver bleeding [48]. Samokhvalov *et al.* induced grade IV liver laceration in rats and packed it with Celox. They found Celox 100% to be effective in controlling liver bleeding [12]. Another study showed a fully synthetic, polyurethane based glue (MAR-1) as a suitable agent in controlling the bleeding in 50% resection of the lateral left liver lobe in male Wistar rats [49].

Perhepatic gauze packing (PHGP) is an acceptable

## Method in damage control laparotomy for packing the abdominal organs to control bleeding [50, 51].

PHGP became more important, especially when it was compared with controlling bleeding via liver resection that had high mortality and some complications [42, 52-54], but PHGP has its own complications. It sometimes fails to control hepatic hemorrhage and is often associated with massive transfusion and frequent development of abdominal compartment syndrome [55, 56]. In our study, intraperitoneal bleeding in gauze packed group was more than the imbibed fibrinogen gauze group 48hrs after injury. Three subjects in the gauze packed group required repacking after second look, and eventually half of the rats in this group died in the days after operation.

All of our rats in the imbibed fibrinogen gauze group survived after 14 days of follow-up. Measurement of bleeding 15 minutes and 48hrs after operation was lower in comparison to simple gauze packed group. Therefore, fibrinogen had a better impact on controlling hemorrhage at the time of operation and the subsequent days after operation. Interestingly, our imbibed fibrinogen-gauze group show no need for repacking. Moreover, volume density of granulation tissue and fibrosis were more than our control group. Therefore, our rats experienced better healing during the 14 days of follow-up, which resulted in 100% survival. As far as we know, fibrinogen has not been used for external packing of liver in any other study. Thus, this study is unique in introducing new agent to control bleeding in trauma of the liver, opening

a new horizon for it to be used in liver injury in humans.

One of our limitations was the second look for the evaluation of hemostasis. Although fibrinogen showed its efficacy in controlling the bleeding, second look while using gauze was inevitable. Hence, finding a proper base for applying fibrinogen on the liver is still a challenging matter. Another limitation was that we did not measure bile leakage during the days following operation, but we assumed that due to more fibrosis in the rats packed with imbibed fibrinogen gauze group, lesser bile leakage might had occurred in comparison to gauze packed group.

To conclude, this study showed that imbibed fibrinogen gauze resulted in no mortality, significant fibrosis and granulation tissue on injured area and efficient hemorrhage control. Thus, treatment with imbibed fibrinogen gauze is potentially effective in experimental liver trauma.

## Acknowledgment

This study was supported by Shiraz University of Medical Sciences and approved with code No. 94-01-01-9658. The study was extracted from the thesis written by Golnoush Sadat Mahmoudi Nezhad for M.D. degree. The authors wish to thank Mr. H. Argasi at the Research Consultation Center (RCC) of Shiraz University of Medical Sciences for his invaluable assistance in editing this manuscript.

**Conflicts of Interest:** None declared.

## References

1. Malhotra P, Sharma D, Gupta S, Minhas S. Clinico epidemiological study of blunt abdominal trauma in a tertiary care hospital in north western Himalayas. *International Surgery Journal*. 2017;**4**(3):874-82.
2. Swift C, Garner JP. Non-operative management of liver trauma. *JR Army Med Corps*. 2012;**158**(2):85-95.
3. Diório AC, Fraga GP, Dutra Júnior I, Joaquim JLDGC, Mantovani M. Predictive factors of morbidity and mortality in hepatic trauma. *Revista do Colégio Brasileiro de Cirurgiões*. 2008;**35**(6):397-405.
4. Asensio JA, Demetriades D, Chahwan S, Gomez H, Hanpeter D, Velmahos G, et al. Approach to the management of complex hepatic injuries. *J Trauma*. 2000;**48**(1):66-9.
5. Tominaga GT, Staudenmayer KL, Shafi S, Schuster KM, Savage SA, Ross S, et al. The American Association for the Surgery of Trauma grading scale for 16 emergency general surgery conditions: Disease-specific criteria characterizing anatomic severity grading. *J Trauma Acute Care Surg*. 2016;**81**(3):593-602.
6. Nouri S, Sharif MR, Afzali H, Sharif A, Satkin M. The Advantages and Disadvantages of Methods Used to Control Liver Bleeding: A Review. *Trauma Mon*. 2015;**20**(4):e28088.
7. Doklestic K, Stefanovic B, Gregoric P, Ivancevic N, Loncar Z, Jovanovic B, et al. Surgical management of AAST grades III-V hepatic trauma by Damage control surgery with perihepatic packing and Definitive hepatic repair-single centre experience. *World J Emerg Surg*. 2015;**10**:34.
8. Ivatury RR, Nallathambi M, Gunduz Y, Constable R, Rohman M, Stahl WM. Liver packing for uncontrolled hemorrhage: a reappraisal. *J Trauma*. 1986;**26**(8):744-53.
9. Woolley T, Thompson P, Kirkman E, Reed R, Ausset S, Beckett A, et al. Trauma Hemostasis and Oxygenation Research Network position paper on the role of hypotensive resuscitation as part of remote damage control resuscitation. *J Trauma Acute Care Surg*. 2018;**84**(6S Suppl 1):S3-S13.
10. Bardes JM, Inaba K, Schellenberg M, Grabo D, Strumwasser A, Matsushima K, et al. The contemporary timing of trauma deaths. *Journal of Trauma and Acute Care Surgery*. 2018;**84**(6):893-9.
11. Genyk Y, Kato T, Pomposelli JJ, Wright JK, Jr., Sher LS, Tetens V, et al. Fibrin Sealant Patch (TachoSil) vs Oxidized Regenerated Cellulose Patch (Surgicel Original) for the Secondary Treatment of Local Bleeding in Patients Undergoing Hepatic Resection: A Randomized Controlled Trial. *J Am Coll Surg*. 2016;**222**(3):261-8.
12. Samokhvalov IM, Golovko KP, Reva VA, Zhabin AV, Denisov AV, Sokhranov MV, et al. The use of local hemostatic agent "Celox" in experimental model of grade IV liver injury. *Voen Med Zh*. 2013;**334**(11):24-30.
13. Kakaei F, Seyyed Sadeghi MS, Saneii B, Hashemzadeh S, Habibzadeh A. A randomized clinical trial comparing the effect of different haemostatic agents for haemostasis of the liver after hepatic resection. *HPB Surg*.

14. Yong J, Medawar P. Fibrin Suture of Peripheral Nerves. Measurement of the Rate of Regeneration. *Lancet*. 1940;**239**:126.
15. Spangler HP, Braun F, Holle J, Moritz E, Wolner E. The local application of fibrinogen and collagen for hemostasis in heart surgery. *Wien Med Wochenschr*. 1976;**126**(7):86-9.
16. Ali J, Rizoli S, Pavenski K. The Coagulopathic Trauma Patient and Massive Transfusion Protocol. *The Surgical Critical Care Handbook: Guidelines for Care of the Surgical Patient in the ICU*: World Scientific; 2016. p. 201-22.
17. Novak A, Stanworth SJ, Curry N. Do we still need cryoprecipitate? Cryoprecipitate and fibrinogen concentrate as treatments for major hemorrhage - how do they compare? *Expert Rev Hematol*. 2018;**11**(5):351-60.
18. Turner PV, Brabb T, Pekow C, Vasbinder MA. Administration of substances to laboratory animals: routes of administration and factors to consider. *J Am Assoc Lab Anim Sci*. 2011;**50**(5):600-13.
19. Greene SP, Soucy DM, Song WC, Barber AE, Hagedorn FN, Illner HP, et al. Early isotonic saline resuscitation from uncontrolled hemorrhage in rats. *Surgery*. 1998;**124**(3):568-74.
20. Iwamoto S, Takasu A, Sakamoto T. Therapeutic mild hypothermia: effects on coagulopathy and survival in a rat hemorrhagic shock model. *J Trauma*. 2010;**68**(3):669-75.
21. Abidu-Figueiredo M, Ribeiro IC, Chagas MA, Cardoso LE, Costa WS, Sampaio FJ. The penis in diabetes: structural analysis of connective tissue and smooth muscle alterations in a rabbit model. *BJU Int*. 2011;**108**(3):400-4.
22. Costa WS, Rebello SB, Cardoso LE, Cavalcanti AG, Sampaio FJ. Stereological and biochemical analysis of muscular and connective tissue components in the penile corpus cavernosum adjacent to the fibrous plaque of Peyronie's disease. *BJU international*. 2009;**103**(2):212-6.
23. Geuna S, Herrera-Rincon C. Update on stereology for light microscopy. *Cell Tissue Res*. 2015;**360**(1):5-12.
24. Nyengaard JR. Stereologic methods and their application in kidney research. *J Am Soc Nephrol*. 1999;**10**(5):1100-23.
25. Gundersen HJ, Bagger P, Bendtsen TF, Evans SM, Korbo L, Marcussen N, et al. The new stereological tools: disector, fractionator, nucleator and point sampled intercepts and their use in pathological research and diagnosis. *APMIS*. 1988;**96**(10):857-81.
26. Gundersen HJ, Bendtsen TF, Korbo L, Marcussen N, Moller A, Nielsen K, et al. Some new, simple and efficient stereological methods and their use in pathological research and diagnosis. *APMIS*. 1988;**96**(5):379-94.
27. Muhlfeld C, Nyengaard JR, Mayhew TM. A review of state-of-the-art stereology for better quantitative 3D morphology in cardiac research. *Cardiovasc Pathol*. 2010;**19**(2):65-82.
28. Karbalay-Doust S, Noorafshan A, Pourshahid SM. Taxol and taurine protect the renal tissue of rats after unilateral ureteral obstruction: a stereological survey. *Korean J Urol*. 2012;**53**(5):360-7.
29. Noorafshan A, Ebrahimipour MR, Sadeghi Y. Stereological study of the cells of dorsal root ganglia in male diabetic rats. *APMIS*. 2001;**109**(11):762-6.
30. Shirazi M, Rahimi M, Noorafshan A. Single vs. double layer suturing method repair of the urethral plate in the rabbit model of hypospadias. *Cent European J Urol*. 2016;**69**(4):425-30.
31. Levy JH, Welsby I, Goodnough LT. Fibrinogen as a therapeutic target for bleeding: a review of critical levels and replacement therapy. *Transfusion*. 2014;**54**(5):1389-405; quiz 8.
32. Oliveira FM, Carvalho MV, Marchi E, Pinto CA. The collagen, fibrinogen and thrombin biological adhesive is effective in treating experimental liver injuries. *Rev Col Bras Cir*. 2016;**43**(2):110-6.
33. Matthes G, Stengel D, Seifert J, Rademacher G, Mutze S, Ekkernkamp A. Blunt liver injuries in polytrauma: results from a cohort study with the regular use of whole-body helical computed tomography. *World J Surg*. 2003;**27**(10):1124-30.
34. Clancy TV, Gary Maxwell J, Covington DL, Brinker CC, Blackman D. A statewide analysis of level I and II trauma centers for patients with major injuries. *J Trauma*. 2001;**51**(2):346-51.
35. Richardson JD. Changes in the management of injuries to the liver and spleen. *J Am Coll Surg*. 2005;**200**(5):648-69.
36. Ponz CB, Trias M. Laparoscopic surgery and surgical infection. *Journal of Chemotherapy*. 2001;**13**(sup4):17-22.
37. Seyednejad H, Imani M, Jamieson T, Seifalian AM. Topical haemostatic agents. *Br J Surg*. 2008;**95**(10):1197-225.
38. Tan SR, Tope WD. Effectiveness of microporous polysaccharide hemospheres for achieving hemostasis in Mohs micrographic surgery. *Dermatol Surg*. 2004;**30**(6):908-14.
39. Polanco P, Leon S, Pineda J, Puyana JC, Ochoa JB, Alarcon L, et al. Hepatic resection in the management of complex injury to the liver. *J Trauma*. 2008;**65**(6):1264-9; discussion 9-70.
40. Duane TM, Como JJ, Bochicchio GV, Scalea TM. Reevaluating the management and outcomes of severe blunt liver injury. *J Trauma*. 2004;**57**(3):494-500.
41. Senzolo M, Burra P, Cholongitas E, Burroughs AK. New insights into the coagulopathy of liver disease and liver transplantation. *World J Gastroenterol*. 2006;**12**(48):7725-36.
42. Patrono D, Romagnoli R, Tandoi F, Maroso F, Bertolotti G, Berchiolla P, et al. Peri-hepatic gauze packing for the control of haemorrhage during liver transplantation: A retrospective study. *Dig Liver Dis*. 2016;**48**(4):414-22.
43. Kaptanoglu L, Kurt N, Sikar HE. Current approach to liver traumas. *International Journal of Surgery*. 2017;**39**:255-9.
44. Zacharias T, Ferreira N. Carrier-bound fibrin sealant compared to oxidized cellulose application after liver resection. *HPB (Oxford)*. 2012;**14**(12):839-47.
45. Mayol JM, Zapata C. Gelatin-thrombin matrix for intraoperative hemostasis in abdomino-pelvic surgery: a systematic review. *Surg Technol Int*. 2013;**23**:23-8.
46. Banihashemi M, Safari A, Nezafat N, Tahamtan M, Negahdaripour M, Azarpira N, et al. Effect of Fibrin Packing on Managing Hepatic Hemorrhage and Liver Wound Healing in a Model of Liver Stab Wound in Rat. *Bull Emerg Trauma*. 2017;**5**(1):18.
47. Mosesson MW. Fibrinogen and fibrin structure and functions. *J Thromb Haemost*. 2005;**3**(8):1894-904.
48. Rosselli DD, Brainard BM, Schmiedt CW. Efficacy of a topical bovine-derived thrombin solution as a hemostatic agent in a rodent model of hepatic injury. *Can J Vet Res*. 2015;**79**(4):303-8.
49. Srinivasan PK, Sperber V, Afify M, Tanaka H, Fukushima K, Kogel B, et al. Novel synthetic adhesive as an effective alternative to Fibrin based adhesives. *World J Hepatol*. 2017;**9**(24):1030-9.
50. Paydar S, Mahmoodi M, Jamshidi M, Niakan H, Keshavarz M, Moeenvaziri N, et al. Perihepatic Packing versus Primary Surgical Repair in Patients with Blunt Liver Trauma; an 8-year Experience. *Bull Emerg Trauma*. 2014;**2**(3):103-9.

51. Ebrahimi S, Tahmasebi S, Rouhezamin MR, Mousavi SM, Abbasi HR, Bolandparvaz S, et al. Modified Perihepatic Packing; A Creative and Beneficial Method for Management of High Grade Liver Injury. *Bull Emerg Trauma*. 2013;1(1):22-7.
52. Feliciano DV, Mattox KL, Jordan GL, Jr. Intra-abdominal packing for control of hepatic hemorrhage: a reappraisal. *J Trauma*. 1981;21(4):285-90.
53. Feliciano DV, Mattox KL, Burch JM, Bitondo CG, Jordan JG. Packing for control of hepatic hemorrhage. *The Journal of trauma*. 1986;26(8):738-43.
54. Kozar RA, Feliciano DV, Moore EE, Moore FA, Cocanour CS, West MA, et al. Western Trauma Association/ critical decisions in trauma: operative management of adult blunt hepatic trauma. *J Trauma*. 2011;71(1):1-5.
55. Raeburn CD, Moore EE, Biffi WL, Johnson JL, Meldrum DR, Offner PJ, et al. The abdominal compartment syndrome is a morbid complication of postinjury damage control surgery. *Am J Surg*. 2001;182(6):542-6.
56. Bradley MJ, Dubose JJ, Scalea TM, Holcomb JB, Shrestha B, Okoye O, et al. Independent predictors of enteric fistula and abdominal sepsis after damage control laparotomy: results from the prospective AAST Open Abdomen registry. *JAMA Surg*. 2013;148(10):947-54.

#### Open Access License

All articles published by Bulletin of Emergency And Trauma are fully open access: immediately freely available to read, download and share. Bulletin of Emergency And Trauma articles are published under a Creative Commons license. Mandated authors will be offered CC-BY; all other authors will choose between CC-BY, CC-BY-NC and CC-BY-NC-ND.