



## Diagnostic Accuracy of Abdominal Ultrasonography in Pediatric Acute Appendicitis

Alireza Pedram<sup>1</sup>, Fatemeh Asadian<sup>2\*</sup>, Naghmeh Roshan<sup>3</sup>

<sup>1</sup>International Branch, School of Medicine, Shiraz University of Medical Sciences, Shiraz, Iran

<sup>2</sup>Department of Medical Laboratory Sciences, School of Paramedical Sciences, Shiraz University of Medical Sciences, Shiraz, Iran

<sup>3</sup>Shoashtari Hospital, School of Medicine, Shiraz University of Medical Sciences, Shiraz, Iran

\*Corresponding author: Fatemeh Asadian

Address: Department of Medical Laboratory Sciences, School of Paramedical Sciences, Shiraz, Iran. Tel: +98-917-7056487; Fax: +98-71-32279113  
e-mail: asadian@sums.ac.ir

Received: December 11, 2018

Revised: June 6, 2019

Accepted: June 26, 2019

### ABSTRACT

**Objective:** To evaluate the diagnostic accuracy of ultrasonography in pediatric acute appendicitis.

**Methods:** In this cross-sectional study, 230 children aged 5-15 years with the diagnosis of acute appendicitis were studied. This study included the evaluation of demographic indices, ultrasound findings at diagnosis, and then comparing the results with the description of the patient's procedure and the pathology report of these patients. Patients who did not undergo ultrasound before surgery or their ultrasound did not include the evaluation of appendicitis or their pathologic report was not available were excluded.

**Results:** Overall, we have included a total number of 230 children with clinical diagnosis of acute appendicitis among whom there were 121 (52.6%) girls and 109 (47.4%) boys with mean age of 11.44±2.90 years. Preoperative ultrasound report showed that 51.3% were normal and 48.7% had acute appendicitis. 34.8% had normal appendix and 65.2% had a pathological diagnosis of acute appendicitis. The sensitivity and specificity of ultrasound in these children were 58% and 68%, respectively. Positive and negative predictive values were 77% and 46%, respectively. The area under curve (AUC) was 0.853 (CI 95% 0.788-0.917) indicating a test with moderate accuracy.

**Conclusion:** According to the obtained results, abdominal ultrasonography is of acceptable diagnostic accuracy in pediatric patients with acute appendicitis. The use of auxiliary techniques in ultrasound would increase the sensitivity and specificity in the diagnosis of acute appendicitis in children.

**Keywords:** Ultrasonography; Appendicitis; Sensitivity; Specificity; Children.

Please cite this paper as:

Pedram AR, Asadian F, Roshan N. Diagnostic Accuracy of Abdominal Ultrasonography in Pediatric Acute Appendicitis. *Bull Emerg Trauma*. 2019;7(3):278-283. doi:

### Introduction

Acute appendicitis is one of the most common causes of abdominal pain in patients referring to the emergency department, and appendectomy is one of the most commonly used emergency

medical surgeries worldwide [1-3]. This disease is caused by intratubular obstruction, accumulation of fecal matter, lymphoid hyperplasia, ingestion of foreign objects, parasites and tumors. Appendicitis occurs less in children compared with adults, but its complications are more prevalent in children [4, 5].

**Archive of SID**

Acute appendicitis is common among children and has the potential to be a very serious disease [6]. Each year, 80000 children in the United States suffer from appendicitis. The rate of developing this disease in children under 14 years of age is 4 per 1000. The most common age of developing appendicitis in children is 12–18 years of age [6-8]. Since acute appendicitis can progress quickly and move towards more complex pathologies, the early and correct diagnosis of acute appendicitis is necessary to reduce the risk of perforation [9, 10]. Moreover, lack of timely diagnosis causes complications such as gangrene and rupture of the appendix that lead to peritonitis, phlegmon and abscesses [2, 6]. Diagnosis of acute appendicitis is based on clinical symptoms. The clinical symptoms of acute appendicitis are completely different. Symptoms can be classic or variable [11, 12]. The classic clinical symptoms of appendicitis include abdominal pain, nausea and vomiting, anorexia and general boredom, occurring in less than 50% of cases, so most cases of acute appendicitis have atypical symptoms. Diagnosis of acute appendicitis in children is more difficult than adults. This is due to the controversial nature of biography and examination in children and the occurrence of symptoms in atypical form in them [11].

Despite the advances in imaging technology, the hallmark of acute appendicitis is still based on patient biography and careful examination. Nevertheless, in addition to clinical examinations, the use of imaging can be very helpful in the correct diagnosis and reduction of the risk of progression of the disease and reduce the negative appendectomy rate [10]. In some studies, ultrasound, CT scan and MRI are used to increase the accuracy of diagnosis, and in some cases it is said to improve prognosis. However, the common use of them has not yet been proven [9]. Studies have shown that the use of ultrasound and CT scan before surgery can reduce the negative appendectomy rate and increase the accuracy of diagnosis [13-15]. However, some studies did not indicate increase in the diagnosis of negative appendectomy rate and the reduction of complications [15, 16]. The noteworthy point is that the use of low-risk methods for children is very important [9].

Ultrasound is an easy and inexpensive method with high precision for diagnosis of internal defects and is recommended for the evaluation of acute appendicitis. Diagnostic criteria of appendicitis in ultrasound are wall thickness of more than 6 mm, luminal dilatation and presence of mass in R.L.Q or fecalith. Many studies have been conducted on the use of ultrasound to confirm or reject acute appendicitis in suspected patients, but its accuracy is still unclear [14, 16]. An ultrasound of the appendix may be helpful even in patients with abnormal signs, including children and the elderly whose diagnosis is often delayed [14, 16]. Although the diagnostic accuracy depends on the operator, it seems that auxiliary diagnosis with ultrasound can be considered as a low-risk diagnostic method with high sensitivity [17, 18].

However, there are always contradictory opinions in studies, and there are no supplementary studies to confirm or reject this issue. Therefore, the aim of this study was to evaluate the sensitivity and specificity of ultrasound to detect acute appendicitis in children in order to reduce the negative appendectomy rate.

**Materials and Methods***Study Population*

This cross-sectional study was performed on 230 children aged 5 to 15 years with clinical diagnosis of acute appendicitis who referred to Shahid Motahari Hospital of Marvdasht in 2017 and underwent appendectomy. 230 children aged 5 to 15 years who referred to Shahid Motahari Hospital of Marvdasht and were diagnosed with acute appendicitis, ultrasound was performed for them before surgery and underwent appendicitis surgery and their pathologic results were available. It should be noted that all information about ultrasound, operation descriptions and patient's pathology reports were collected from the archives of medical records of Shahid Motahari Hospital of Marvdasht and, if necessary, from separate archives of Radiology and Laboratory of Shahid Motahari Hospital of Marvdasht. The inclusion criteria of samples were diagnosis of acute appendicitis with abdominal pain, including pain in the right iliac fossa or lower abdominal pain or other clinical symptoms suspected of acute appendicitis. The exclusion criteria were patients who did not undergo ultrasound prior to surgery or their ultrasound did not show appendicitis or their pathologic report was not available. The study protocol was approved by the Shiraz University of Medical Sciences medical ethics committee and institutional review board. As this was retrospective study, no informed written consent was needed.

*Study Protocol*

In this study, the ultrasound findings of the samples were evaluated at the time of diagnosis along with the patient's procedure description and the pathology report of the patients. The Ethics Committee approval of Shiraz University of Medical Sciences was obtained for this study. Ultrasound findings, findings during surgery, pathologic findings in the archives of medical records and radiology, and the laboratory of Shahid Motahari Hospital of Marvdasht. Positive pathologic report indicates any pathological evidence of inflammation in the studied tissue, which is categorized into seven groups according to the following criteria:

1. No specific sign of inflammation or appendicitis: normal appendix tissue and lack of appendicitis symptom.
2. Reactive follicular hyperplasia: stimulation of the tissue and the presence of lymphoid aggregation.
3. Early acute appendicitis: entrance of

## Analysis of SID

polymorphonuclear leukocytes (PMN) into the mucosal layer of appendix.

4. Acute appendicitis: entrance of polymorphonuclear leukocytes (PMN) into the muscular layer of the appendix.

5. Acute appendicitis and periappendicitis: entrance of polymorphonuclear leukocytes (PMN) into the serosa layer.

6. Acute suppurative appendicitis: high accumulation of polymorphonuclear leukocytes (PMN) into the entire appendix wall.

7. Acute gangrenous appendicitis: appendix wall necrosis

Stages 1 and 2 were considered as a normal appendix in the pathology report and from stage 3 on, were considered as appendicitis, and we used it as a definitive diagnosis for evaluating the ultrasound parameters.

### Ultrasonography

Abdominal ultrasound was performed using the graded compression technique with a 5.0-MHz linear array transducer. Positive ultrasound results for appendicitis was defined as the presence of an enlarged non-compressible appendix with an outer wall diameter greater than 6 mm, the presence of a complex mass, or the presence of an appendicolith. And the absence of ultrasound evidence was considered as a normal appendix. In the patients' procedure description, based on the evidence provided by the surgeon, any macroscopic evidence of inflammation was considered as appendicitis. The ultrasound data were correlated with surgical and pathological findings. After extraction, these data were recorded in a checklist for data collection and further analysis.

### Statistical Analysis

Sampling was done randomly. Sample size was calculated based on  $\alpha = 0.9$ ,  $p=0.05$  and  $d: 0.04$ . After collected of information, results were evaluated by statistical package for social sciences (SPSS Inc., Chicago, Illinois, USA) for Windows, version 18.0.

Descriptive data were collected from the frequency distribution table, central indexes, distribution and percentages. Continuous quantitative data were compared between the two groups using the independent t-test and Chi-Square test were used to compare the discrete data between the groups. In addition, the correlations between variables were performed and 0.05 was considered as the significance level.

### Results

This cross-sectional study was performed on 230 children aged 5 to 15 years with clinical diagnosis of acute appendicitis. Of these children, 121 (52.6%) were girls and 109 (47.4%) were boys. The mean age of the samples was  $11.44 \pm 2.90$  years. The results showed that there was no significant difference between the studied samples in terms of age and gender (Table 1).

The results of the ultrasound report showed that 118 (51.3%) of the samples had normal ultrasound while 112 (48.7%) had acute appendicitis. 7 samples (3%) had normal procedure description, and 223 (97%) had procedure description of acute appendicitis. Overall, 80 patients (34.8%) had normal pathologic report of appendix and 150 (65.2%) had pathological report of acute appendicitis (Table 2).

The results showed that in this study, the true positive rate of ultrasound diagnosis was 87 relatives to pathology report, the false positive diagnosis rate was 25, the true negative rate was 55 and the false negative rate was 63. The correlation between the ultrasound detection and in acute appendicitis showed  $R^2$  of 0.048 ( $r=0.225$ ). The best cutoff for sonography detection, for measurement of outer wall to outer wall diameter was  $>6$  mm with a specificity 58%, a sensitivity of 68%, and a zone under the curve of 0.853 (CI 95% 0.788-0.917). In addition, the positive and negative predictive value of ultrasound for diagnosis of acute appendicitis was calculated to be 77% and 46%, respectively (Figure 1).

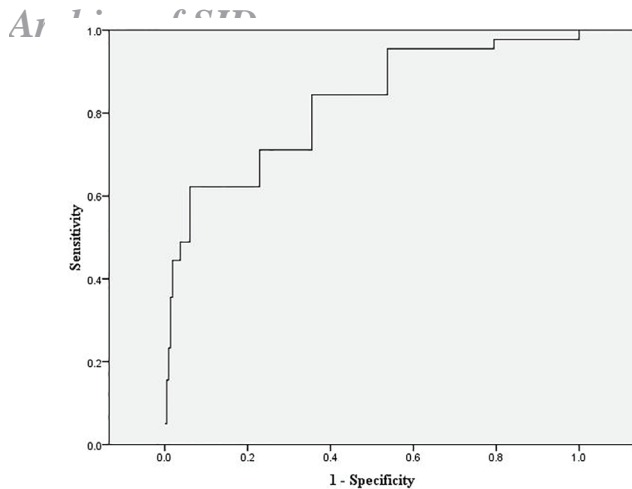
**Table 1.** The baseline characteristics of the patients with acute appendicitis in the current study

Variation	Boys	Girls	Total	p value
Sex	109 (47.4%)	121 (52.6%)	230 (100%)	0.090
Age (year)	12.04 $\pm$ 2.76	10.77 $\pm$ 2.92	11.44 $\pm$ 2.90	0.184

**Table 2.** The results of the ultrasound, procedure description and pathological report of the patients with acute appendicitis in the current study

		Boys	Girls	Total	p value
Ultrasound	Normal	45 (41.3%)	73 (60.3%)	118 (51.3%)	0.004
	AA <sup>a</sup>	64 (58.7%)	48 (39.7%)	112 (48.7%)	
Procedure description	Normal	4 (3.7%)	3 (2.5%)	7 (3%)	0.611
	AA	105 (96.3%)	118 (97.5%)	223 (97%)	
Pathology report	Normal	30 (27.5%)	50 (41.3%)	80 (34.8%)	0.055
	AA	79 (72.5%)	71 (58.7%)	150 (65.2%)	

<sup>a</sup>AA: Acute appendicitis



**Fig. 1.** Receiver–operating characteristics (ROC) curve for the diagnostic accuracy of ultrasonography in pediatric acute appendicitis. Area under curve (AUC) = 0.853 (CI 95% 0.788-0.917) suggestive of moderate accuracy.

## Discussion

Acute appendicitis is one of the most common causes of abdominal pain and one of the most common causes of emergency surgery worldwide [1]. In most cases, the diagnosis is based on clinical records and clinical examinations, most notably with pain in the central abdominal region, which then moves toward the right iliac fossa [4, 5]. However, appendicitis occasionally occurs with an atypical manifestation. Therefore, it leads to a delay in diagnosis or misdiagnosis. According to studies, the unnecessary laparotomy rate for acute appendicitis is about 20-25%. This rate even reaches 35-45% in women of childbearing age, due to pelvic organ diseases in women and complications of pregnancy in this group [19]. Management of patients with clinical suspicion of acute appendicitis include the decision to operate the patient or not to operate the patient. Therefore, any type of examination that will improve the accuracy of the diagnosis will be helpful [20].

The goal of imaging in diagnosing acute appendicitis is to increase the diagnostic efficiency, along with lowering the cost and risk for the patient [10]. Some studies have suggested that, in cases where appendicitis is difficult to diagnose based on clinical symptoms, graded compression ultrasound is very helpful and the negative appendectomy rate is reduced [13-15].

The results of this study showed that the true positive rate of ultrasound diagnosis was 87, the false positive rate was 25, the true negative rate was 55, and the false negative rate was 63. The sensitivity and specificity of ultrasonography in the diagnosis of acute appendicitis compared to pathology report was 58% and 68%, respectively. The positive and negative predictive value of ultrasound for diagnosis of acute appendicitis was calculated to be 77% and 46%, respectively.

Several studies have been conducted on the use of

ultrasound to confirm or exclude acute appendicitis in suspected patients [13-16]. In the study of Blank *et al.*, all 6 cases of abscess and 4 of the 5 cases of ruptured appendix were diagnosed correctly by ultrasound [21]. In the study of Abu-Yousef *et al.*, the sensitivity and specificity of ultrasound diagnosis were calculated to be 80 and 95%. In this study, according to the pathologist, two of the three cases of appendicitis were diagnosed with ultrasound [19]. In addition, the sensitivity and specificity of ultrasound in the diagnosis of acute appendicitis in the study of Chen *et al.* were 96.4% and 67.6%, respectively [22]. In the study of Lessin *et al.*, the sensitivity and specificity of ultrasound in the diagnosis of acute appendicitis in children were 88% and 96%, respectively, and were significantly higher than the clinical symptoms [23]. In a study by Ramachandran *et al.*, the abdominal ultrasound had a sensitivity of 90%, specificity of 96%, and accuracy of 95% [24]. In a study in a general hospital in 2005, sensitivity of ultrasound was 66.66% [25]. In the study of Scammell *et al.*, sensitivity of ultrasound as a diagnostic method for acute appendicitis was 83.3% and specificity was 97.4% [26].

However, in a study by Marusch *et al.* that was performed on 3924 suspected acute appendicitis patients, the results showed low consistency of ultrasound findings with pathologic reports: in 68.2% of cases whose acute appendicitis was detected by pathologist, ultrasound was not able to detect signs of inflammation. In this study, ultrasound sensitivity was reported 21.5% [27]. In addition, according to various studies, the sensitivity of diagnosis of acute appendicitis by ultrasound was 78 to 96%, with a specificity of 85 to 98%. Some studies reported that ultrasound examination in patients suspected of acute appendicitis reduced the incidence of unnecessary appendectomy by up to 7% and reduced the 6-hour delay of surgical operation by 2%. However, the quality of the results was highly dependent on the skill and the accuracy of the person who performed the ultrasound. Therefore, one of its disadvantages is its dependence on the individual who causes the difference in the results of various studies [13-16, 24-26].

According to recent studies, to diagnose acute appendicitis, the finding that is most visible in ultrasound and is accepted by radiologists, is the existence of enlarged non-compressible appendix with a maximum anterior-posterior diameter of 6 mm or more [13-16, 25]. Additionally, in acute appendicitis, the blood flow with circumferential view is recorded in the appendix wall. Therefore, the presence of blood flow with circumferential view in the appendix wall can be a strong confirmation of the diagnosis of acute appendicitis. Despite the high accuracy of ultrasound in the diagnosis of acute appendicitis, there are always limitations and problems with the use of this method, which leads to false positive and negative responses [28]. Ruptured appendix reduces the accuracy of ultrasound

The accuracy of ultrasound in detecting appendicitis complications, such as appendectomy abscess or gangrene appendicitis, is more than when a person has only one uncomplicated inflamed appendix [30]. The patient's inhibition and lack of cooperation with ultrasound procedure due to pain even in uncomplicated acute appendicitis is also mentioned as a reason for the failure of ultrasound to detect acute appendicitis [19]. Moreover, the presence of gas-filled bowel loops in the lower right quadrant of the abdomen of obese patients, and the absence of transducers with high resolution can be considered as other causes of false negative ultrasound for the observation of small structures, such as uncomplicated inflamed appendicitis [19]. Thus, 15-30% negative appendectomy was reported in developed countries [4]. In various studies, the rate of finding a worm-shaped appendix was between 60-80% with sensitivity and specificity of more than 90% [31].

Studies have shown that the sensitivity of ultrasound to detect acute appendicitis was 55-96% and the specificity is 85-98%. The sensitivity of ultrasound to detect acute appendicitis was also reported to be 95% and reported to be 97% in another study. Studies also show that in the hands of experienced

people, ultrasound has a sensitivity of 75-95% with a diagnostic accuracy of 87-96% [32-34].

Recent studies have shown that Color Doppler ultrasound is a reliable method for detecting acute appendicitis. Adding Color Doppler to ultrasound examination can improve the diagnostic accuracy for detecting acute appendicitis [34]. Quillin *et al.* showed that Color Doppler ultrasound had a sensitivity of 87% and accuracy of 93% in the diagnosis of acute appendicitis [34].

Therefore, these findings suggest that ultrasound can be used to detect acute appendicitis in patients using appropriate devices and experienced professionals.

In conclusion, ultrasound can be used in children with clinical diagnosis or suspicion of acute appendicitis according to patient's condition. Although the accuracy of the diagnosis is dependent on the operator, it seems that it can be considered as a low-risk diagnostic method with high sensitivity. It also seems that using this method can play an effective role in reducing negative appendectomy rate. Therefore, the use of auxiliary techniques in ultrasound would increase the sensitivity and specificity in the diagnosis of acute appendicitis.

**Conflicts of Interest:** None declared.

## References

- Pinto F, Pinto A, Russo A, Coppolino F, Bracale R, Fonio P, et al. Accuracy of ultrasonography in the diagnosis of acute appendicitis in adult patients: review of the literature. *Crit Ultrasound J*. 2013;5 Suppl 1:S2.
- Bhangu A, Søreide K, Di Saverio S, Assarsson JH, Drake FT. Acute appendicitis: modern understanding of pathogenesis, diagnosis, and management. *Lancet*. 2015;386(10000):1278-1287.
- Yıldız T, İlçe Z, Turan G, Bozdağ Z, Elmas B. Parasites in the Etiology of Pediatric Appendicitis. *Turkiye Parazitol Derg*. 2015;39(3):190-3.
- Öztaş T, Dursun A, Söğütçü N, Bilici S. Unusual Histopathological Findings in Appendectomy Specimens Obtained from 1683 Pediatric Patients with Suspected Acute Appendicitis. *Indian Journal of Surgery*. 2018;1-6.
- Okoro KU, De La Espriella MG, Grider DJ, Baffoe-Bonnie AW. Tuberculous Enteritis Presenting as Acute Appendicitis and Perirectal Abscess. *Case Rep Med*. 2018;2018:6068258.
- Almaramhy HH. Acute appendicitis in young children less than 5 years: review article. *Ital J Pediatr*. 2017;43(1):15.
- Short HL, Sarda S, Travers C, Hockenberry JM, McCarthy I, Raval MV. Trends in common surgical procedures at children's and nonchildren's hospitals between 2000 and 2009. *J Pediatr Surg*. 2018;53(8):1472-1477.
- Blitman NM, Anwar M, Brady KB, Taragin BH, Freeman K. Value of Focused Appendicitis Ultrasound and Alvarado Score in Predicting Appendicitis in Children: Can We Reduce the Use of CT? *AJR Am J Roentgenol*. 2015;204(6):W707-12.
- Dilley A, Wesson D, Munden M, Hicks J, Brandt M, Minifee P, Nuchtern J. The impact of ultrasound examinations on the management of children with suspected appendicitis: a 3-year analysis. *J Pediatr Surg*. 2001;36(2):303-8.
- Kaiser S, Jorulf H, Söderman E, Frenckner B. Impact of radiologic imaging on the surgical decision-making process in suspected appendicitis in children. *Acad Radiol*. 2004;11(9):971-9.
- Bachur RG, Dayan PS, Bajaj L, Macias CG, Mittal MK, Stevenson MD, et al. The effect of abdominal pain duration on the accuracy of diagnostic imaging for pediatric appendicitis. *Ann Emerg Med*. 2012;60(5):582-590.e3.
- Erikci VS. Management of Pediatric Appendicitis. Current Issues in the Diagnostics and Treatment of Acute Appendicitis: IntechOpen; 2018.
- Alvarado A. Clinical Approach in the Diagnosis of Acute Appendicitis. Current Issues in the Diagnostics and Treatment of Acute Appendicitis: IntechOpen; 2018.
- Nielsen JW, Boomer L, Kurtovic K, Lee E, Kupzyk K, Mallory R, et al. Reducing computed tomography scans for appendicitis by introduction of a standardized and validated ultrasonography report template. *J Pediatr Surg*. 2015;50(1):144-8.
- Sauvain MO, Slankamenac K, Muller MK, Wildi S, Metzger U, Schmid W, et al. Delaying surgery to perform CT scans for suspected appendicitis decreases the rate of negative appendectomies without increasing the rate of perforation nor postoperative complications. *Langenbecks Arch Surg*. 2016;401(5):643-9.
- Boonstra PA, van Veen RN, Stockmann HB. Less negative appendectomies due to imaging in patients with suspected appendicitis. *Surg Endosc*. 2015;29(8):2365-70.
- Lahaye MJ, Lambregts DM, Mutsaers E, Essers BA, Breukink S, Cappendijk VC, et al. Mandatory imaging cuts costs and reduces the rate of unnecessary surgeries in the diagnostic work-up of patients

## Archives of SID

- suspected of having appendicitis. *Eur Radiol.* 2015;**25**(5):1464-70.
18. Marzouni HZ, Davachi B, Rezazadeh M, Milani MS, Matinfard S. Diagnostic Value of Hepatic Vein Ultrasound in Early Detection of Liver Cirrhosis. *Galen Medical Journal.* 2018;**7**:1140.
  19. Abu-Yousef MM, Bleicher JJ, Maher JW, Urdaneta LF, Franken Jr E, Metcalf A. High-resolution sonography of acute appendicitis. *American Journal of Roentgenology.* 1987;**149**(1):53-8.
  20. Gracey D, McClure MJ. The impact of ultrasound in suspected acute appendicitis. *Clin Radiol.* 2007;**62**(6):573-8.
  21. Blank W, Braun B. Sonography in the diagnosis of appendicitis--a prospective study. *Z Gastroenterol.* 1988;**26**(11):708-14.
  22. Chen SC, Wang HP, Hsu HY, Huang PM, Lin FY. Accuracy of ED sonography in the diagnosis of acute appendicitis. *Am J Emerg Med.* 2000;**18**(4):449-52.
  23. Lessin MS, Chan M, Catalozzi M, Gilchrist MF, Richards C, Manera L, et al. Selective use of ultrasonography for acute appendicitis in children. *Am J Surg.* 1999;**177**(3):193-6.
  24. Ramachandran P, Sivit CJ, Newman KD, Schwartz MZ. Ultrasonography as an adjunct in the diagnosis of acute appendicitis: a 4-year experience. *J Pediatr Surg.* 1996;**31**(1):164-7; discussion 167-9.
  25. Chan I, Bicknell SG, Graham M. Utility and diagnostic accuracy of sonography in detecting appendicitis in a community hospital. *AJR Am J Roentgenol.* 2005;**184**(6):1809-12.
  26. Scammell S, Lansdale N, Sprigg A, Campbell D, Marven S. Ultrasonography aids decision-making in children with abdominal pain. *Ann R Coll Surg Engl.* 2011;**93**(5):405-9.
  27. Marusch F, Allecke K, Gastinger I. Value of ultrasound in diagnosis of appendicitis. Results of the East German Multicenter Study. East German Working Group "Outcome Assessment and Quality Assurance in Surgery" of the CAQ of the German Society of Surgery. *Zentralbl Chir.* 1998;**123** Suppl 4:29-31.
  28. Hahn HB, Hoepner FU, Kalle T, Macdonald EB, Prantl F, Spitzer IM, et al. Sonography of acute appendicitis in children: 7 years experience. *Pediatr Radiol.* 1998;**28**(3):147-51.
  29. Townsend CM, Beauchamp RD, Evers BM, Mattox KL. Sabiston textbook of surgery E-book: Elsevier Health Sciences; 2012.
  30. Rioux M. Sonographic detection of the normal and abnormal appendix. *AJR Am J Roentgenol.* 1992;**158**(4):773-8.
  31. Olsen J, Myren C, Haahr P. Randomized study of the value of laparoscopy before appendectomy. *British journal of surgery.* 1993;**80**(7):922-3.
  32. Yabunaka K, Katsuda T, Sanada S, Fukutomi T. Sonographic appearance of the normal appendix in adults. *J Ultrasound Med.* 2007;**26**(1):37-43; quiz 45-6.
  33. Heller MT, Hattoum A. Imaging of acute right lower quadrant abdominal pain: differential diagnoses beyond appendicitis. *Emerg Radiol.* 2012;**19**(1):61-73.
  34. Quillin SP, Siegel M. Appendicitis in children: color Doppler sonography. *Radiology.* 1992;**184**(3):745-7.

**Open Access License**

All articles published by Bulletin of Emergency And Trauma are fully open access: immediately freely available to read, download and share. Bulletin of Emergency And Trauma articles are published under a Creative Commons license (CC-BY-NC).