



Internal Jugular Vein Waveform; A New Insight to Detect Early Stage of Hemorrhagic Shock

Mohammad Reza Rouhezamin¹, Babak Shekarchi^{1*}, Ali Taheri Akerdi², Shahram Paydar²

¹Department of Radiology, School of Medicine, AJA University of Medical Sciences, Tehran, Iran

²Trauma Research Center, Rajaei (Emtiaz) Trauma Hospital, Shiraz University of Medical Sciences, Shiraz, Iran

*Corresponding author: Babak Shekarchi

Address: Department of Radiology, School of Medicine, AJA University of Medical Sciences, Tehran, Iran.

e-mail: shekarchi.babak@yahoo.com

Received: April 7, 2019

Revised: May 19, 2019

Accepted: June 19, 2019

ABSTRACT

Objective: To evaluate the accuracy of internal jugular vein waveform to detect early stage of hemorrhagic shock

Methods: Forty-three volunteers enrolled in our study between November and December 2018. After blood donation of 450cc, the blood donors in the case group underwent color Doppler sonography of internal Jugular Vein. Besides, the clinical and laboratory indicators of shock were evaluated. The same clinical, laboratory and sonographic data was also obtained from the volunteers in the control group, then Chi-square and Student *t*-test were applied to make comparison between mentioned groups.

Results: After excluding five volunteers, eighteen subjects were included in the blood donor group (mean of age: 35.81±8.05) and 20 healthy volunteers enrolled in the control group (mean of age: 34.95±6.86). The Jugular pulsatility index was significantly smaller in the case group (0.47±0.27 vs. 0.77±0.52). The jugular pulsatility index above 0.91 excluded blood loss (sensitivity=100%). The combination of clinical, laboratory and sonographic data were also represented as two other indices; Jugular Pulsatility-Shock index and Jugular Pulsatility-Shock-Base Deficit index (JPSBDI). These indices were also accurate enough to detect early blood loss ($p=0.011$ and <0.001 , respectively). JPSBDI below 0.38 was highly accurate to rule out blood loss. (Area under the curve: 0.868, sensitivity=95% and specificity=76.47%).

Conclusion: The internal Jugular vein waveform is accurate to detect early stages of shock. The combination of clinical, laboratory and sonographic data is more promising than each of them, separately.

Keywords: Internal jugular vein; Doppler; Waveform; Hemorrhagic shock.

Please cite this paper as:

Rouhezamin MR, Shekarchi B, Taheri Akerdi A, Paydar S. Internal Jugular Vein Waveform; A New Insight to Detect Early Stage of Hemorrhagic Shock. *Bull Emerg Trauma*. 2019;7(3):263-268. doi:

Introduction

Shock, a widespread circulatory dysfunction leading to the failure of tissue oxygenation, is a common concern in modern trauma management [1]. Hemorrhagic shock is the leading cause of mortality

and morbidity in trauma patients[2]. Several indicators have been introduced for the diagnosis of early stage shock and small volume loss. Vital signs, including pulse rate (PR) and systolic blood pressure (SBP), are not sensitive [3]. Shock index (SI), the ratio of PR to SBP, is more promising; however, it

Accuracy of SID

still lacks enough accuracy to detect early stage of shock [4]. Although some laboratory parameters such as venous blood gas components and lactate level are accurate predictors of shock, they are not available bed side. Besides, some of them are not accurate enough to predict small volume loss [5, 6].

Sonographic parameters are other means for the detection of blood loss. Several sonographic methods have been presented for the evaluation of trauma patients. The most common one is Focused Assessment with Sonography for Trauma (FAST) which has been introduced for emergency settings since the late 90s [7]. Although it has undeniable role in trauma management, FAST has limited accuracy to detect small blood loss [8]. Moreover, several articles are available in which hemodynamic status and intravascular volume are evaluated sonographically. These studies mostly rely on venous diameter and its variation during inspiration and expiration [5, 6, 9, 10]. The flow pattern of internal jugular vein (IJV) which is mainly determined by the amount of intravascular volume and cardiac output, the two parameters affected in volume loss, has not been evaluated, yet. The aim of our study is to evaluate the flow pattern of IJV in volunteers with small volume loss.

Materials and Methods

Study Population

The study protocol was approved by local ethics committee affiliated to Jahrom University of Medical Sciences (JUMS) (ID: IR.JUMS.REC.1397.111). After signing an informed written consent, forty-three participants were included in this prospective study during November and December 2018. Twenty-three healthy consecutive blood donors were enrolled in the case group. Blood donation was done in the blood bank unit affiliated to JUMS. Besides, twenty healthy volunteers who attended to Honari Medical Clinic, a referral center affiliated to JUMS, were added in the control group with the same inclusion and exclusion criteria. The volunteers younger than 18 and older than 50 in addition to those suffered from a known medical illness and the donors with abnormal physical exam were excluded.

Study Protocol

Every blood donor in the case group donated 450 cc blood. The donors were instructed to avoid oral fluid uptake in the resting period. Ten minutes after blood donation, SBP and PR were obtained from the volunteers. Shock index was also calculated (PR/SBP) for each donor. Afterward, the sonographic examinations were performed for all volunteers in supine position and were recorded by an experienced radiologist. The measurements were done using a linear high frequency probe (14 MHz) and a Toshiba Aplio 300 sonography device (Toshiba Medical Systems, Tokyo, Japan). At last, about 5 cc blood

was obtained from the opposite ante-cubital fossa and laboratory tests including base deficit (BD), pH and bicarbonate level were assessed. The same sonographic and clinical investigations were also done for volunteers in the control group with the same sequential pattern. After a resting period of ten minutes in a room with similar temperature, vital signs were obtained, the sonographic examination of IJV was performed by the same radiologist and about 5 cc blood was drawn from their left ante-cubital fossa.

Sonographic Evaluation

The sonographic examinations were done in a calm and warm room, in supine position with relatively extended neck and slight rotation of head to the left side. The Right IJV was found in the axial plan at the level of carotid bulb and the pulse wave was evaluated in the longitudinal scan plane. The sample volume was kept about 1/3 of IJV diameter and centered in longitudinal axis. The angle of insonation was 60 degree or less, parallel to the long axis of IJV. All participants were instructed to breathe in a steady and calm manner and to avoid deep inspiration or expiration. After five consecutive similar cycles, the maximum (Vmax) and minimum (Vmin) velocities were defined. The Vmax-Vmin difference and the Vmax/Vmin ratio were calculated. The Jugular pulsatility index (JPI) was assumed as (Vmax-Vmin)/Vmax. Two other indices were also represented as below: 1. Jugular Pulsatility-Shock Index (JPSI: JPI/Shock Index) 2. Jugular Pulsatility-Shock -Base Deficit index (JPSBDI: JPSI/BE)

Statistical Analysis

The data were analyzed using MedCal 13 (MedCal software bvba) and Statistical Package for the Social Sciences program version 23.0 (SPSS Inc., Chicago, IL, U.S.A.). Chi-square test was applied to compare categorical variables while Student *t*-test was used to compare the means of parameters with normal distribution. The data were reported as mean±standard deviation and p-value less than 0.05 was considered meaningful. Receiver operator characteristic (ROC) curves were plotted and areas under the curve (AUC) were compared. Finally, several cut of points were chosen and sensitivity, specificity, positive likelihood ratio (+RL) and negative likelihood ratio (-RL) were reported.

Results

Forty male and three female volunteers were included in our study. Four donors (three male and one female) were excluded from the case group because of hypertension, hyperthyroidism and vasovagal shock during blood donation. Another one also refused being sampled and sonographic examination after blood donation.

The demographic data as well as absolute volume

Archives of SID

of donated blood (DB), relative donated blood (DB/body weight) and body weight were similar statistically between two groups (Table 1). The means of clinical (PR, SBP, SI), laboratory (BD, HCO₃) and sonographic data were calculated for each group, compared and shown in Table 2. The combination of clinical, laboratory and sonographic data were also expressed as two combined indices, JPSI and JPSBDI. The Means were calculated and compared for these indices and shown in Table 3.

Afterward, ROC curves were plotted for each meaningful parameter and SI. The Areas under the Curve (AUC) were shown in table 4 and in Figure 1. At last, several cut of points of JPI, JPSI and JPSBDI were chosen and sensitivity, specificity, +LR and -LR were shown for each in Table 5.

Discussion

Hemorrhage is the main preventable cause of death in trauma patients. About forty percent of trauma related death and ninety percent of potentially preventable

mortality attributed to trauma are the direct consequences of blood loss [11]. The early diagnosis of volume loss plays a major role in avoiding harmful consequences related to under or over treatment [12]. In fact, a delay in the diagnosis of occult hemorrhage, even a small amount of blood loss, may cause dramatic results: threefold increase in post admission death in trauma patients[13]. On the other hand, Haut *et al.* [14], showed higher mortality in patients underwent aggressive prehospital fluid therapy.

The current methods are not reliable for the diagnosis of early blood loss. The determination of anatomic scores such as Injury Severity Score (ISS) is time consuming and not practical in early stage of trauma[15]. In the same way, clinical data and vital signs are not reliable indicators of early stage of shock [16-18]. Our study shows the same results: the minor increase of PR and decrease of SBP after small blood loss are not statistically meaningful and reliable enough for diagnosis of early blood loss. In fact, the compensatory mechanism secondary to catecholamine release increases the intravascular resistance to

Table 1. The demographic data and amount of donated blood in both groups

Characteristics	Case(n=18)	Control(n=20)	p value
Age (years)	35.81±8.05	34.95±6.86	0.514
Sex (M/F)	17/1	19/1	0.939
Weight (Kg)	91.67±12.26	88.73±18.02	0.576
Absolute Donated Blood (mL)	467.44±9.53	462±12.57	0.172
Relative Donated Blood	0.0052±0.00065	0.0054±0.00102	0.455

Table 2. Vital sign, clinical and sonographic parameters of patients in both groups

Parameters	Case (n=18)	Control (n=20)	p value
PR ^a	74.83±8.74	73.00±5.90	0.450
SBP ^b	120.44±11.28	121.65±11.03	0.741
SI ^c	0.62±0.10	0.60±0.05	0.339
BD ^d	3.52±1.43	4.92±1.05	0.002
HCO ₃	29.93±2.04	30.72±2.71	0.332
Vmax ^e	51.33±25.16	53.05±35.56	0.866
Vmin ^f	27.56±21.85	12.70±21.51	0.042
Vmax-Vmin	23.77±18.84	40.34±33.53	0.073
Vmax/Vmin	1.61±1.19	2.11±2.89	0.501
JPI ^g	0.4701±.27	0.7758±.52	0.034

^aPR: pulse rate; ^bSBP: systolic blood pressure; ^cSI: shock index; ^dBD: base deficit; ^eVmax: maximum velocity; ^fVmin: minimum velocity; ^gJPI: jugular pulsatility index

Table 3. Combined indices in both groups

Parameters	Case (n=18)	Control (n=20)	p value
JPSI ^a	1.69±0.80	1.08±0.57	0.011
JPSBDI ^b	0.53±0.28	0.22±.11	<0.001

^aJPSI: Jugular pulsatility-shock index; ^bJPSBDI: Jugular pulsatility- shock - base deficit index

Table 4. Area under the curve (AUC) for the different variables included in the current study

Parameter	SI ^a	BD ^b	JPI ^c	JPSI ^d	JPSBDI ^e	Vmin ^f
AUC	0.551	0.797	0.711	0.740	0.868	0.668

^aSI: shock index; ^bBD: base deficit; ^cJPI: jugular pulsatility index; ^dJPSI: Jugular pulsatility-shock index; ^eJPSBDI: Jugular pulsatility-shock-base deficit index; ^fVmin: Minimum velocity

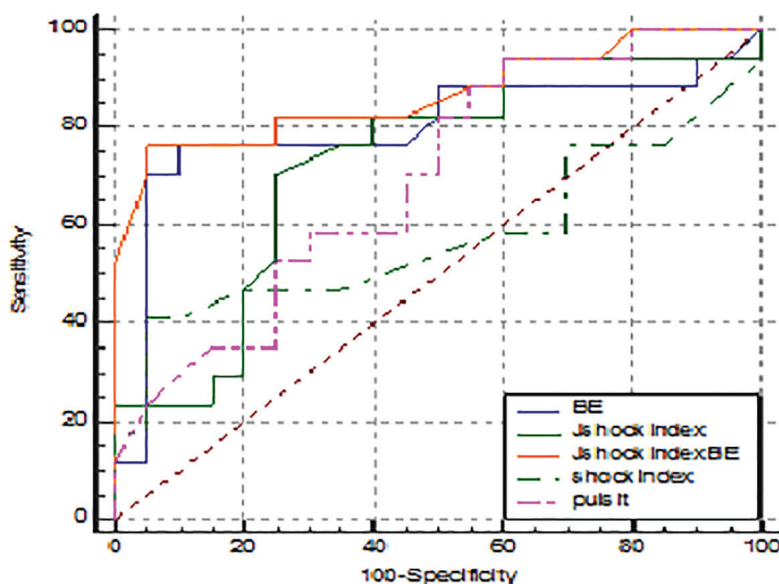


Fig. 1. The diagnostic accuracy of all the variable according to the receiver-operative characteristic (ROC) curve. BE: base deficit; Jshock index: Jugular pulsatility-stock index; JshockindexBE: Jugular pulsatility-shock-base deficit index; Pulsit: Jugular pulsatility index

Table 5. Accuracy of sonographic and combined indices

Threshold	Sensitivity	Specificity	+LR ^d	-LR ^e
JPI ^a				
0.91	100	20	1.25	0
0.71	94.44	40	1.57	0.14
0.61	88.89	45	1.62	0.25
0.48	61.11	70	2.04	0.56
0.24	22.22	95	4.44	0.82
JPSI ^b				
0.84	94.44	40	1.57	0.14
1.06	83.33	60	2.08	0.28
1.22	72.22	75	2.89	0.37
1.8	33.33	85	2.22	0.78
2.04	22.22	95	4.44	0.82
JPSBDI ^c				
0.1	94.12	25	1.25	0.24
0.21	88.24	45	1.6	0.26
0.3	82.35	75	3.29	0.24
0.38	76.47	95	15.29	0.25
0.42	52.97	100		0.47

^aJPI: Jugular pulsatility index; ^bJPSI: Jugular pulsatility-shock-index; ^cJPSBDI: Jugular pulsatility-shock-base deficit index; ^d+LR: positive likelihood ratio; ^e-LR: negative likelihood ratio

maintain blood pressure and tissue perfusion.

Increased base deficit, the indicator of lactic acidosis and anaerobic metabolism due to impaired tissue perfusion, is a predictor of early stage of shock in current study with acceptable accuracy (AUC: .797). Similarly, this laboratory test has been implied as an accurate index for classification of volume loss and shock in literature [19-21]. Although it is a reliable prognostic factor in trauma patients [19], it is affected by confounding factor such as hypocapnia, hyponatremia and acidosis [22].

Sonography is a potential alternative method for diagnosis of blood loss. The diameter of Inferior Vena Cava (IVC) [9], IVC collapsibility index [10],

IVC to aorta diameter ratio [5] and jugular index [6] are some indicators of volume loss evaluated previously. The data about these parameters are controversial [23, 24]. Although several studies are available about venous diameter in patients with volume loss, venous Doppler waveform has not been evaluated, yet. The Doppler flow patterns of Internal Jugular vein (IJV), the main draining vein of head and neck, was first described by Alain Pucheu [25]. The typical waveform was shown to be pulsatile, pantaphasic or triphasic with or without reflux; however, monophasic continuous waves with less pulsatility were also described.

Intravascular volume, cardiac output and

Archives of SID

Respiratory variation influence the venous dynamics and waveform [26-28]. In addition, blood loss affects all these factors. Intravascular volume loss is the inevitable consequence of hemorrhage. Cardiac output was declared to decrease after volume loss, even in the absence of clinical shock, in a study by Carter and his colleagues[26]. The respiratory variations in systemic veins was shown to be helpful in fluid therapy, too[29, 30]. Consequently, blood loss affects venous dynamics.

Our study depicts decreased pulsatility of IJV waveform after small blood loss. Hemorrhage and volume loss begins redistribution, a compensatory mechanism to maintain oxygenation of main organs such as brain, in spite of reduced cardiac output and venous return [31]. Consequently, the fraction of blood to brain increases; however, the absolute cerebral blood flow declines slightly [32] as well as cerebral venous flow [33]. At the same time, the absolute and relative flow to the peripheral extracranial circulation such as muscles of face depletes [1]. In other words, the absolute flow of IJV decreases after volume loss resulting in less maximum- minimum velocity difference and IJV pulsatility.

JPI has acceptable sensitivity and specificity to detect early stage of shock in our study. It is more accurate than vital signs and SI (AUC: .711 vs .551) and more easily accessible than laboratory tests. Nowadays, a sonographic device is readily available in most emergency rooms. Besides, it is an easy

method to learn and apply. The combinations of JPI, SI (JPSI) and BD (JPSBDI) are more accurate than each of them alone. JPSI is easily available and can be calculated in early approach to trauma patients. JPSBDI is highly accurate in cut of point about 0.38 (sensitivity: 76.47%, specificity: 95%). The JPSI and JPSBDI less than 0.3 and 0.09, respectively, rule out volume loss (sensitivity=100%). These indices can prevent over or under resuscitation in trauma patients with suspected volume loss.

Our study had limitations. Small sample size is the first one. However, this limitation did not affect the statistical analysis. Second, the participants in our study were healthy blood donors without coexisting clinical problems; however, it could be a preliminary study to introduce new noninvasive readily available indices which can be evaluated in real patients.

In conclusion, evaluation of IJV flow pattern provides useful data for the early diagnosis of small blood loss. JPI is a new sensitive and specific index to detect the early stage of shock which is easily available and can be calculated in an emergency room. Combination of clinical, laboratory and sonographic data results in more accurate indices (JPSI and JPSBDI). Moreover, further studies may reveal the role of IJV waveform and Doppler indices beyond the diagnosis of early stage of shock, to guide the amount and rate of fluid resuscitation in trauma patients.

Conflicts of Interest: None declared.

References

- Dutton RP. Low-pressure resuscitation from hemorrhagic shock. *Int Anesthesiol Clin.* 2002;**40**(3):19-30.
- Krug EG, Mercy JA, Dahlberg LL, Zwi AB. The world report on violence and health. *Lancet.* 2002;**360**(9339):1083-8.
- Pacagnella RC, Souza JP, Durocher J, Perel P, Blum J, Winikoff B, et al. A systematic review of the relationship between blood loss and clinical signs. *PLoS One.* 2013;**8**(3):e57594.
- Witting MD. Standing shock index: An alternative to orthostatic vital signs. *Am J Emerg Med.* 2017;**35**(4):637-639.
- Rahman NH, Ahmad R, Kareem MM, Mohammed MI. Ultrasonographic assessment of inferior vena cava/abdominal aorta diameter index: a new approach of assessing hypovolemic shock class 1. *Int J Emerg Med.* 2016;**9**(1):8.
- Akilli NB, Cander B, Dundar ZD, Koylu R. A new parameter for the diagnosis of hemorrhagic shock: jugular index. *J Crit Care.* 2012;**27**(5):530.e13-8.
- Scalea TM, Rodriguez A, Chiu WC, Brenneman FD, Fallon WF Jr, Kato K, et al. Focused Assessment with Sonography for Trauma (FAST): results from an international consensus conference. *J Trauma.* 1999;**46**(3):466-72.
- Yeo A, Wong CY, Soo KC. Focused abdominal sonography for trauma (FAST). *Ann Acad Med Singapore.* 1999;**28**(6):805-9.
- Kosiak W, Swieton D, Piskunowicz M. Sonographic inferior vena cava/aorta diameter index, a new approach to the body fluid status assessment in children and young adults in emergency ultrasound--preliminary study. *Am J Emerg Med.* 2008;**26**(3):320-5.
- Sefidbakht S, Assadsangabi R, Abbasi HR, Nabavizadeh A. Sonographic measurement of the inferior vena cava as a predictor of shock in trauma patients. *Emerg Radiol.* 2007;**14**(3):181-5.
- Eastridge BJ, Mabry RL, Seguin P, Cantrell J, Tops T, Uribe P, et al. Death on the battlefield (2001-2011): implications for the future of combat casualty care. *J Trauma Acute Care Surg.* 2012;**73**(6 Suppl 5):S431-7.
- Porter JM, Ivatury RR. In search of the optimal end points of resuscitation in trauma patients: a review. *J Trauma.* 1998;**44**(5):908-14.
- Gutierrez G, Reines HD, Wulf-Gutierrez ME. Clinical review: hemorrhagic shock. *Crit Care.* 2004;**8**(5):373-81.
- Haut ER, Kalish BT, Cotton BA, Efron DT, Haider AH, Stevens KA, et al. Prehospital intravenous fluid administration is associated with higher mortality in trauma patients: a National Trauma Data Bank analysis. *Ann Surg.* 2011;**253**(2):371-7.
- Baker SP, O'Neill B, Haddon W Jr, Long WB. The injury severity score: a method for describing patients with multiple injuries and evaluating emergency care. *J Trauma.* 1974;**14**(3):187-96.
- Little RA, Kirkman E, Driscoll P, Hanson J, Mackway-Jones K. Preventable deaths after injury: why are the traditional 'vital' signs poor indicators of blood loss? *J Accid Emerg Med.* 1995;**12**(1):1-14.
- Brasel KJ, Guse C, Gentilello LM, Nirula R. Heart rate: is it truly a vital sign? *J Trauma.* 2007;**62**(4):812-7.
- Victorino GP, Battistella FD, Wisner DH. Does tachycardia correlate with

Archives of SID

- hypotension after trauma? *J Am Coll Surg*. 2003;**196**(5):679-84.
19. Spahn DR, Cerny V, Coats TJ, Duranteau J, Fernández-Mondéjar E, Gordini G, et al. Management of bleeding following major trauma: a European guideline. *Crit Care*. 2007;**11**(1):R17.
 20. Sinert R, Zehtabchi S, Bloem C, Lucchesi M. Effect of normal saline infusion on the diagnostic utility of base deficit in identifying major injury in trauma patients. *Acad Emerg Med*. 2006;**13**(12):1269-74.
 21. Mutschler M, Nienaber U, Brockamp T, Wafaisade A, Fabian T, Paffrath T, et al. Renaissance of base deficit for the initial assessment of trauma patients: a base deficit-based classification for hypovolemic shock developed on data from 16,305 patients derived from the TraumaRegister DGU®. *Crit Care*. 2013;**17**(2):R42.
 22. Maar SP. Searching for the Holy Grail: a review of markers of tissue perfusion in pediatric critical care. *Pediatr Emerg Care*. 2008;**24**(12):883-7.
 23. Çelik ÖF, Akoğlu H, Çelik A, Asadov R, Onur ÖE, Denizbaşı A. Initial inferior vena cava and aorta diameter parameters measured by ultrasonography or computed tomography does not correlate with vital signs, hemorrhage or shock markers in trauma patients. *Ulus Travma Acil Cerrahi Derg*. 2018;**24**(4):351-35.
 24. Worapratya P, Anupat S, Suwannanon R, Wuthisuthimethawee P. Correlation of caval index, inferior vena cava diameter, and central venous pressure in shock patients in the emergency room. *Open Access Emerg Med*. 2014;**6**:57-62.
 25. Pucheu A, Evans J, Thomas D, Scheuble C, Pucheu M. Doppler ultrasonography of normal neck veins. *J Clin Ultrasound*. 1994;**22**(6):367-73.
 26. Lin S-K, Chang Y-J, Yang F-Y. Hemodynamics of the internal jugular vein: an ultrasonographic study. *Tzu Chi Medical Journal*. 2009;**21**(4):317-22.
 27. Kusaba T, Yamaguchi K, Oda H, Harada T. Echography of inferior vena cava for estimating fluid removed from patients undergoing hemodialysis. *Nihon Jinzo Gakkai Shi*. 1994;**36**(8):914-20.
 28. Grant E, Rendano F, Sevinc E, Gammelgaard J, Holm HH, Grønvall S. Normal inferior vena cava: caliber changes observed by dynamic ultrasound. *AJR Am J Roentgenol*. 1980;**135**(2):335-8.
 29. Feissel M, Michard F, Faller JP, Teboul JL. The respiratory variation in inferior vena cava diameter as a guide to fluid therapy. *Intensive Care Med*. 2004;**30**(9):1834-7.
 30. Barbier C, Loubières Y, Schmit C, Hayon J, Ricôme JL, Jardin F, et al. Respiratory changes in inferior vena cava diameter are helpful in predicting fluid responsiveness in ventilated septic patients. *Intensive Care Med*. 2004;**30**(9):1740-6.
 31. Carter EA, Tompkins RG, Yarmush ML, Walker WA, Burke JF. Redistribution of blood flow after thermal injury and hemorrhagic shock. *J Appl Physiol (1985)*. 1988;**65**(4):1782-8.
 32. Slater G, Vladeck BC, Bassin R, Brown RS, Shoemaker WC. Sequential changes in cerebral blood flow and distribution of flow within the brain during hemorrhagic shock. *Ann Surg*. 1975;**181**(1):1-4.
 33. Sun N, Li LZ, Luo W, Luo Q. Cerebral hemodynamic change and metabolic alteration in severe hemorrhagic shock. *Oxygen Transport to Tissue XXXVI*: Springer; 2014. p. 217-23.

Open Access License

All articles published by Bulletin of Emergency And Trauma are fully open access: immediately freely available to read, download and share. Bulletin of Emergency And Trauma articles are published under a Creative Commons license (CC-BY-NC).