

Orbital Cellulitis Due To Leech Therapy

Mazlum Kılıç¹, Rohat Ak^{2*}

¹Department of Emergency Medicine, Fatih Sultan Mehmet Education and Research Hospital, Istanbul, Turkey

²Department of Emergency Medicine, Kartal Dr. Lütfi Kırdar Education and Research Hospital, Istanbul, Turkey

*Corresponding author: Rohat Ak

Address: Kartal Dr. Lütfi Kırdar Education and Research Hospital, Department of Emergency Medicine, Istanbul, Turkey; Şemsi Denizer Cad. E-5 Karayolu Cevizli Mevkii 34890, Kartal/Istanbul. Tel: + 90 506 821 31 36
e-mail: rohatakmd@gmail.com

Received: January 13, 2019

Revised: April 2, 2019

Accepted: April 12, 2019

Please cite this paper as:

Kılıç M, Ak R. Orbital Cellulitis Due To Leech Therapy. *Bull Emerg Trauma*. 2019;7(3):335-336. doi:

A 59-year-old woman was admitted to the emergency department with complaints of redness and swelling in both eyes and face. She had a long history of headache, therefore applied leech treatment occasionally. Swelling began on the face after the treatment of leech therapy. Vital signs were as follows; fever: 36.5 °C, BP: 126/81 mmHg, heart rate: 84/min and sO₂: 98%; respiratory rate: 12/min. In physical examination, GCS was 15, conscious, oriented cooperative. There was no lymphadenopathy in the palpation of the head and neck examination. Oropharynx was in natural appearance and no uvula edema. Facial palpation

revealed redness, pain and heat rise (Figure 1A). Other systemic findings were normal. Laboratory tests showed leukocytes: 11,000/mm³ (4,000-10,000/mm³), hemoglobin: 12.8 g/dL (12,00-14,00 g/dL) platelet: 271,000 (100,000-400,000/mm³) CRP: 3.45 mg/L (0-0.5mg/L). Other parameters were within normal limits. Computed tomography (CT) showed bilateral periorbital, frontal subcutaneous soft tissue edema and lymphatic dilatations (Figure 1B). She was hospitalized with the diagnosis of orbital cellulite due to leech therapy.

It is known that leeches have been used in the treatment of some diseases since ancient times.

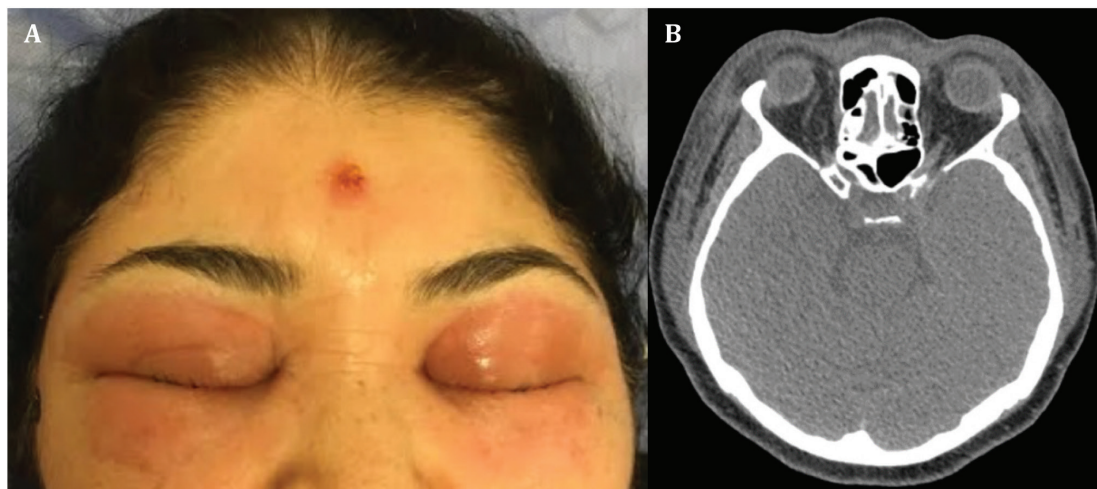


Fig. 1. Bilateral edema and redness of the eyes, as well as a wound due to leech therapy in the frontal midline are seen (A). Computed tomography (CT) showed bilateral periorbital, frontal subcutaneous soft tissue edema and lymphatic dilatations (B).

Archive of SID

This treatment is known as hirudotherapy. Today, leech therapy is used in many diseases such as degenerative joint diseases, lower extremity varicose vein diseases, lateral epicondylitis etc. with different levels of evidence [1, 2]. The widespread presence of leeches in the nature, easy access by patients and self-administration by patients without the supervision of health professionals raise the undesirable effects and

complications of this treatment. In order to prevent these undesirable effects, the treatment must be performed by a competent health professional after the appropriate clinical evaluation of a physician and the complications should be monitored.

Conflicts of Interest: None declared.

References

1. Iqbal A, Jan A, Quraishi HA, Sheeraz M, Shah A, Rather SA, et al. Leech therapy in medical science—a review. *Global J Res Med Plants Indigen Med.* 2018;7(6):75-85.
2. Robinson K, Postelnick M, Rhodes N, Qi C, Malczynski M, Widmaier V, et al. Implementing Infection Prevention for Leech Therapy. *Am J Infect Control.* 2019;47(6):S15.

Open Access License

All articles published by Bulletin of Emergency And Trauma are fully open access: immediately freely available to read, download and share. Bulletin of Emergency And Trauma articles are published under a Creative Commons license (CC-BY-NC).