

# Dichloromethane Injection: A Case Report

THUNYAPORN TANGTRONGCHITR<sup>1</sup>, NAT KRAIROJANANAN<sup>2</sup>, KITISAK SANPRASERT<sup>2,\*</sup>

<sup>1</sup>Ramathibordi Poison Center, Ramathibordi Hospital, Bangkok, Thailand

<sup>2</sup>Department of Trauma and Emergency Medicine, Phramongkutklo Hospital, Bangkok, Thailand

## Abstract

**Background:** Dichloromethane (a chlorinated hydrocarbon) is normally used as a solvent. Dichloromethane poisoning has been reported from occupational exposure and the common routes of dichloromethane poisoning are ingestion and inhalation.

**Case presentation:** We described a case of 51-year-old man who received subcutaneous injection of dichloromethane and presented with local wound necrosis at his forearm, but carboxyhemoglobin levels were normal.

**Discussion:** The corrosive property of dichloromethane result in venous thrombosis formation at his wound that might prevent systemic absorption of dichloromethane leads to reduced hepatic converted dichloromethane to the carbon monoxide.

**Conclusion:** Symptomatic treatment and monitoring of CO production remain the mainstay in the treatment of patients with subcutaneous injection of dichloromethane.

**Keywords:** Carbon Monoxide; Methylene Chloride; Subcutaneous Injection

**How to cite this article:** Tangtrongchitr T, Krairojananan N, Sanprasert K. Dichloromethane injection: a case report. *Asia Pac J Med Toxicol* 2018;7:84-5.

## INTRODUCTION

Dichloromethane (a chlorinated hydrocarbon) is normally used as a solvent. Dichloromethane poisoning has been reported from occupational exposure and the common routes of dichloromethane poisoning are ingestion and inhalation. Dichloromethane (CH<sub>2</sub>Cl<sub>2</sub>) or Methylene Chloride is a halogenated aliphatic hydrocarbon compound. It is a colorless and flammable liquid with a mild sweet odor.

Dichloromethane is used as raw material in many products such as household cleaner products, paint removers, and deodorants. The Liver is the primary site of dichloromethane metabolism when metabolized, producing Carbon monoxide (CO) via cytochrome P-450 2E1 and Glutathione-S Transferase (1).

## CASE PRESENTATION

A 51-year-old man without significant medical history presented with his local wounded forearm at the hospital. His is a craftsman and usually uses dichloromethane as a solvent for inlaying plastic frame. He had several pressures and stresses from his family and workplace, so he decided to harm himself by self-injected dichloromethane (2 mL) into

his forearm. At hospital, we found an erythematous lesion (10 cm) with severe pain at his left forearm (Figure 1). His vital signs showed he had hypertension (BP = 168/104 mm Hg, PR = 67/min, RR = 20/min, BT = 37 °C), and oxygen saturation by pulse oximeter was normal (99% on room air).

We did local debridement and found several venous thromboses occurring in his wound (Figure 2). After completion of debridement, his pain was significantly reduced.

We used pulse CO-oximeter (MASIMO Rad - 57 Pulse CO-Oximeter) for monitoring carboxyhemoglobin production and found carboxyhemoglobin levels shown in Table 1. Patient was discharged from the hospital without any clinical findings of CO poisoning during hospital admission.

## DISCUSSION

Dichloromethane (CH<sub>2</sub>Cl<sub>2</sub>) or Methylene Chloride is a halogenated aliphatic hydrocarbon compound. It is a colorless and flammable liquid with a mild sweet odor.

Dichloromethane is used as raw material in many products such as household cleaner products, paint removers, and deodorants. The Liver is the primary site of dichloromethane

**Table 1. Carboxyhemoglobin level**

Post dichloromethane injection (hr.)	2	6	10	48	72
Carboxyhemoglobin level	4.7%	5.5%	1.6%	4%	3%

\*Correspondence to: Dr. Kitisk Sanprasert; MD. Department of Trauma and Emergency Medicine, Phramongkutklo Hospital, Bangkok, Thailand

E-mail: Oligulia@gmail.com, Tel: 0816891290

Received 14 June 2018; Accepted 13 August 2018

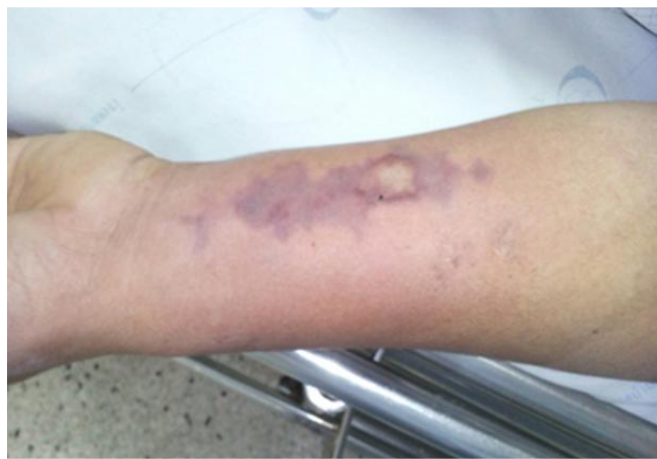

Figure 1. Local wound before debridement

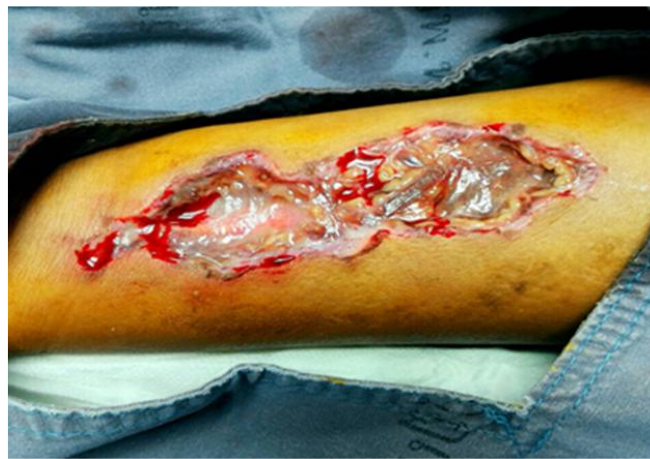

Figure 2. After debridement

metabolism when metabolized, producing Carbon monoxide (CO) via cytochrome P-450 2E1 and glutathione-S-transferase (1) (Figure 3). From an animal model, hepatic conversion of dichloromethane into CO was a saturable metabolic rate. (2)

The elimination half-life of dichloromethane is 13 hr at room air (3) and it decreased by oxygen administration. During exposure to dichloromethane, carboxyhemoglobin (COHb) derived from liver metabolism might be responsible for the clinical manifestations of dichloromethane poisoning. The earliest symptoms of CO poisoning are often non-specific. Central nervous system bore the predominant symptoms of CO poisoning. Delayed neuropsychiatric symptoms such as amnesia, psychosis, cognitive impairment, seizure, and coma have been described in CO poisoning patients. (4) The pathophysiology of this delayed symptoms remains controversial. Hypoxia alone is insufficient to explain this symptom.

The dichloromethane poisoning treatment includes removal from exposure, supplemental of oxygen, supportive treatment and CO production monitoring. Dichloromethane poisoning can cause many manifestations, including acute kidney injury (5), hepatotoxicity (6) and CO poisoning. In this case, we monitored COHb level for 5 days and did not find the rising of COHb level. Venous thrombosis formation in his wound might play a role to prevent systemic absorption of dichloromethane.

### CONCLUSION

The corrosive property of dichloromethane result in venous thrombosis formation at his wound that might prevent systemic absorption of dichloromethane leads to reduced hepatic converted dichloromethane to the carbon monoxide. Symptomatic treatment and monitoring of CO production remain the mainstay in the treatment of patients with subcutaneous injection of dichloromethane.

**Conflict of interest:** None to be declared.

**Funding and support:** None.

### REFERENCES

1. Bos PM, Zeilmaier MJ, van Eijkeren JC. Application of physiologically based pharmacokinetic modeling in setting acute exposure guideline levels for methylene chloride. *Toxicol Sci* 2006;91:576-85.
2. Angelo MJ, Bischoff KB, Pritchard AB, Presser MA. A physiological model for the pharmacokinetics of methylene chloride in B6C3F1 mice following i.v. administrations. *J Pharmacokinetic Biopharm.* 1984;12:413-36.
3. Ratney RS, Wegman DH, Elkins HB. In vivo conversion of methylene chloride to carbon monoxide. *Arch Environ Health* 1974;28:223-6
4. Lam SP, Fong SY, Kwok A, Wong T, Wing YK. Delayed neuropsychiatric impairment after carbon monoxide poisoning from burning charcoal. *Hong Kong Med J* 2004 ;10:428-31.
5. Horovitz MI, Zecler E. Acute renal failure with hepatic involvement after methylene chloride inhalation. *Harefuah.* 1995 ;128:91-2, 127.
6. Mizutani K1, Shinomiya K, Shinomiya T. Hepatotoxicity of dichloromethane. *Forensic Sci Int* 1988;38:113-28.

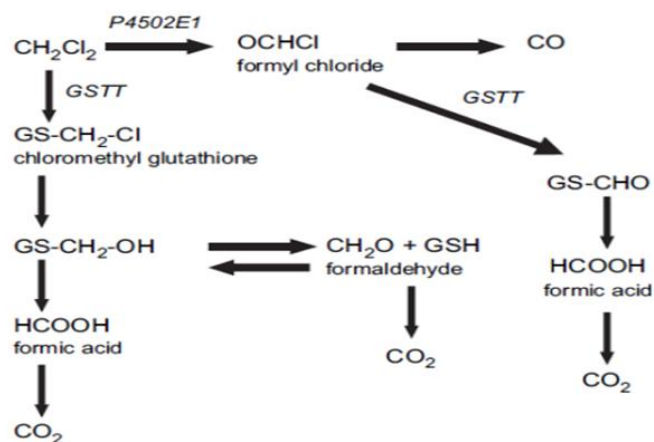


Figure 3. Biotransformation scheme of methylene chloride