

CASE REPORT

Sinus Bradyarrhythmia in Accidental Kodo Millet (*Paspalum scrobiculatum*) Poisoning – A Case Report

SURENDAR RAVIPRAGASAM^{1*}, AJAY RANGASWAMY¹, MANU AYYAN¹, BALAMURUGAN N¹, VIVEKANADAN PILLAI¹

¹Department of Emergency Medicine, Jawaharlal Institute of Postgraduate Medical Education & Research, Puducherry, India.

Abstract

Introduction: The Kodo Millet crop is known by different names in different regions such as *Varagu*, *Harka* and *Arikelu*. It is predominantly grown in India and commonly consumed. When infected by certain fungus species, the compound cyclopiazonic acid causes the crop to be toxic to humans.

Case Report: The following article discusses a case of Kodo Millet poisoning, which is presented with episodes of vomiting, sweating, giddiness and dysphagia. Upon examination, Sinus bradycardia and hypotension were the major findings. The electrocardiograph (ECG) showed sinus brady arrhythmia, which is rarely presented in Kodo Millet poisoning. The emergency physician team treated the patient symptomatically and he was discharged after 24 hours as the symptoms and the ECG findings were reverted.

Discussion: Kodo Millet poisoning often occurs due to accidental consumption of infected crops. Its occurrence is rare and the treatment involves only supportive care and monitoring. However, it is important to rule it out as a possible differential diagnosis in similar cases due to other causes.

Conclusion: Sinus bradyarrhythmia is a rare condition associated with Kodo Millet poisoning. Emergency physicians should be aware of this toxicity to rule out all other possible differential diagnoses and to provide patients with early treatment.

Keywords: Kodo Millet, Varagu poisoning, India

How to cite this article: Ravipragsam S, Rangaswamy A, Ayyan M, Balamurugan N, Pillali V. Sinus Bradyarrhythmia in Accidental Kodo Millet (*Paspalum scrobiculatum*) Poisoning – A Case Report. *Asia Pac J Med Toxicol* 2021; 10(2):65-68.

INTRODUCTION

The Kodo Millet (*Paspalum scrobiculatum*) is predominantly grown in the Deccan region (Gujarat, Karnataka and parts of Tamil Nadu) and is rich in dietary fibers, iron and other minerals. It is known by various names in different local regions such as *Varagu* in Tamil, *Harka* in Kannada, *Arikelu*, *Arika* in Telugu, cow grass, rice grass, ditch Millet or Indian Crown Grass (1). Despite its widespread production and consumption in India, it can be poisonous to cattle and humans. The poisonous nature of the Millet is due to 'cyclopiazonic acid' (CPA), a toxic substance produced by the fungus *Aspergillus flavus*, *Aspergillus tamaris* and *Phomopsis paspalli* (2). Poisoning due to chemical compounds present in food are an important but poorly recognized health problem, especially in developing countries (3). The poisoning caused by Kodo Millet is referred as 'Kodua poisoning'. Although Kodua Poisoning is reported frequently, there is limited published research and case reports on the subject. In this article, we discuss the rare and interesting case of sinus bradyarrhythmia caused by the accidental consumption of Kodo Millet, presented to our Emergency Department (ED) in our tertiary care institute.

CASE REPORT

A 48-yearold female presented to our ED with complaints of multiple episodes of vomiting followed by giddiness associated with disorientation and altered response for the last hour. The patient also complained of excessive sweating, tremors, giddiness and dysphagia for the past one hour. The patient mentioned a history of consumption of soaked Varagu (Kodo Millet in Tamil) (Figure 1) for dinner. The patient had no other related or significant previous history of medical illness or any surgical interventions. The patient initially went to a nearby primary health Centre, where her stomach was washed with riles tube and she was given a dose of atropine for bradyarrhythmia and referred to our tertiary care center for further management.

The patient was evaluated upon arrival to the ED and triaged as a level two, according to the ESI triaging system. The primary survey recordings were as follows: the airway was patent; breathing was normal (vesicular breathing) with no wheeze or crept; SpO₂ was 98%; Respiratory rate was 18/min; on auscultation S1, S2 was present with no added sounds; per abdomen was soft with mild epigastric tenderness and bowel sounds were present; Pulse rate was 50/min;

*Correspondence to: Dr Surendar Ravipragsam, M.D., Emergency medicine, No 21, Mohan Nagar, Puducherry – 605006
Email: drsurendar18@gmail.com, Tel: +91 99446 36634



Figure 1. Kodo Millet crop consumed by the patient

Sinus bradycardia; Blood pressure was 90/60mmHg measured from the right upper limb in supine position; Glasgow Coma Scale – E4V5M5 (14/15); pupils normal and were reacting to light; no lateralizing signs; power and tone normal in all limbs. The primary adjunct point of care ultrasound showed ‘A’ profile with lung sliding in the Lung ultrasound, Inferior vena cava distensibility index 50% collapsible, 2D ECHO suggestive of normal left ventricular function, and serum calcium levels were 9 mg/dl.

Investigations done: Blood investigation Trop I was found negative, Blood Urea, creatinine, sodium, potassium chloride, and liver enzymes were within normal limits. The chest radiograph showed normal imaging. The 12 lead Electrocardiograph

(ECG) was done which showed sinus bradycardia with 54/min, low voltage complex in limb leads, flattening of T waves in II, III, avF, avL, and ST depression with biphasic t-waves in V3 to V6. Also, there was mild prolongation of QTC complex in all leads (Figure 2-3). Chemical examination of the infected food could not be analyzed because the patient received a stomach wash before arrival to our tertiary care center.

Management:

The patient presented predominantly with multiple episodes of vomiting and altered sensorium. The major examination findings were hypotension and bradyarrhythmia. Initially, the patient was managed with 500 mL of 0.9% normal saline and Atropine (0.5mg) was administered to manage bradycardia according to the 2020 bradycardia management guidelines of American Heart Association. Only after further probing, the patient gave history of consumption of *Varagu* (Kodo Millet in Tamil) for dinner. Later, stomach wash with ryle’s tube followed by Piritone injection (4mg IV stat), Hydrocortisone injection (100mg IV stat), Pantoprazole injection (40mg IV stat) and an Emset injection (4mg IV stat) considering as anaphylactic shock, after ruling out other possible causes of sinus bradyarrhythmia and hypotension. A second dose of atropine (0.5mg) was given five minutes after the initial dose. The blood pressure and the pulse rate improved after four hours, which were 110/70mmHg and 82/min respectively. The patient was kept for observation in ED for 24 hours and maintained on iv fluids 0.9% normal saline. After the 24 hours observation period, the patients’ symptoms had improved and she was discharged.

Pathophysiology of Kodo Millet poisoning:

The toxic nature of Kodo Millet is due to contamination of

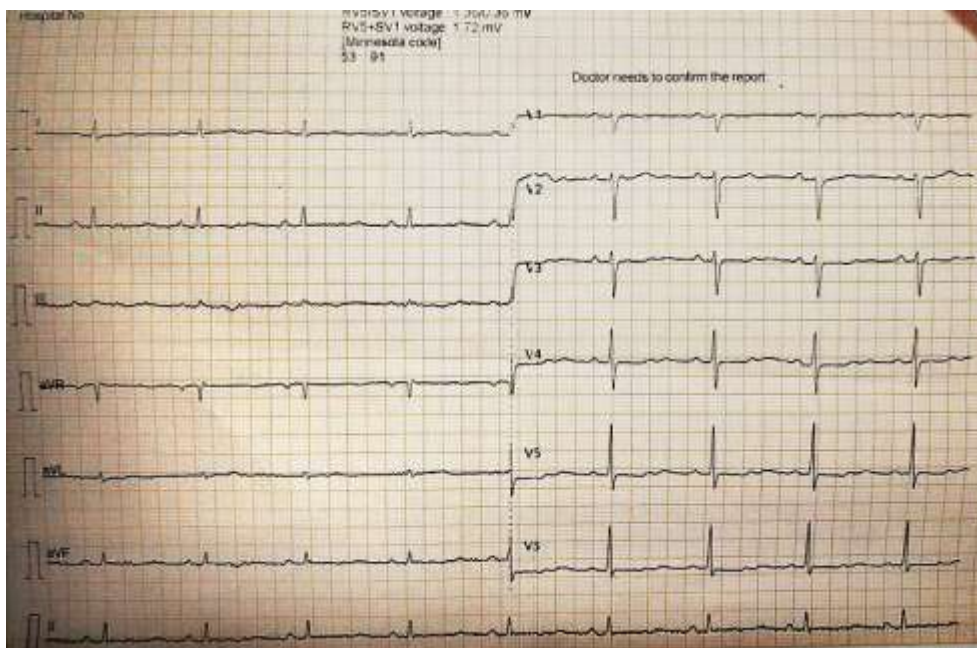


Figure 2. Electrocardiograph finding of the patient

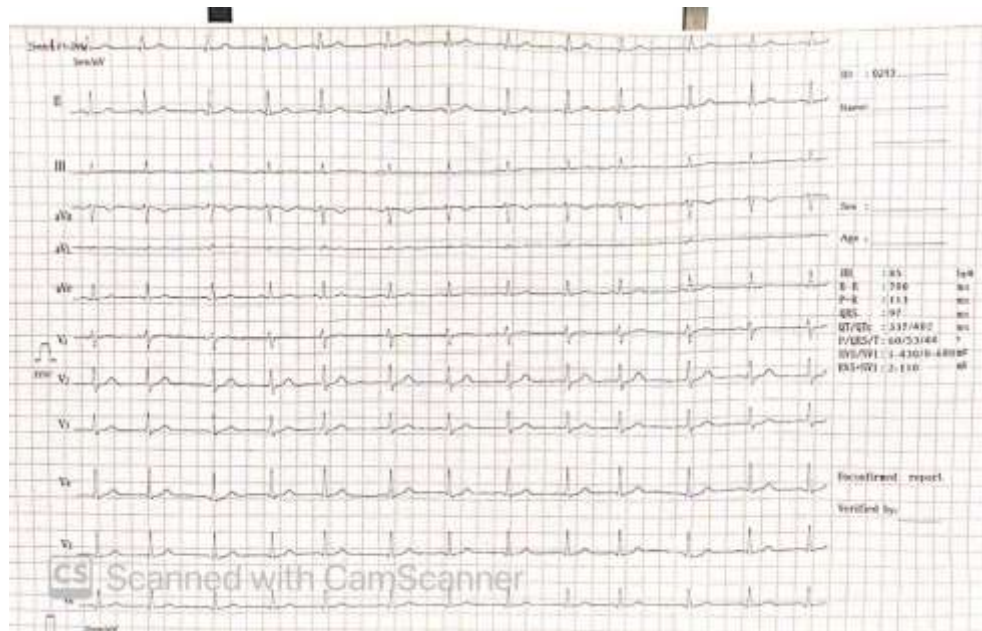


Figure 3. ECG of the same patient after administration of atropine

the crop by the fungus *Aspergillus flavus*, *Aspergillus tamaris* and *Phomopsis paspalli* that produces a mycotoxin, cyclopiazonic acid (CPA). Anorexia, ataxia, vomiting, diarrhea, excessive sweating, dehydration were the common clinical findings associated with CPA ingestion. In extreme cases hepatotoxicity, extensor spasm at the time of death were noticed (4). Since it predominantly affects the nervous system it is often referred to as a neurotoxin. The toxicity is due to selective inhibitory effect on Ca^{2+} - dependent ATPase in both endoplasmic and sarcoplasmic reticulum, which in turn affects calcium influx into the cells (5). The cellular effects of CPA were also found to be due to inhibition of certain cytochrome-p450 related enzymes which were responsible for causing acute hepatotoxicity and focal hepatic necrosis (6). In this case study, the major finding was sinus bradyarrhythmia, which can be due to hypocalcemia caused by selective and reversible inhibition of Ca^{2+} -ATPase pump CPA (7). However, there is a lack of literature regarding sinus bradyarrhythmia as major finding. The bradyarrhythmia was reversed with only atropine and general management along with other symptoms, which may suggest that it could be due to CPA only. Death due to Kodo Millet poisoning is rare and no cases of death have been reported in literatures.

DISCUSSION

Kodo Millet poisoning, though mild and a rare phenomenon, often occurs due to accidental consumption of infected crops. The treatment mainly involves stomach wash, supportive care, monitoring and observation to avoid deterioration of the patient's health. To manage bradyarrhythmia, Inj Atropine can be used and in severe cases

Injection calcium gluconate can be administered, however it usually reverts with general management and close monitoring. When the underlying reason for the patient

condition is unclear toxidrome-based approach has to be employed where the treatment to the patient comes first before treating the poison.(8). Several research publications have implicated the presence of CPA in Kodo Millet and the effects of its consumption, but only few research publications exist on case reports and its management. Though the occurrence and severity of Kodo Millet poisoning is usually rare, it is important to rule out it as a possible differential diagnosis in similar case scenarios due to other causes.

LIMITATIONS

This is the only case of Kodo Millet poisoning ever reported in our ED. Furthermore, the presentation and findings of this case was quite atypical. Future research and case studies will be required to generalize our case findings.

CONCLUSION

It's important for ED physicians to be knowledgeable of Kodo Millet poisoning as several patients with different conditions may present a similar history and examination findings. Moreover, sinus bradyarrhythmia is a rare condition associated with Kodo Millet poisoning. Thus, it is important for Emergency Physicians to properly rule out all the possible differential diagnoses to correctly identify the underlying cause. Also, toxidrome-based approach has to be employed so that the patient can be stabilized before establishing the diagnosis.

ACKNOWLEDGEMENT

I acknowledge my co-workers, Staff nurses and the Emergency technicians who helped in managing and tracking the case records.

Conflicts of interest: None to be declared.

Funding and support: None

REFERENCES

1. Deshpande SS, Mohapatra D, Tripathi MK, Sadvatha RH. Kodo millet-nutritional value and utilization in Indian foods. *J Grain Process Storage*. 2015;2:16–23.
2. Patanwar P, Sharma KKN. Nutritional Status of Kurmi Adolescent Girls of Raipur City Chhattisgarh, India. *Int J Sci Res Pub*. 2013;3:1–6.
3. Gibb H, Devleeschauwer B, Bolger PM, Wu F, Ezendam J, Cliff J, et al. Asian Implications of Aflatoxin and Dioxin Foodborne Chemical Exposures Based on World Health Organization Estimates. *Asia Pac J Med Toxicol*. 2015 Dec 1;4(4):131–3.
4. Bullerman LB. MYCOTOXINS | Classifications. In: Caballero B, editor. *Encyclopedia of Food Sciences and Nutrition* (Second Edition) [Internet]. Oxford: Academic Press; 2003 [cited 2020 Dec 11]. p. 4080–9. Available from: <http://www.sciencedirect.com/science/article/pii/B012227055X00821X>
5. M K, A B, Cc H, E M, Hj L, A F. The effects of the *Penicillium* mycotoxins citrinin, cyclopiazonic acid, ochratoxin A, patulin, penicillic acid, and roquefortine C on in vitro proliferation of porcine lymphocytes [Internet]. *Mycopathologia*. 2004 [cited 2020 Dec 11]. Available from: <https://pubmed.ncbi.nlm.nih.gov/15702270/>
6. Antony M, Shukla Y, Janardhanan K. Potential risk of acute hepatotoxicity of kodo poisoning due to exposure to cyclopiazonic acid. *J Ethnopharmacol*. 2003 Sep 1;87:211–4.
7. Burdock GA, Flamm WG. Review Article: Safety Assessment of the Mycotoxin Cyclopiazonic Acid. *Int J Toxicol*. 2000 May 1;19(3):195–218.
8. Mégarbane B. Toxidrome-based Approach to Common Poisonings. *Asia Pac J Med Toxicol*. 2014 Mar 1;3(1):2–12.