

## CASE REPORT

# Vasculotoxic snake bite induced multi-organ dysfunction- A case report

VIKRAM REDDY G<sup>1</sup>, AKASH CHETAN GEET<sup>2</sup>, SAGAR DHUPAJI SONONE<sup>3</sup><sup>1</sup>Assistant professor, Department of Radiology, Seth GS medical college and KEM hospital, Mumbai.<sup>2</sup>Junior Resident, Department of Radiology, Seth GS medical college and KEM hospital, Mumbai.<sup>3</sup>Assistant professor, Department of Radiology, Seth GS medical college and KEM hospital, Mumbai.

## Abstract

**Background:** A WHO report included snake envenomation in the list of most important Neglected Tropical Diseases (NTD) and 95% of these cases were reported within developing countries. The reason behind this given importance is the high morbidity and mortality rates of snake envenomation as well as the challenges in availability and affordability of anti-snake venom [1]. Vasculotoxic snake bites has a myriad of manifestations ranging from local complications like necrosis and cellulitis to systemic complications such as coagulopathy, acute renal failure, acute respiratory failure, and hemolysis.

**Case Presentation:** We report a case of a young male patient who was bitten by a Russell viper snake and developed cellulitis and blackish discolorations of the local site. The patient developed altered sensorium and subsequent loss of consciousness with a CT scan of the brain showing intra-parenchymal and subarachnoid hemorrhage. The coagulation profile demonstrated disseminated intravascular coagulation. He was treated for the above complications with polyvalent anti-snake venom, fresh frozen plasma, and cryoprecipitate units. Three days later, the patient developed breathlessness and hemoptysis with a drop in haemoglobin level with bilateral parenchymal infiltrates and left lower lobe consolidation indicative of diffuse alveolar hemorrhage with acute respiratory distress syndrome. On the fifth day, the patient reduced urine output with raised serum and creatinine levels. The patient's clinical status rapidly worsened despite mechanical ventilatory and inotropic support and unfortunately succumbed to death on the 7th day of admission.

**Conclusion:** Although there are case reports of snake bite induced isolated organ involvement, little is known about multi-organ dysfunction due to snake envenomation. The widespread multi-systemic involvement of snake envenomation resulting in fatal intracranial hemorrhage, acute lung, and kidney injury in our patient has been illustrated in this case report.

**Keywords:** snake envenomation, disseminated intravascular coagulation, acute respiratory distress syndrome, acute renal failure, intracranial hemorrhage.

**How to cite this article:** G Vikram Reddy, Geet AC, Sonone SD. Vasculotoxic snake bite induced multi-organ dysfunction- A case report. *Asia Pac J Med Toxicol* 2021; 10(2):69-73.

## INTRODUCTION

Snake venoms are a cocktail of multiple toxic substances that induce a myriad of manifestations like petechiae, blisters, muscle necrosis, and organ dysfunction. Hence, patients can present with isolated or multi-systemic symptoms due to hemotoxic or cytotoxic mechanisms [2]. However, snakebite envenomation is an under-reported and under-recognised life-threatening entity that was added to WHO's list of neglected tropical diseases [1]. Russell viper envenomation results in venom-induced consumption coagulopathy showing serious local symptoms as well as potentially fatal systemic manifestations. These manifestations include local cellulitis, intracranial haemorrhage, disseminated intravascular coagulation, diffuse alveolar haemorrhage with acute respiratory distress

syndrome (ARDS), and acute renal dysfunction [3]. Since the pathological effects of envenoming may be complex and multifaceted, understanding the myriad of manifestations and imaging features is of utmost importance in close monitoring and managing complications to reduce morbidity and mortality. Multi-organ dysfunction as a form of haemorrhagic manifestation is rare, yet a fatal outcome of snake envenomation. Although most of the available studies in the literature have focused on isolated organ involvement, there are some studies indicating that a small portion of patients who survive the initial few hours suffer from local and systemic complications. We present a case of multi-organ dysfunction caused by a vasculotoxic snake bite, which included disseminated intravascular coagulation, intracranial hemorrhage, acute respiratory distress syndrome, and acute renal failure eventually leading to death despite timely and

\*Correspondence to: Dr. Vikram Reddy G, MD, Assistant professor, Department of Radiology, Seth GS medical college and KEM hospital, Mumbai. Room 35, Annex boys hostel, Opposite haffkine institute, Parel, Mumbai-400012.  
Tel: +91 9742185991, Email: vikky1992@gmail.com

adequate treatment. This case report brings to light the seriousness of systemic complications caused by vasculotoxic snake envenomation.

### CASE REPORT

A 40-year-old non-diabetic non-hypertensive male was admitted to the casualty of our hospital with a history of Russell viper snake bite over the right foot while working in a printing press. The patient did not have any comorbidities or coagulation abnormalities. He did not take any local treatment immediately after the bite and was presented to the emergency department within 30 minutes of the snake bite. After 1 hour of admission, he developed pain and swelling over the right foot which progressed to involve the whole of the right leg. The patient complained of blackening of the foot and continuous bleeding from the injury site. At the time of admission, the patient was awake and aware of time, location, and person. The next day, the patient experienced an episode of severe headache followed by altered sensorium and subsequent loss of consciousness. There was no history of convulsions, cranial nerve involvement symptoms like ptosis or lower bulbar symptoms. Past history and family history were non-contributory. The patient was poorly responsive to external stimuli with the Glasgow Coma Scale (GCS) of 6/15. Further neurological evaluation revealed bilateral upgoing plantar response. The patient had dilated pupils and also reacted sluggishly to light bilaterally with absent doll's eye reflex. There were no symptoms of excessive sweating or salivation.

Immediate computed tomography of the brain was ordered which showed acute intra-parenchymal haemorrhage within the left frontal and insular cortex with a midline shift of 7mm. There was an extension of haemorrhage into the left lateral ventricle. Linear hyper-densities were noted in the left frontal and bilateral parietal sulci suggestive of subarachnoid

haemorrhage (Figures 1). Chest radiograph on the same day revealed no significant abnormality (Figure 3). The patient was administered with 2 doses of polyvalent Anti Snake Venom (ASV) 10 units.

Bedside whole blood clotting test was prolonged. The coagulation profile showed raised, prothrombin time (PT) of >120 seconds (control 12 s), International normalized ratio (INR) of 10.59, and activated partial thromboplastin time (aPTT) of 120 seconds (control = 35 s). Fibrinogen levels were <75mg/dl. Fibrin degraded product and D-dimer were 6.1 µg/mL and 7microgramsFEU/ml respectively. The above laboratory findings were suggestive of disseminated intravascular coagulation. The patient received ten units of fresh frozen plasma (FFP) and ten units of cryoprecipitate over 4 days starting from the day of admission. At admission, the haemoglobin levels were 12.4g/dl which dropped to 8.1g% on the 3<sup>rd</sup> day. On admission, the baseline platelet count was 3, 50, 000/mm<sup>3</sup> which showed a decreasing trend with counts dropping to 100,000/mm<sup>3</sup> on the 3<sup>rd</sup> day to 80,000/mm<sup>3</sup> on the 4<sup>th</sup> day of admission.

On the third day of admission, the patient developed breathlessness with haemoptysis. Respiratory examination at this point revealed bilateral coarse crepitations and chest radiograph showed diffuse bilateral coalescent opacities involving lower lung fields (Figure 2). Chest CT showed bilateral asymmetrical dense ground-glass opacities with fine reticulations resulting in a crazy-paving appearance seen in the right middle lobe, lingula, posterior segment of right upper lobe, and all segments of left upper lobe with an anteroposterior density gradient. An area of consolidation with air bronchogram was seen involving posterior and medial basal segments of left lower lobe (Figures 3). The patient was put on inotropic and mechanical ventilatory support.

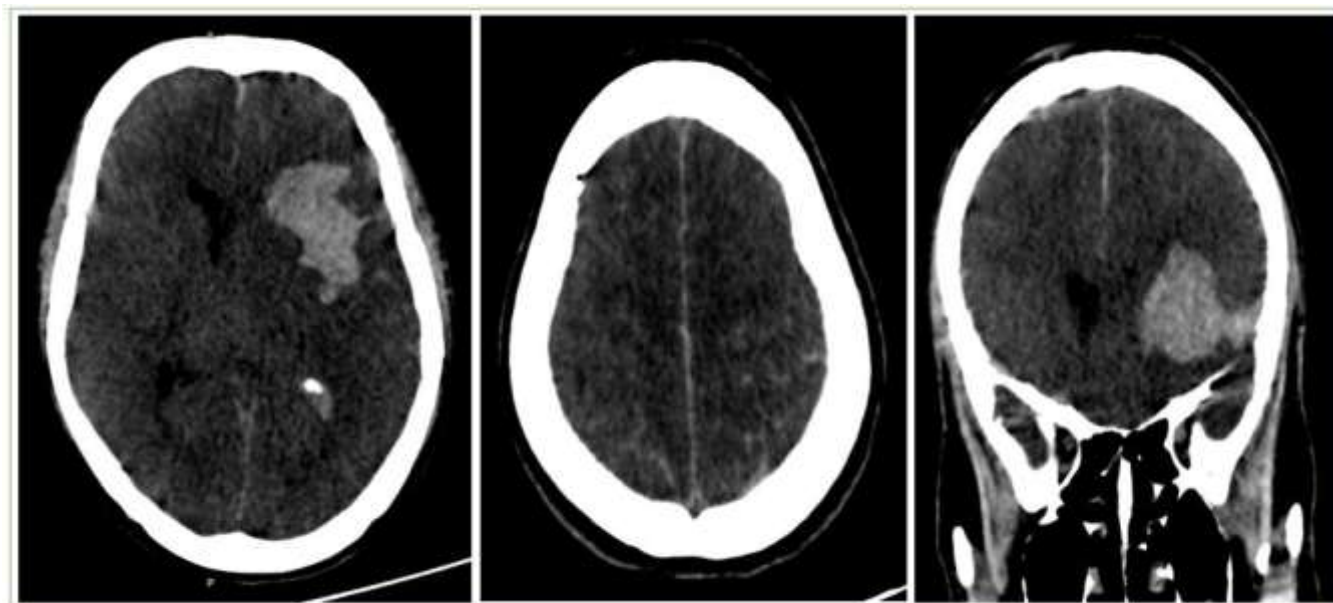


Figure 1. Unenhanced computed tomography of brain shows acute intraparenchymal hemorrhage in left frontal and insular cortex with surrounding edema and associated midline shift of 7mm.

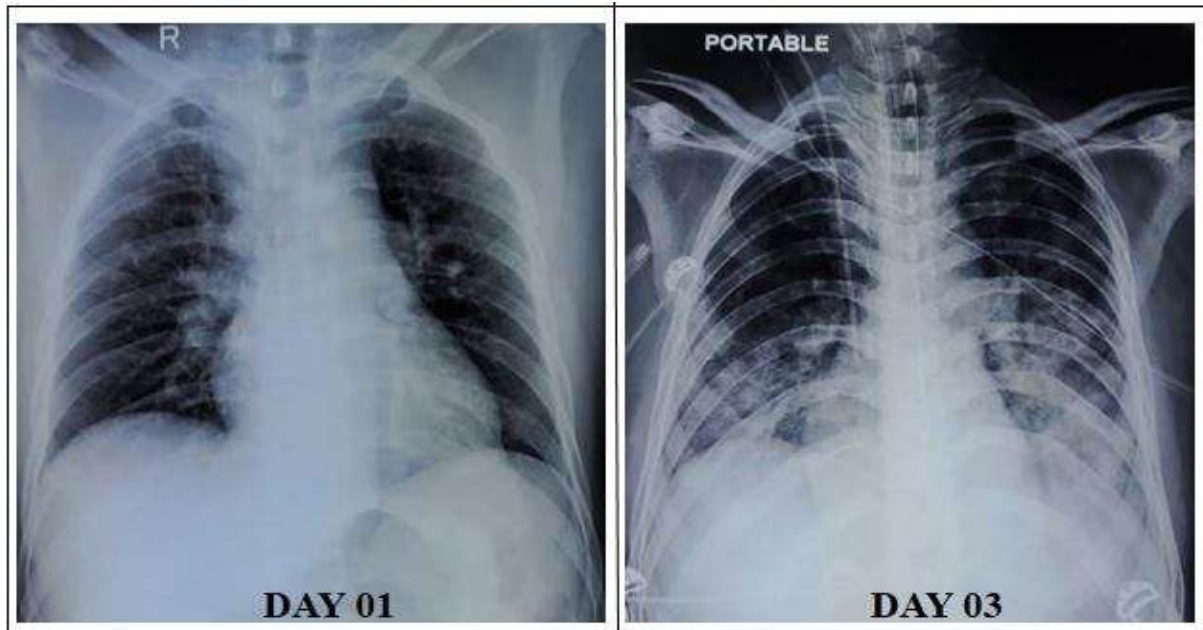


Figure 2. Chest radiograph on the day of admission shows both lung fields are clear. Chest radiograph on the 3th day of admission shows showed diffuse bilateral coalescent opacities involving lower lung fields.

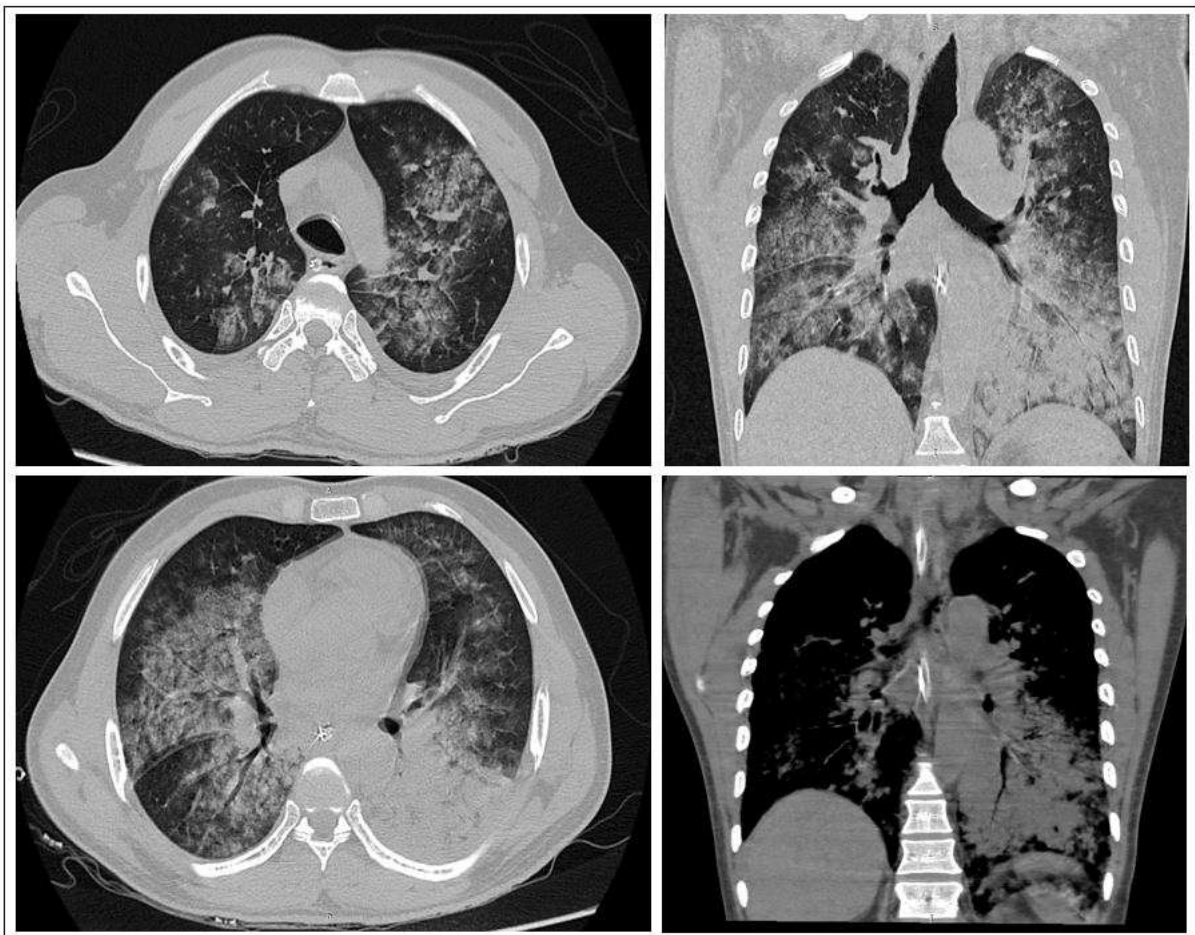


Figure 3. HRCT of chest shows bilateral asymmetric areas of multiple ground glass attenuation and smooth interlobular septal thickening (crazy paving appearance) with an anteroposterior density gradient. Airspace consolidation in left lower lobe.



The patient had normal serum creatinine for 4 days, but on the 5<sup>th</sup> day, the patient had low urine output with laboratory parameters indicative of hemolysis and deranged blood urea and creatinine levels. His serum creatinine levels increased to 2.1mg/dl on the 5<sup>th</sup> day and 3.6mg/dl on the 6<sup>th</sup> day. Haemodialysis was planned but could not be carried out because of the morbid condition of the patient. The patient's clinical status rapidly worsened despite mechanical ventilatory and inotropic support and passed away on the 7<sup>th</sup> day.

## DISCUSSION

Ophitoxaemia is a term used to describe the spectrum of clinical manifestations associated with snake bite. The systemic manifestations of venomous snakes are due to either their neurotoxic or hemotoxic enzymes [4]. Proteins form the major constituent (approx. 90%) of the toxic cocktail which includes numerous enzymes and polypeptide toxins having varied actions. Carbohydrates, lipid compounds, amino acids, serotonin, acetylcholine etc. constitute the rest of the toxin. Clinical severity is ultimately determined by the category of the snake, the nature, quantity and degree of toxicity of the snake venom administered, the location of the wound, timing of the first-aid and therapies provided, and the underlying medical comorbidities [5]. Renal dysfunction, intracranial haemorrhage or ischemia, and superadded infection are the usual causes of mortality due to snake envenomation [6].

Vasculotoxic snake bite is generally caused by two Viperoid species: Russell's viper and Saw-scaled viper [7, 8]. Phospholipase A2 is the factor responsible for the hematological complications and hyaluronidase causes disruption of mucopolysaccharides [3, 9]. Various components of snake venom have both anti-coagulant and hypercoagulable actions leading to both thrombotic and hemorrhagic complications [3]. The 50% lethal dose (LD50) of Russell viper snake is estimated to about 5-6 microgram [10].

The multitude of components present in snake venom can result in life-threatening and catastrophic complications of the nervous System ranging from intra-cerebral hemorrhage due to anti-coagulant properties of hemotoxic snakebites to ischemic infarcts resulting from DIC (disseminated intravascular coagulation). Snake envenomation induced ischemic strokes usually present after 2-3 days due to prothrombotic properties of venom [11]. Russell's viper snakes are commonly associated with cerebral ischemia rather than haemorrhage [12]. There are numerous mechanisms responsible for cerebral haemorrhage following snake bite, among which venom-induced consumptive coagulopathy (VICC) and hemorrhagin-induced direct endothelial injury are the most important causes [13]. The procoagulant toxins activate the coagulation pathway at various levels resulting in venom-induced consumptive coagulopathy. Sano-Martins et al [14] standardized the use of the whole blood clotting time for detecting VICC in snakebite patients. Deranged coagulation parameters in the form of an increase in PT, aPTT, and 20-minute whole blood clotting test signify the initiation of VICC. VICC also causes a marked increase in fibrinogen degradation products. The above-mentioned deranged coagulation profile in VICC was seen in

our patient with raised whole blood clotting time. In our case, the onset of intra-cranial haemorrhage was observed on the second day of admission.

The initiation of acute respiratory distress syndrome (ARDS) after being bitten by a snake is an unusual occurrence that has received insufficient attention in the medical literature. [15]. There are multiple factors associated with snakebite resulting in ARDS, major causes being DIC, secondary to aspiration or related to the venom. The toxins in venom lead to a dramatic rise in capillary permeability leading to capillary exudation and resultant ARDS. An indirect cause of ARDS is the deposition of venom related immune complexes in the capillaries of the lung. It may occur due to micro-thrombotic obstruction of the lung capillaries [15]. The diagnosis of ARDS is based on the parameters of the new Berlin 2012 definition of ARDS [16]. These criteria include the beginning of the respiratory symptoms for less than 7 days and the first of bilateral opacities on chest x-ray in the absence of heart disease, and fluid overload with normal left ventricular function. Acute kidney injury causes pulmonary edema in viper bites and the prevalence could be grossly underestimated provided that a large percentage of Russell's viper bites result in renal failure [15]. However, in our case, the onset of ARDS was prior to acute kidney injury postulating the possibility of immune complex deposition and DIC as the primary pathological process rather than fluid overload. Toxic snake bite results in non-cardiogenic ARDS with asymmetric findings in lung parenchyma with normalized heart. Similar findings were noted in our case. Sharma *et al* stated that the mortality rate of patients admitted to well-equipped hospitals with the availability of anti-snake venom, ventilatory support, and dialysis access was lower as compared to under-equipped hospitals in rural areas [17].

A small proportion of patients bitten by venomous snakes, primarily vipers, develop acute kidney injury (AKI). The acute renal dysfunction secondary to a snake bite is multifactorial, acute tubular necrosis due to persistent hypotension, acute diffuse interstitial nephritis, and extra capillary proliferative glomerulonephritis, myoglobinuria, and rhabdomyolysis due to DIC are some of the important causative factors. Renal vessel occlusion by micro-thrombi combined with glomerular damage by the immune complexes of venom could be the attributing factor for AKI along with hemoglobinuria and myoglobinuria which causes nephrotoxicity. Mortality in snake bite-induced AKI is 1-20% [18]. In a study conducted by Kalantari S et al., there was a 50% fatality rate among the 16 patients admitted with elevated serum creatinine levels due to envenomation induced acute kidney injury [19].

Warell et al stated that the onset of risk death after severe envenomation varies for various snakes: 8 hours after cobra bite, 18 hours after krait bites, 3 days after *D. russelii* bite, and 5 days after *Echis* bite. However, our patient succumbed to death after the 7<sup>th</sup> day of Russel viper bite despite intensive care [20].

In India, polyvalent ASV is the only available combination containing the antibodies against the venom of four common tropical species of India including Russell's viper (*Daboia russelii*), Common Cobra (*Naja naja*), Common Krait

*Archive of SID*

(*Bungarus caeruleus*), and Saw Scaled Viper (*Echis carinatus*) [21]. In developing countries like India, Snake envenomation is one of the most important and life-threatening emergencies which is often neglected. The measures to be taken to reduce morbidity and mortality are easy availability, affordability, and judicious use of anti-snake venom, institutional care, close monitoring of blood parameters and vitals.

**CONCLUSION**

Despite early and timely management with ASV and blood products, our patient developed significant multi-organ dysfunction due to snake envenomation. Although there are case reports of snake bite induced isolated organ involvement, the available literature on multi-organ dysfunction due to haemorrhagic manifestations of envenomation is very limited. Reporting the actual incidence of snake bite-related incidents and related deterministic factors like an increased bite to hospitalisation time, onset of coagulopathy and organ dysfunction is vital for the survival of the patient. Despite the limitation of a case report, our case highlights the significance and application of a structured analysis to work out the prognostic variables that may assist clinicians to predict outcomes more accurately and influence treatment choices like rational use of anti-snake venom.

**Conflict of Interest:** None to be declared.

**Funding and Support:** None.

**REFERENCES**

- Chippaux JP. Snakebite envenomation turns again into a neglected tropical disease!. *Journal of Venomous Animals and Toxins including Tropical Diseases*. 2017 Dec;23(1):1-2.
- Slagboom, Kool J, Harrison RA, Casewell NR. Haemotoxic snake venoms: their functional activity, impact on snakebite victims and pharmaceutical promise. *British journal of haematology* 2017 Jun;177(6):947-59.
- Menon, JC, Joseph KJ. Complications of Hemotoxic Snakebite in India. *Toxinology: Clinical Toxinology in Asia Pacific and Africa*. 2015 (pp. 209-232 Springer Reference, Dordrecht, Netherlands.
- Cook GC, Zumla A. History of tropical medicine, and medicine in the tropics. *Manson's Tropical Diseases*. 2008 Dec 16; 22: 1-8.
- Gold BS, Wingert WA. Snake venom poisoning in the United States: a review of therapeutic practice. *Southern medical journal* 1994 Jun 1;87(6):579-89.
- Jalal MJ, Thomas A, Varghese P. Intracerebral hemorrhage: a rare snake bite sequelae. *Indian Journal of Neurosurgery*. 2017 Mar; 6(01):027-30. doi:10.1055/s-0036-1581985
- Warrell DA. Venomous and poisonous animals. In: Cook GC, Zumla AI, editors. *Manson's tropical diseases*. Philadelphia:Saunders Elsevier; 2009. p. 557-99
- Gold BS, Dart RC, Barish RA. Bites of venomous snakes." *The New England journal of medicine* 2002 Aug 1;347(5):347-56. doi:10.1056/NEJMra013477
- Menon G, Kongwad LI, Nair RP, Gowda AN. Spontaneous intracerebral bleed post snake envenomation. *Journal of clinical and diagnostic research: JCDR*. 2017 Apr; 11(4):PD03. doi:10.7860/JCDR/2017/25095.9517
- Parveen G, Khan MF, Ali H, Ibrahim T, Shah, R. Determination of Lethal Dose (LD<sub>50</sub>) of Venom of four Different Poisonous Snakes found in Pakistan. *Biochem Mol Biol J*. 2017;3(3):18. doi: 10.21767/2471-8084.100046
- Bush SP, Mooy GG, Phan TH. Catastrophic acute ischemic stroke after Crotalidae polyvalent immune Fab (ovine)-treated rattlesnake envenomation. *Wilderness & Environmental Medicine*. 2014 Jun 1; 25(2):198-203.
- Al-Sadawi M, Mohamadpour M, Zhyvotovska A, Ahmad T, Schechter J, Soliman Y, et al. Cerebrovascular Accident and Snake Envenomation: A Scoping Study. *Int J Clin Res Trials*. 2019; 4: 133. doi: 10.15344/2456-8007/2019/133. Epub 2019 Apr 11. PMID: 31528777; PMCID: PMC6746409.
- Isbister GK. Snakebite doesn't cause disseminated intravascular coagulation: coagulopathy and thrombotic microangiopathy in snake envenoming. In *Seminars in thrombosis and hemostasis* 2010 Jun; 36: 444-451. © Thieme Medical Publishers.
- Sano-Martins IS, Fan HW, Castro SC, Tomy SC, França FO, Jorge MT et.al. Reliability of the simple 20 minute whole blood clotting test (WBCT20) as an indicator of low plasma fibrinogen concentration in patients envenomed by Bothrops snakes. *Butantan Institute Antivenom Study Group. Toxicon*. 1994; 32 (9):1045-1050. doi:10.1016/0041-0101(94)90388-3
- Udayabhaskaran, V, Thomas EA, Shaji B. Capillary Leak Syndrome Following Snakebite Envenomation. *Indian journal of critical care medicine: peer-reviewed, official publication of Indian Society of Critical Care Medicine* 2017 Oct;21(10):698 . doi:10.4103/ijccm.IJCCM\_41\_17
- Narayanan NK, Narayanan BA, Bosland M, Condon MS, Nargi D. Docosahexaenoic acid in combination with celecoxib modulates HSP70 and p53 proteins in prostate cancer cells. *International journal of cancer*. 2006 Oct 1;119(7):1586-98.
- Sharma, Sanjib Kumar, et al. "Snakebite-reappraisal of the situation in Eastern Nepal. *Toxicon* 2003Mar; 41(3): 285-289.
- Kanjanabuch T, Sitprija V. Snakebite nephrotoxicity in Asia. *InSeminars in nephrology* 2008 Jul; 28(4): 363-372.
- Kalantri S, Singh A, Joshi R, Malamba S, Ho C, Ezoua J, et al. Clinical predictors of in-hospital mortality in patients with snake bite: a retrospective study from a rural hospital in central India. *Tropical Medicine & International Health* 2006 Jan; 11(1): 22-30. doi:10.1111/j.1365-3156.2005.01535.x
- Warrell DA (2003) Injuries, envenoming, poisoning and allergic reactions caused by animals. In: *Oxford Text Book of Medicine*, 4th Edn (eds DA Warrell, TM Cox & JD Firth) Oxford University Press, Oxford, pp. 923–947.
- Ghosh S, Mukhopadhyay P, Chatterjee T. Management of snake bite in India. *J Assoc Physicians India*. 2016 Aug 1; 64:11-4.