

## Case Report

# Isolated Retrobulbar Hydatid Cyst: A Case Report

Shahnaz Sali<sup>1</sup>, Javad Minooeifar<sup>1\*</sup>, Azadeh La'li<sup>1</sup>, Zahra Doosti<sup>1</sup>, Masoud Ebrahimi<sup>1</sup>

<sup>1</sup> Infectious Disease and Tropical Medicine Research Center, Shahid Beheshti University of Medical Sciences, Tehran, Iran

Received: 30 May, 2017; Accepted: 20 October, 2017

## Abstract

**Background:** Hydatid cyst is caused by *Echinococcus granulosus* and human is the accidental host. The most common sites of involvement are the liver and lungs, and involvement of other organs is less common. Ocular involvement of hydatid cyst is one of the most uncommon manifestations of hydatid cyst.

**Cases Report:** The case was a 40-year-old woman with a retrobulbar cystic lesion who was examined for the left eye pain and then proptosis. With the initial diagnosis of retrobulbar tumor, the patient underwent surgery and the removed mass was sent to the pathology laboratory. Since the result indicated the existence of a hydatid cyst, the patient was referred to the infectious service and was treated with albendazole.

**Conclusion:** Although the ocular involvement of hydatid cyst is uncommon, it should be considered as a differential diagnosis in patients with proptosis in the endemic areas.

**Keywords:** *Echinococcus granulosus*; Orbit; Hydatid cyst

---

\*Corresponding Author: Javad Minooeifar, Infectious Diseases and Tropical Medicine Research Center, Velenjak St., Shahid Chamran Highway, Shahid Beheshti University of Medical Sciences, Tehran, Iran. Tel: (+98) 912 1193741. Fax: (+98) 21 22418180. Email: jminooefar@yahoo.com

Please cite this article as: Sali Sh, Minooeifar J, La'li A, Doosti Z, Ebrahimi M. Isolated Retrobulbar Hydatid Cyst: A Case Report. Novel Biomed. 2018;6(1):51-4.

## Introduction

Echinococcosis means human infection as the accidental host of *echinococcus* spp. that are carried by the family Canidae. This disease has two forms, including unilocular caused by *Echinococcus granulosus* and Alveolar caused by *Echinococcus multilocularis*<sup>1</sup>. Other names of Echinococcosis are hydatid disease or hydatidosis<sup>2-4</sup>.

Humans become infected by eating viable eggs of the parasite. In the intestine, oncosphere penetrates into the mucosa and enters the blood stream. Then the oncosphere changes into a cyst in the host visceral and eventually becomes a mature larval cyst. Infection with *E. granulosus* has been estimated to be 2-6% of the endemic population<sup>1</sup>.

Echinococcosis is the most common infection in

human worldwide<sup>2-4</sup>. Risk factors include slaughter, unsanitary living conditions, living in close proximity to livestock and dogs, and uncontrolled population of dogs<sup>1</sup>. Female gender, playing with dog and drinking ground water are other risk factors<sup>5</sup>.

Hydatid cyst involves the liver and lungs in 50-70% and 20-30% of cases, respectively<sup>1</sup>. In another study liver with 59.4% and lung with 28.2% are the most common infected site<sup>6</sup>. However, it may occur anywhere in the body including the brain, heart, and bone (in less than 10% of cases). They are often asymptomatic and incidentally found on radiographs in the majority of cases. They become symptomatic mainly due to mass effect resulting from enlargement of cysts<sup>1</sup>.

Infection is diagnosed based on radiography and then confirmed by ELISA or Western blot. Sensitivity and

specificity of serology for liver cysts are 80-100% and 88-96%, respectively. These figures for pulmonary cysts are equal to 50-56% and 25-56%<sup>1</sup>.

## Case Report

The patient was a 40-year-old housewife who visited a physician complaining of the left eye pain and received topical treatment. However, the patient's pain continued despite receiving treatment. The pain was localized at first and then gradually spread to the ear and the whole head which exacerbating by looking to the right. After 3 months, the patient's entourage noticed her eyes asymmetry as the left eye protrusion. At the same time, the patient also was complaining of blurred vision. In examinations, eye movements were natural but with edematous eyelids and proptosis in the left eye. The right eye had normal vision but the left one only could count fingers at a distance of 50 cm. Other vital signs were normal. A MRI in sagittal and axial view with and without contrast was prescribed for the patient and the results showed a cystic lesion in the left orbit (Figure 1-3). Accordingly, with the diagnosis of the orbital retrobulbar tumor with lateral orbitotomy, the patient underwent surgery and the removed mass was sent to the pathology laboratory. The patient was discharged from the hospital with a good general health but without improvement in the vision. Since the pathology results indicated the existence of a hydatid cyst, the patient was referred to the infectious service to be treated with albendazole. In the next visit and examinations, no evidence of recurrence was observed.

## Discussion

Hydatid cyst usually involves the liver and lungs and it rarely occurs in other body organs. According to a study conducted by Kayal and Hussain<sup>7</sup> on 25 patients with hydatid cyst from 2009 to 2011, the most common organs involved in this disease were the liver and then lungs, subcutaneous tissue, spleen, muscles, and parotid, respectively. The results of a study by Cappello, Cacopardo *et al.* (2013) on patients with hydatid cyst from 2000 to 2010 showed that the involvement of the liver is two times more than that of lungs<sup>8</sup>. In a study by Amr *et al.* (1994) on

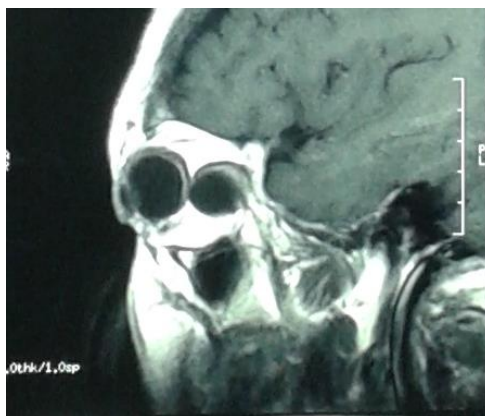


Figure 1. Sagittal view of Brain MRI.

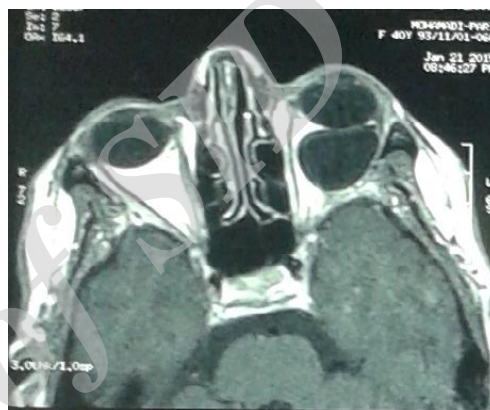

Figure 2. Axial view of Brain MRI.

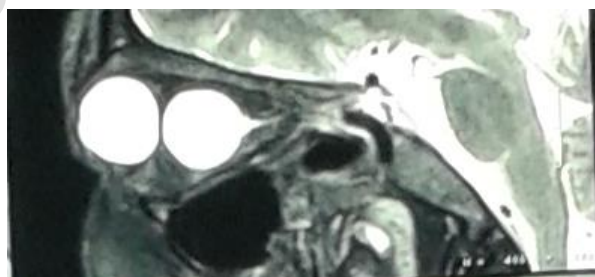


Figure 3. Sagittal view of Brain MRI with contrast.

306 patients, the involvement rate was 57% in the liver and 26% in lungs, and areas with lower involvement included kidney, spleen, soft tissue, appendix, and mesenteric<sup>4</sup>. In addition, multi-organ involvement has been reported among 7% of cases. According to a study by Rokni (2009), the common body organs involved in this disease in Iran was the liver and lungs and then other organs<sup>9</sup>. In a study conducted by Khojasteh *et al.* (2014) on patients hospitalized in Imam Khomeini, Shahid Modarres, and Dr. Shariati hospitals of Tehran from 2011 to 2012, it was found that the most common sites of involvement were the liver (76%), lungs, and CNS, respectively<sup>10</sup>. In

addition, no case of ocular involvement was reported by them. In a study conducted by Mardani *et al.* (2009) on operated patients with hydatid cyst in Qom from 2004 to 2007, the liver (74%) and lungs (26%) were the main sites of involvement, and no case of ocular involvement was reported<sup>11</sup>. According to studies mentioned above, it can be concluded that ocular involvement is one of the most uncommon side effects of hydatid cyst which has been reported in few studies and there is no certain figure available as its prevalence.

In cases that orbital hydatid cyst is reported isolated or with involvement in other organs, patients usually complain of different symptoms. According to a study conducted by Benazzou *et al.* (2010) who reviewed 10 cases of orbital hydatid cyst, the most common symptoms included gradually-progressive unilateral proptosis (100%) and vision loss (90%)<sup>12</sup>. Kaushic *et al.* reported a primary ocular hydatid cyst in an 80-year-old woman with nontender, nonpulsatile proptosis, and reduced vision<sup>13</sup>. MRI results showed the existence of a retrobulbar cyst, so the patient underwent surgery through lateral orbitotomy and pathology reports confirmed the initial diagnosis. In a study conducted by Thatte *et al.* (2016), the severity of symptoms was determined based on the parasite load as well as the site and size of the cyst<sup>14</sup>. Their findings showed that symptoms caused by pressure usually took a long time to manifest. Most symptomatic cysts were larger than 5 cm in diameter. Other symptoms included multiple-month proptosis with low periorbital pain, limited eye movements, impaired vision, and headache. In a study conducted by Anandpara *et al.* (2015), a patient with proptosis and vision loss in the left eye since 6 months ago was examined<sup>15</sup>. The result of examination indicated the existence of an intraconal cystic lesion. The patient was operated and the histopathology result reported a hydatid cyst. Therefore, the patient was prescribed to be treated with albendazole for 12 weeks. According to a study conducted by Al-Abboudi *et al.* (2015), most cases of orbital hydatid cyst occur in upper-outer and upper-inner angles<sup>16</sup>. In this study, a 42-year-old woman complaining of a gradually-aggravated headache, the right eye swelling, and impaired vision was introduced. Examinations showed proptosis, and her

visual acuity was as much as counting fingers at a distance of one meter. A cyst was reported in MRI result and, with an early diagnosis of hydatid cyst, the patient underwent surgery and then placed under treatment with albendazole for 2 months. Finally, the histopathology results confirmed the initial diagnosis. In a study conducted by Khalili *et al.* entitled “*Orbital hydatid cyst: a case report in Shahrekord*”, an 11-year-old boy with painless and nonpulsatile proptosis, blurred vision in the right eye, and asymmetric eyes was introduced<sup>17</sup>. According to the CT scan result, the patient underwent surgery with an early diagnosis of hydatid cyst. The pathology result confirmed the initial diagnosis. Before and after the surgery, the patient was treated with 15 mg/kg albendazole for two 4-week periods. In a study conducted by Rajabi *et al.* on 8 patients with slowly progressive proptosis during 2-4 months, hydatid cyst was reported as the first manifestation as follows: extraconal (2 cases), intraconal (1 case), one in the lacrimal gland, one in the medial rectus muscle, and one inside the orbital bone<sup>18</sup>.

## Conclusion

Given the very low incidence of ocular involvement in hydatid cyst, it seems that hydatid cyst is considered a differential diagnosis in endemic areas and in patients with proptosis. It is recommended that patients with hydatid cyst be treated with albendazole before any surgery in order to prevent any complication of cystic rupture.

## References

1. Mandell G, Bennett J, Dolin R. Mandell, Douglas, and Bennett's Principles and Practice of Infectious Diseases. 7th ed. Imprint: Churchill Livingstone; 2009.
2. Iyigun O, Uysal S, Sancak R, Hokelek M, Uyar Y, Bernay F, et al. Multiple Organ Involvement Hydatid Cysts in a 2-year-old boy. *J Tropical Pediatrics*. 2004;50(6):374–6.
3. Blanton R, Kliegman RM. Echinococcosis (*Echinococcus granulosus* and *E. multilocularis*) In: Behrman RE, Bede JH, (editors) *Nelson Textbook of Pediatrics*, Philadelphia. 16th ed. WB Saunders; 2008. p.1079–81.
4. Rokni, M.B. Echinococcosis /hydatidosis in Iran. *Iranian J Parasitol*. 2009;4(2):1-16.
5. Wang Q, Huang Y, Huang L, Yu W, He W, Zhong B, et al. Review of risk factors for human echinococcosis prevalence on the Qinghai-Tibet Plateau, China: a prospective for control options. *Infectious Diseases of Poverty*. 2014 29;3(1):3.

6. Khazaei S, Rezaeian Sh, Khazaei Z, Goodarzi E, Khazaei S, Mohammadian M, et al. Epidemiological and Clinical Characteristics of Patients with Hydatid Cysts in Khorasan Razavi Province, from 2011 to 2014. *Iran J Parasitol*. 2016;11(3):364–70.
7. Kayal, A, Hussain A, A Comprehensive Prospective Clinical Study of Hydatid Disease. *ISRN Gastroenterology*. 2014; ID 514757, 5.
8. Cappello E, Cacopardo B, Caltabiano E, Li Volsi S, Chiara R, Sapienza M, et al. Epidemiology and clinical features of cystic hydatidosis in Western Sicily: A ten-year review. *World J Gastroenterol*. 2013;19(48):9351–8.
9. Amr SS, Amr ZS, Jitawi S, Annab H. Hydatidosis in Jordan: an epidemiological study of 306 cases. *Ann Trop Med Parasitol*. 1994;88(6):623-7.
10. Hatami H., Khojasteh M., Khodakarim S. Epidemiological, clinical and paraclinical study on hydatid cyct infected patients operated in the hospitals of Imam khomeini, Shahid Modarres, and Shariati hospital 2011-2012. 2014;32(3):239-46.
- 11 Mardani A, Babakhan L, Abedi Astaneh F, Rafiei M, Mardani H. A Survey of Epidemiological Situation of Patients Infected with Hydatid Cyst Operated in Hospitals of Qom, Iran (2004-2007). *mljgoums*. 2009;3(2):6-10.
12. Benazzou S, Arkha Y, Derraz S, E Ouahabi A, El Khamlichi A. Orbital hydatid cyst: review of 10 cases. *J Craniomaxillofac Surg*. 2010;38(4):274-8.
13. Mathad V.U, Singh H, Singh D, Butte M. V, Kaushik M. Large primary intraorbital hydatid cyst in elderly. *Asian J Neurosurg*. 2013;8(3):163.
14. Thatte S, Thatte S. Ocular Hydatid Cyst. *Ann Clin Pathol*. 2016;4(5):1081.
15. Anandpara KM, Aswani Y, Hira P, Sathe PA. Isolated primary orbital hydatid disease presenting as multiple cystic lesions: a rare cause of proptosis. *Ann Parasitol*. 2015;61(3):193-5.
16. Al-Muala HD, Sami SM, Shukri MA, Hasson HK, Alaboudy AT. Orbital hydatid cyst. *Ann Maxillofac Surg*. 2012; 2(2):197-9.
17. Ahmadi M, Khalili B. A case report of orbital hydatid cyst in Shahrekord. *J Shahrekord Univ Med Sci*. 2015;16(6):148-53.
18. Rajabi MT, Bazvand F, Makateb A, Hosseini S, Tabatabaie SZ, Rajabi MB. Orbital hydatid cyst with diverse locality in the orbit and review of literatures. *Arch Iran Med*. 2014;17(3):207-10.