



## Hepatoprotective effect of *Acantholimon bracteatum* (Girard) Boiss. on formaldehyde-induced liver injury in adult male mice

E. Nasiri<sup>1</sup>, S. Naserirad<sup>2</sup>, A. Pasdaran Lashgari<sup>3,4\*</sup>, R. Gazor<sup>1</sup>, F. Mohammadghasemi<sup>5</sup>, Z. Atrkar Roushan<sup>6</sup>

<sup>1</sup>Department of Anatomical Sciences, Faculty of Medicine, Guilan University of Medical Sciences, Rasht, Iran.

<sup>2</sup>Student Research Center, Guilan University of Medical Sciences, Rasht, Iran.

<sup>3</sup>Department of Pharmacognosy, School of Pharmacy and Research and Development Center of Plants and Medicinal Chemistry, Guilan University of Medical Sciences, Rasht, Iran.

<sup>4</sup>Medicinal Plants Processing Research Center, Shiraz University of Medical Sciences, Shiraz, Iran.

<sup>5</sup>Department of Biochemistry, Faculty of Medicine, Guilan University of Medical Sciences, Rasht, Iran.

<sup>6</sup>Department of Social Medicine, Faculty of Medicine, Guilan University of Medical Sciences, Rasht, Iran.

### Abstract

**Background and objectives:** *Acantholimon bracteatum* (Girard) Boiss (Plumbaginaceae) is used in variety of diseases including hepatic ailments in the west regions of Iran. In the present study, the hepatoprotective effect of the methanol extract (ME) of *A. bracteatum* on formaldehyde (FA) induced liver injury has been investigated in adult male mice. **Methods:** Fifty six adult male mice were divided into 8 groups. The control group received normal saline. Group II (E2) was treated with formaldehyde 10 mg/kg. Group III to VIII (E3-E8) were treated with both FA (10 mg/kg) and the metanol extract at doses of 5, 10, 15, 20, 50 and 100 mg/kg, respectively. All animals were treated for 2 weeks (once every other day). At the end of the morphology, histopathology of liver and serum levels of alanine aminotransferase (ALT), aspartate aminotransferase (AST) and alkaline phosphatase (ALP) were evaluated. **Results:** Formaldehyde induced liver damage both in histology and function. The levels of ALT, AST and ALP enzymes had significantly increased in FA treated group. Administration of ME in all experimental groups significantly reduced serum levels of ALP ( $p=0.02$ ); however, AST was reduced significantly just in groups III (E3) and IV(E5) ( $p<0.002$ ) who were treating with doses of 5 and 15 mg/kg of *A. bracteatum*; similarly, ME at doses of 5 and 15 mg/kg protected liver histology against FA. **Conclusion:** The results showed that the ME of *A. bracteatum* has a protective effect on both histology and function of liver in low doses.

**Keywords:** *Acantholimon bracteatum* (Girard) Boiss., formaldehyde-induced liver injury, hepatoprotective effect, Plumbaginaceae

### Introduction

Physiological processes including metabolism and detoxification [1]. Based on these functions,

hepatic diseases and injuries remain one of the public health problems and one of the primary causes of morbidity and mortality in world [2]. It is well known that free radicals released from many environmental sources such as chemical industry can trigger liver cell damage. Recently, antioxidant agents have attracted researches about hepatoprotective potential of natural sources such as plants. Numerous plants are used for their protection and treatment of liver diseases in traditional medicine systems [3]. Detoxifications of toxicants lead to liver cellular stress and hepatoprotective medications could be recommended for this distractive condition. Thus, natural based hepatoprotective treatment is a need of the medical treatment systems. Using many edible plants such as nutmeg, turmeric, chicory and others as the hepatoprotective remedy has been popularized for a long time [4,5]. Clinical investigations have demonstrated efficacy and safety of a number of herbal products in the treatment of liver diseases [6]. In the present study we have considered formaldehyde (FA) as a hepatotoxic compound which is used for producing hepatotoxicity in animals; it is a common chemical that is used in many industries and can cause damage in many key cellular components [7,8]. Plumbaginaceae plants with medicinally important genera like *Limonium* and *Plumbago* have been used as traditional remedies for treatment of liver disease [9,10]. Among the members of this family, *Acantholimon* has the most diversity. Although this genus has shown massive distribution in the world, no research has been conducted on the bioactivity or chemical compounds of these plants. *A. bracteatum* (Girard) Boiss. (Plumbaginaceae) is a woody sub shrub, highly branched, spiny, 0.5-1.9 m high with purple flowers and needle leaves, widely distributed in many different climatic regions of Iran and it is known as 'prickly thrift' in Europe. Traditionally, it has been used to treat jaundice, diabetes and other hepatoprotective effects in the western regions of Iran. The present study has been focused on evaluating the potential

hepatoprotective effects of the methanol extract (ME) of *A. bracteatum* on formaldehyde (FA) induced liver injury in mice.

## Experimental

### *Plant material*

The aerial parts of *A. bracteatum* were collected from wild population growing in East Azarbaijan province, Iran, at their flowering stage in June 10, 2015. The voucher specimens were authenticated by the Department of Pharmacognosy (NO. 2559) and they were deposited at the Herbarium of Department of Pharmacognosy Faculty of Pharmacy, Guilan University of Medical sciences, Rasht, Iran.

### *Animals*

Fifty six adult male albino mice (20-25 g) were obtained from Razi Vaccine and Serum Research Institute. The animals were maintained on 12 h light and dark cycle, at 25±2 °C and 60%-70% humidity with standard pellets diet. Animal welfare and experimental procedures were strictly in accordance with the guide for the care and use of laboratory animals published by the US National Institutes of Health (NIH publication NO. 85-23, revised 1996) and the related guidelines on the ethical use and care of laboratory animals issued by the Faculty of Medicine, Guilan University of Medical Science, Rasht, Iran (1930349905).

### *Extraction*

*A. bracteatum* was dried in shade and pulverized in a dry grinder. The powdered material (300 g) was Soxhlet-extracted with 2.5 L of *n*-hexane, dichloromethane and methanol for a period of 72 h (24h for each solvent). The crude extract was filtered, concentrated at 40 °C using a rotary vacuum evaporator, and dried in an oven at 40 °C for 4-5 h (yield 35.5% on a dry-weight basis). The methanol extract (2g) was used for hepatoprotective effects in the experiment.

### *Experimental design*

Modified method of Gulec *et al.* has been used in

the present study [11]. The animals were divided into eight groups (seven mice in each group). Group I (E0) served as a normal control and received normal saline. Group II (E1) served as a toxicant control and received only 37% formaldehyde (10 mg/kg) for two weeks (3 days a week). Groups III-VIII (E2-E7) received equal 37% formaldehyde at a dose of 10 mg/kg body weight and after an hour, were treated with the methanol extract (ME) at doses of 5, 10, 15, 20, 50 and 100 mg/kg, respectively for 2 weeks (once every other day). All samples were administered intraperitoneally using insulin needles. The animals were anesthetized and then scarified by cervical dislocation on the 15<sup>th</sup> day. Blood samples were collected by cardiac and IVC puncture. Clear serum was separated by centrifugation (15000 rpm/15 min), collected in vials and kept at 4 °C until further examinations. A portion of each liver was fixed in 10% formalin and kept for histopathological assessments.

#### *Determination of biochemical parameters*

Biochemical parameters were assessed according to standard methods. The serum alanine aminotransferase (ALT), aspartate aminotransferase (AST) and alkaline phosphatase (ALP) activities were measured by using the photometric method (DGKC) based on conversion of *p*-nitrophenylphosphate+H<sub>2</sub>O to phosphate + *p*-nitrophenol. The assay kits were obtained from Parsazmun Co., Iran.

#### *Histopathological analysis*

The livers were removed, fixed in 10% neutral buffered formalin for 72 h, dehydrated, and embedded in paraffin. Later, 5 µm sections were prepared followed by staining with haematoxylin–eosin for histological assessments. Vacuolization, necrotic cells, hypereosinophilic cytoplasm, congested blood vessels, congested blood sinusoids, degeneration of lobules and inflammatory cell infiltrations were used as criteria to assess the degree of histopathological

features and graded from scores 0-3. 0: normal; 1: mild injury; 2: moderate injury; 3: severe liver injury [12].

#### *Statistical analysis*

All data were expressed as mean ± SD. Multiple comparisons were performed by one-way analysis of variance (ANOVA) followed post Hoc (tukey). Value of  $p < 0.05$  was considered to be significant.

#### **Results and Discussion**

The results of the hepatoprotective effect of ME are summarized in table 1. The levels of ALT, AST and ALP enzymes significantly increased in the formalin group compared to the control group ( $p < 0.005$ ). The mice treated with ME showed a significant decrease in ALT and ALP compared to the formalin group in some doses according to table 1 ( $p < 0.05$ ). AST also significantly increased in the formalin group compared to the control, E3 (5 mg/kg) and E5 (15 mg/kg) groups ( $p < 0.05$ ). Doses of 5 and 15 mg ME showed the strongest hepatoprotective effect against formalin induced liver injury (table 1).

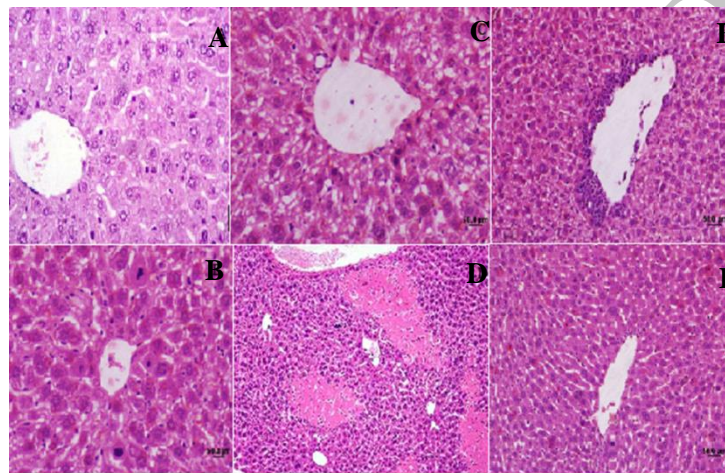
The liver sections in control group showed normal cellular architecture with distinct hepatic cells, sinusoidal spaces and a central vein (figure 1 A). In contrast, the E2 group exhibited the most severe damage. The liver sections in this group showed dilated congested blood sinusoids, congested blood vessel, inflammatory cells (lymphocytes) infiltration, necrosis, increasing of hypereosinophilic cytoplasm, degeneration of the hepatocytes and increased vacuole formation. The von kupffer cells were frequently seen and became more prominent (figure 1 B-E). Changes were almost improved in E3 group, which exhibited areas of normal liver architecture and patches of necrotic hepatocytes that was more similar to the control group (figure 1 F). The liver sections of the mice treated with ME in E4 group (figure 2 A) showed a relatively normal lobular pattern with a mild degree of lymphocyte infiltration compared to E2 group.

**Table 1.** The effects of methanol extracts of *A.bracteatum* on biochemical parameters of FA-induced liver injury in mice

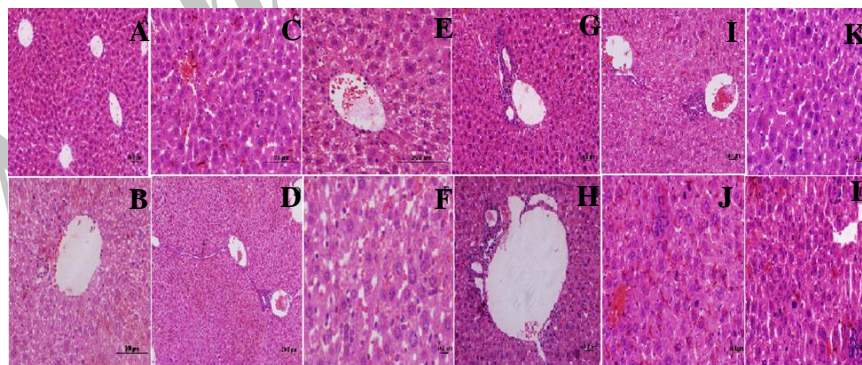
Groups	Dosage	ALT(U/L)	AST(U/L)	ALP(U/L)
E1	normal saline 0.9%	49±17.88	81.83±19.35	237.80±120.03
E2	10mg/kg FA 37%	92±7.65 <sup>a</sup>	255.42±59.20 <sup>a</sup>	523.85±124.07 <sup>a</sup>
E3	10mg/kg FA+5mg ME	51.33±14.05 <sup>bc</sup>	111.20±24.78 <sup>bc</sup>	241.42±69.49 <sup>bc</sup>
E4	10mg/kg FA+10mg ME	52.66±7.94 <sup>bc</sup>	211.50±115.30	278.16±114.67 <sup>bc</sup>
E5	10mg/kg FA+15mg ME	53±7.31 <sup>bc</sup>	156.60±29.64 <sup>bc</sup>	186±119.11 <sup>bc</sup>
E6	10mg/kg FA+20mg ME	72.33±34.71	246.16±112.25	243.33±55.95 <sup>bc</sup>
E7	10mg/kg FA+50mg ME	68.85±24.17	246.14±50.65	253.85±157.60 <sup>bc</sup>
E8	10mg/kg FA+100mg ME	72.40±30.15	242.80±111.78	198.80±87 <sup>bc</sup>

Data are expressed as the mean ± SD, n = 7. ALT: alanine aminotransferase, AST: aspartate aminotransferase, ALP: alkaline phosphatase

<sup>a</sup>: p= 0.002, compared to the control group; <sup>b</sup>: p < 0.01, compared to the FA group; <sup>c</sup>: p < 0.05, compared to the FA group



**Figure 1.** Photomicrographs of sections of liver stain H & E. (A): normal cellular architecture with distinct hepatic cells, sinusoidal spaces and a central vein in control group. X400 (B, C, D and E): sections of formaldehyde-treated liver (Group E2) showed degeneration of the hepatocytes (B-X400), inflammatory cells infiltration (C- X200), increased kupffer cells, hyper-eosinophilic cytoplasm (D-X400) and necrosis (E- X100). (F): changes were almost improved in E3 group. X200.



**Figure 2.** Photomicrographs of sections of liver stain H & E. (A): mild degree of lymphocyte infiltration in E4 group. X100 (B): a section of E5 group showed lymphocyte infiltration and congested blood vessel (CBV). X200 (C): Liver cells treated with 20 mg of the ME showed central venous distension, and mild lymphocyte infiltration. X200 (D-G): The liver sections in E6 group showed lymphocytes infiltration (D X200), vacuole formation(E X200), congested blood vessel, lymphocytes infiltration (F X100) and increased kupffer cells (G X400). (H-L): lymphocytes infiltration (H X200), central venous distension (I X200), congested blood vessel (J X400), hyper eosinophil cell (K X400) and increased kupffer cells (L X100) in E7 group.

Histopathological observations of liver sections from the E5 group showed a relatively normal lobular pattern with a mild degree of lymphocyte infiltration and congested blood vessel (figure 2 B). The animals treated with 20 mg/kg of the ME in E5 group (figure 2 C) showed improvement in liver histology with central venous distension and mild lymphocyte infiltration compared to E2 group.

Treatment with 50 and 100 mg/kg ME in E7 and E8 groups could not improve liver histology against FA. There were no differences in histology in these groups. In both groups the liver damage signs included infiltration of inflammatory mononuclear cells, congested blood vessel, central venous distension, increased kupffer cells compared to the control group (figure 2 H-L).

Administration of FA during 2 weeks caused clear changes in the liver tissue and functions. Excessive production of reactive species produces damage through oxidation which engaged cellular components [13]. FA can lead to oxidative damage in biological systems. Some significant changes include activation of necrosis factor kB (NF-kB) and decrease in activities of superoxide dismutase and glutathione peroxidase [14]. In the present study, the FA group clearly showed infiltration of inflammatory cells, hypereosinophilic cytoplasm, kupffer cells accumulation and dilated blood sinusoids [15]. The accumulation of Kupffer cells in FA-treated animals liver lobules was attributed to accumulation of the formaldehyde reactive chemical intermediates. The formaldehyde hepatotoxic mechanisms may be the result of increase in the production of the reactive species such as ROS and other oxidant intermediates, that caused breakage in DNA structure and protein cross links [11,16,17]. Liver enzymes such as ALT and AST released and elevated in blood during FA exposure. Considering these liver marker enzymes can be useful parameters for monitoring liver condition. One of the major goals in hepatotoxicity treatment is maintaining

the liver enzymes level in normal range. Natural remedies have shown suitable activity for liver protection in traditional systems of medicine [18,19].

Hepatoprotective effects of some Plumbaginaceae plants such as *Limonium sinense* (Girard) Kuntze, *Plumbago zeylanica* (L) have been determined previously. Compounds from the aqueous extracts of *L. sinense* roots have shown hepatoprotection through mitochondrial mechanisms [20]. In another research the *L. sinense* root polysaccharides showed hepatoprotective effects [21]. Similar potencies were also observed in *P. zeylanica* [22]. In the study, *A. bracteatum* methanolic extract showed maximum preservative effects in liver cell at the concentration of 10 mg, similar effect observed in other concentration against FA.

The methanol extract of *A. bracteatum* probably exerts its protective action against formaldehyde induced liver cell metabolic alterations by the antioxidant effect on formaldehyde induced toxicants[21]

It has been hypothesized that one of the principal causes of FA induced liver injury is lipid peroxidation induced by the free radical derivatives of FA. Thus, antioxidant activity or inhibition of free radicals generation could be important in the protection against FA induced liver injury by *A. bracteatum* (Girard) Boiss. methanol extract. The results obtained from the present study indicated that the methanol extract from the areal parts of *A. bracteatum* (Girard) Boiss. exhibited hepatoprotective effect against FA induced liver damage with decreasing the serum levels of ALT and AST (maximum effects at the 5 and 15 mg/kg dose of ME) towards their respective normal value that is an indication of stabilization of plasma membrane as well as repairing of hepatic tissue damage caused by FA. Effective control of ALP in ME treated groups points towards the FA group showed an early improvement in the secretory mechanism of hepatocytes. Histopathological observations also support the hepatoprotective potential of *A.*

*bracteatum* (Girard) Boiss. methanol extract.

### Acknowledgements

The authors thank the deputy of Guilan Medical Sciences Research Affairs for funding this study and especially thank Mr. Hamid Morovati for his assistance with animal handling and his technical support during the course of the study. This paper was part of a student thesis (IR.GUMS.REC.1930349905).

### Declaration of interest

The authors declare that there is no conflict of interest. The authors alone are responsible for the content of the paper.

### References

- [1] Gebhardt R. Metabolic zonation of the liver: regulation and implications for liver function. *Pharmacol Ther.* 1992; 53(3): 275-354.
- [2] Murray CJ, Lopez AD. Mortality by cause for eight regions of the world: Global burden of disease study. *Lancet.* 1997; 349(9061): 1269-1276.
- [3] Achliya GS, Wadodkar SG, Dorle AK. Evaluation of hepatoprotective effect of *Amalkadi Ghrita* against carbon tetrachloride-induced hepatic damage in rats. *J Ethnopharmacol.* 2004; 90(2-3): 229-232.
- [4] Sultana S, Perwaiz S, Iqbal M, Athar M. Crude extracts of hepatoprotective plants, *Solanum nigrum* and *Cichorium intybus* inhibit free radical-mediated DNA damage. *J Ethnopharmacol.* 1995; 45(3): 189-192.
- [5] Oshima Y, Namao K, Kamijou A, Matsuoka S, Nakano M, Terao K, Ohizumi Y. Powerful hepatoprotective and hepatotoxic plant oligostilbenes, isolated from the Oriental medicinal plant *Vitis coignetiae* (Vitaceae). *Experientia.* 1995; 51(1): 63-66.
- [6] Pradhan S, Girish C. Hepatoprotective herbal drug, silymarin from experimental pharmacology to clinical medicine. *Indian J Med Res.* 2006; 124(5): 491-504.
- [7] Strubelt O, Younes M, Pentz R, Kühnel W. Mechanistic study on formaldehyde-induced hepatotoxicity. *J Toxicol Env Heal A.* 1989; 27(3): 351-366.
- [8] Teng S, Beard K, Pourahmad J, Moridani M, Easson E, Poon R, O'Brien PJ. The formaldehyde metabolic detoxification enzyme systems and molecular cytotoxic mechanism in isolated rat hepatocytes. *Chem-Biol Interact.* 2001; 130(3): 285-296.
- [9] Girish C, Pradhan SC. Indian herbal medicines in the treatment of liver diseases: problems and promises. *Fundam Clin Pharm.* 2012; 26(2): 180-189.
- [10] Rahmatullah M, Khatun Z, Hasan A, Parvin W, Moniruzzaman M, Khatun A, Mahal MJ, Bhuiyan S, Mou SM, Jahan R. Survey and scientific evaluation of medicinal plants used by the Pahan and Teli tribal communities of Natore district, Bangladesh. *Afr J Tradit Complement Altern Med.* 2012; 9(9): 366-373.
- [11] Gulec M, Gurel A, Armutcu F. Vitamin E protects against oxidative damage caused by formaldehyde in the liver and plasma of rats. *Mol Cell Biochem.* 2006; 290(1): 61-67.
- [12] Kim MN, Kim BK, Han KH. Hepatocellular carcinoma in patients with chronic hepatitis C virus infection in the Asia-Pacific region. *J Gastroenterol.* 2013; 48(6): 681-688.
- [13] Wallace DC, Melov S. Radicals r'aging. *Nat Genet.* 1998; 19: 105-106.
- [14] Kaneko JJ, Harvey JW, Bruss ML. *Clinical biochemistry of domestic animals.* 16<sup>th</sup> ed. London: Academic press, Elsevier, 2008.
- [15] Cikmaz S, Kutoglu T, Kanter M, Mesut R. Effect of formaldehyde inhalation on rat livers: a light and electron microscopic study. *Toxicol Ind Health.* 2010; 26(26): 113-119.
- [16] Yu P, Zuo D. Formaldehyde produced endogenously via deamination of methylamine. A potential risk factor for initiation of endothelial injury. *Atherosclerosis.* 1996; 120(1-2): 189-197.
- [17] Sögüt S, Songur A, Özen OA, Özyurt H, Sarsilmaz M. Does the subacute (4-week) exposure to formaldehyde inhalation lead to oxidant/antioxidant imbalance in rat liver?

- Eur J General Medicine*. 2004; 1(3): 26-32.
- [18] Ali SS, Kasoju N, Luthra A, Singh A, Sharanabasava H, Sahu A, Bora U. Indian medicinal herbs as sources of antioxidants. *Food Res Int*. 2008; 41(1): 1-15.
- [19] Gutiérrez RM, Solís RV. Hepatoprotective and inhibition of oxidative stress in liver of *Prostechea michuacana*. *Rec Nat Prod*. 2009; 3(1): 46-51.
- [20] Tang X, Gao J, Chen J, Xu L, Tang Y, Zhao X, Michael L. Mitochondrial modulation is involved in the hepatoprotection of *Limonium sinense* extract against liver damage in mice. *J Ethnopharmacol*. 2008; 120(111): 427-431.
- [21] Tang X, Yan L, Gao J, Ge H, Yang H, Lin N. Optimization of extraction process and investigation of antioxidant effect of polysaccharides from the root of *Limonium sinense* Kuntze. *Pharmacogn Mag*. 2011; 7(27): 186-192.
- [22] Kanchana N, Sadiq AM. Hepatoprotective effect of *Plumbago zeylanica* on paracetamol induced liver toxicity in rats. *Int J Pharm Pharm Sci*. 2011; 3(1): 151-154.

Archive of SID