

## The Anomalous Origin of the Left Coronary Artery from the Pulmonary Artery (ALCAPA): a Case Series and Brief Review

Aliasghar Moeinipour<sup>1</sup>, Mohammad Abbassi Teshnisi<sup>2</sup>, Hassan Mottaghi Moghadam Shahri<sup>3</sup>, Nahid Zirak<sup>4</sup>, Reihaneh Hasanzadeh<sup>5</sup>, \*Hamid Hoseinikhah<sup>1</sup>, Abbas Bahreini<sup>6</sup>

<sup>1</sup>Assistant Professor, Department of Cardiac Surgery, Atherosclerosis Prevention Research Center, Faculty of Medicine, Mashhad University of Medical Sciences, Mashhad, Iran. <sup>2</sup>Associate Professor, Department of Cardiac Surgery, Atherosclerosis Prevention Research Center, Faculty of Medicine, Mashhad University of Medical Sciences, Mashhad, Iran. <sup>3</sup>Associate Professor of Pediatric Cardiology, Faculty of Medicine, Mashhad University of Medical Sciences, Mashhad, Iran. <sup>4</sup>Associate Professor, Department of Anesthesiology, Imam Reza Hospital, Mashhad University of Medical Sciences, Mashhad, Iran. <sup>5</sup>Resident of Anesthesiology, Department of Anesthesiology, Mashhad University of Medical Sciences, Mashhad, Iran. <sup>6</sup>Resident of Neurosurgery, Faculty of Medicine, Shiraz University of Medical Sciences, Shiraz, Iran.

### Abstract

#### Background

Anomalous left coronary artery from the pulmonary artery (ALCAPA) is a rare congenital cardiovascular defect that occurs in approximately 1/300 000 live births or 0.5% of children with congenital heart disease. There are two types of ALCAPA syndrome: the infant type and the adult type. The most infants experience myocardial infarction and congestive heart failure, and approximately 90% die within the first year of life; also, without early surgical intervention they have a dismal prognosis.

#### Materials and Methods

We report 3- year experiences from January 2013 to January 2016 of Imam Reza Hospital center (a tertiary referral hospital North East of Iran) that consist of all patients with ALCAPA syndrome.

#### Results

The Takeuchi procedure, were successfully performed in five children with anomalous origin of the left coronary artery from the pulmonary artery (ALCAPA). There was no death and significant mitral regurgitation postoperative (n=0) in this short study. All of patients (n=5) had evidence of improving ischemic myocardium status by increasing of ejection fraction and regional wall motion of left ventricular in follow up echocardiography.

#### Conclusion

The only cure treatment for ALCAPA syndrome is surgical intervention that needs to be performed immediately after diagnosis to prevent myocardial infarction and chronic heart failure. Today, establishing a system with two coronary arteries is the goal in definitive surgical repair. The Takeuchi procedure is a prefer method to establish a two-coronary repair for ALCAPA.

**Key Words:** ALCAPA, Children, Coronary artery, Heart surgery, LAD, Takeuchi procedure.

\*Please cite this article as: Moeinipour A, Abbassi Teshnisi M, Mottaghi Moghadam Shahri H, Zirak N, Hasanzadeh R, Hoseinikhah H, et al. The Anomalous Origin of the Left Coronary Artery from the Pulmonary Artery (ALCAPA): a Case Series and Brief Review. Int J Pediatr 2016; 4(2): 1397-1405.

#### \*Corresponding Author:

Hamid Hoseinikhah, MD, Assistant Professor, Department of Cardiac Surgery, Atherosclerosis Prevention Research Center, Faculty of Medicine, Mashhad University of Medical Sciences, Mashhad, Iran.

Email: HoseinikhahH@mums.ac.ir

Received date Dec 10, 2015 ; Accepted date: Jan 12, 2016

## 1-INTRODUCTION

Anomalous left coronary artery from the pulmonary artery (ALCAPA or Bland-White-Garland syndrome or White-Garland syndrome) is a rare congenital anomaly in which the left coronary artery (LCA) branches off the pulmonary artery instead of the aortic sinus(1). After birth, the pressure in other coronary arteries (namely the RCA) will have a pressure that exceeds the LCA and collateral circulation will increase. This, ultimately, can lead to blood flowing from the RCA into the LCA (retrograde) and into the pulmonary artery, thus forming a left-to-right shunt (Figure.1) (2).

ALCAPA syndrome was first described in 1866. The first clinical description in conjunction with autopsy findings was described by Bland and colleagues in 1933, so the anomaly is also called Bland-White-Garland syndrome (3). In 1962, Fontana and Edwards reported a series of 58 postmortem specimens that demonstrated that most patients had died at a young age (4).

Presently, the prognosis for patients with ALCAPA is dramatically improved as a result of both early diagnosis using echocardiography with color flow mapping and improvements in surgical techniques, including myocardial preservation.

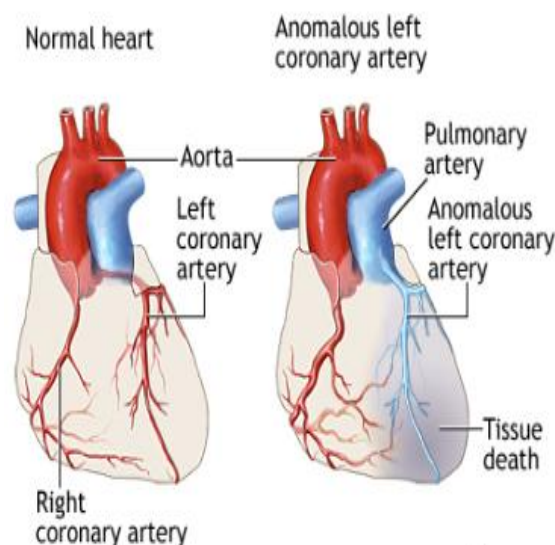
The ALCAPA anomaly may result from (3) abnormal septation of the conotruncus into the aorta and pulmonary artery, or from (4) persistence of the pulmonary buds together with involution of the aortic buds that eventually form the coronary arteries.

ALCAPA is usually an isolated cardiac anomaly but, in rare incidences, has been described with patent ductus arteriosus, ventricular septal defect, tetralogy of Fallot, and coarctation of the aorta. Extremely rare variations of anomalous origin of the coronary arteries from the

main pulmonary artery include the following:

- The left anterior descending or circumflex branches;
- The right coronary, often discovered as an incidental finding on autopsy;

Both the right and left coronary arteries, a circumstance not compatible with survival(3,4).



**Fig.1:** Anomalous left coronary artery

### 1-1. Alternative Names

Anomalous origin of the left coronary artery arising from the pulmonary artery; ALCAPA; ALCAPA syndrome; Bland-White-Garland syndrome (1, 2).

### 1-2. Symptoms

Symptoms of anomalous left coronary artery in an infant include:

- Crying or sweating during feeding;
- Pale skin;
- Poor feeding;
- Rapid breathing;
- Sweating;
- Symptoms of pain or distress in the baby (often mistaken for colic).

Symptoms can appear within the first 2 months of the baby's life (1, 3).

### 1-3. Exams and Tests

ALCAPA can be diagnosed in an infant. However, this defect may not be diagnosed until someone is a child or adult.

Signs of ALCAPA include:

- Abnormal heart rhythm;
- Enlarged heart;
- Heart murmur (rare);
- Rapid pulse.

Tests for anomalous left coronary artery include:

- A test of the electrical activity in the heart (electrocardiogram);
- A special dye injected into the blood vessels of the heart to see their structure and position (arteriography);
- A thin tube (catheter) inserted in a blood vessel of the heart to measure blood pressure and oxygen levels (cardiac catheterization);
- Cardiac magnetic resonance imaging (MRI);
- Chest X-rays;
- Ultrasound of the heart (echocardiogram) (1, 2).

### 1-4. Pathophysiology

Anomalous origin of the left coronary artery from the pulmonary artery (ALCAPA) does not present prenatally because of the favorable fetal physiology that includes (1) equivalent pressures in the main pulmonary artery and aorta secondary to a nonrestrictive patent ductus arteriosus, and (2) relatively similar oxygen concentrations due to parallel circulations. This results in normal myocardial perfusion and, therefore, no stimulus for collateral vessel formation between the right and left coronary artery systems is present.

Shortly after birth, as the circulation becomes one in series, pulmonary artery

pressure and resistance decrease, as does oxygen content of pulmonary blood flow. This results in the left ventricular myocardium being perfused by relatively desaturated blood under low pressure, leading to myocardial ischemia; low pressure is more important in causing decreased myocardial perfusion.

Initially, myocardial ischemia is transient, occurring during periods of increased myocardial demands, such as when the infant is feeding and crying. Further increases in myocardial oxygen consumption lead to infarction of the anterolateral left ventricular free wall. This often causes mitral valve papillary muscle dysfunction and variable degrees of mitral insufficiency. Collateral circulation between the right and left coronary systems ensues. Left coronary artery flow reverses and enters the pulmonic trunk due to the low pulmonary vascular resistance (coronary steal phenomena). As a result, left ventricular myocardium remains under perfused. Consequently, the combination of left ventricular dysfunction and significant mitral valve insufficiency leads to Congestive heart failure (CHF) symptoms (eg, tachypnea, poor feeding, irritability, diaphoresis) in the young infant. Inadequate myocardial perfusion likely causes significant chest pain and these symptoms of myocardial ischemia may be misinterpreted as routine infantile colic (5).

### 1-5. Etiology

Inheritance is not a factor for anomalous origin of the left coronary artery from the pulmonary artery (ALCAPA). For example, if two family members are affected, the fact that they are within the same family did not have a role in their development of the condition. The condition is generally considered to be on the basis of multifactorial inheritance, similar to other congenital heart defects. In utero exposure to teratogens, chromosomal

abnormalities, or other risk factors are unrelated to ALCAPA. Other congenital cardiac defects, such as patent ductus arteriosus, ventricular septal defect, tetralogy of Fallot, or coarctation of the aorta, rarely may be associated with ALCAPA. No specific association with any noncardiac anomalies is noted (6).

## **1-6. Prognosis**

### **1-6-1. Mortality/Morbidity**

Early diagnosis using echocardiography with color flow mapping and improvements in surgical techniques (eg, myocardial preservation) dramatically improve prognosis. Left untreated, the mortality rate in the first year of life is 90% secondary to myocardial ischemia or infarction and mitral valve insufficiency leading to CHF. Sudden death may occur because of inadequate collateral circulation between the left and right coronary artery systems and/or development of arrhythmia (5, 6).

### **1-6-2. Complications**

Complications are rare. The need for future valve surgery depends on the occurrence of hemodynamic complications (eg, residual mitral valve insufficiency precipitated by permanent damage of the mitral valve architecture) following surgery.

Late complications related to coronary artery insufficiency are more likely to occur if revascularization was accomplished by any of the following:

- Surgical ligation;
- Bypass grafts that may become occluded or stenotic;
- Intrapulmonary tunnel technique, which may cause supralvalvar pulmonary stenosis or, less commonly, become obstructed at the surgically created aortopulmonary window.

Inadequate growth of the coronary anastomosis is possible, although unlikely, if surgical reimplantation of the left coronary artery was performed. This occurrence is similar to the rare reports of late coronary artery problems following the arterial switch procedure for transposition of the great vessels that also requires direct coronary transfer and reimplantation (1, 4, 5).

## **1-7. Treatment**

Surgery is needed to correct ALCAPA. Only one surgery is needed in most cases. However, the surgery will depend on the baby's condition and the size of the involved blood vessels.

If the heart muscle supporting the mitral valve is seriously damaged from decreased oxygen, the baby may also need surgery to repair or replace the valve. The mitral valve controls blood flow between the chambers on the left side of the heart.

If the baby's heart is already severely damaged from lack of oxygen, a heart transplant may be an option.

Medicines used include:

- "Water pills" (diuretics);
- Drugs that make the heart muscle pump harder (inotropic agents);
- Drugs that lower the workload on the heart (beta-blockers, ACE inhibitors) (1, 4-6).

## **1-8. Patient Education**

All patients should undergo formal exercise stress testing at an appropriate age as an aid in determining an appropriate exercise program. Long-term physical restrictions, including restrictions of participation in competitive sports, are a direct function of whether myocardial ischemia is evident at rest or during exercise. No dietary restrictions are necessary following successful surgical revascularization with subsequent clinical improvement (5).

## 2-MATERIALS AND METHODS

In this study we report 3- year experiences of Imam Reza Hospital center of Mashhad- Iran, that consist of 5 patients who known cases of ALCAPA syndrome. All of cases were confirmed with pediatric cardiologist with use of transthoracic echocardiography to confirm pulmonary artery catheter placement. Mean of Left Ventricular Ejection Fraction (LVEF) index was 22% (15-30). 4 out of 5 patients (80%) of them were male. Age at operation ranged from 8 to 33 months (median 18 months).

The mid-term results were evaluated in the all survivors with a follow-up mean of 12 months. In all surviving patients with two-vessel coronary blood supply Takeuchi procedure left ventricular end-diastolic volume and left ventricular ejection fraction returned to near normal values 2 to 12 months postoperatively.

## 3- RESULTS

All of this cases (n=5) intracardiac tunnel repair (Takeuchi procedure) was used with good results. Mean of cardiopulmonary bypass time was 64 minutes (main times 45-85) and aortic clamp time 52 minutes (main times = 40-63). There were no deaths, and follow-up coronary angiography showed no graft failure; also, all of patients are discharged successfully and in good clinical condition up to 1- year follow up. None of our patients had sever mitral valve insufficiency (n=0). In follow up echocardiography in all of patients (n=5) LV EF index have increased. All of children gain weight after surgery with improving in feeding status.

## 4- DISCUSSION

ALCAPA syndrome is congenital anomaly of coronary artery origin that is one of the less common congenital heart anomalies. ALCAPA syndrome occurs once per 300,000 live births. (7-9). The

incidence of coronary anomaly is about 1% of all of congenital heart diseases that the most significant of them is ALCAPA syndrome, that is anomalous origin of left anterior descending (LAD) coronary artery that normal position of LAD coronary bottom in Aorta is absent and ostium of LAD is from Pulmonary trunk (main pulmonary artery) (10,11). ALCAPA anomaly usually is isolated congenital heart disease (12). This malformation lead to larger left to right shunt with steal of coronary perfusion. This process a few months after birth present with symptom and sign of myocardial ischemia, sever crying of child at the time of breast-feeding and Failure to thrive (FTT), multiple myocardial infarction, significant ischemic mitral regurgitation, Ischemic cardiomyopathy (12-16). At the late stage of this anomaly congestive heart failure (CHF) is occurred that if undiagnosed and untreated immediately, many of these children have no any options expect Heart transplant (14).

Child who born with ALCAPA syndrome usually is symptomatic after first month that baby with breastfeeding have sign of myocardial ischemia with crying and sweating (1, 2, 14). Pathophysiologic mechanism of ALCAPA syndrome is coronary steal because of low pressure in pulmonary artery vasculature, left coronary artery pass the blood from heart to lungs and in fact the direct of blood flow is retrograde to main pulmonary artery and lead to recurrent and chronic myocardial ischemia and myocardial infarction especially at time of increased myocardial oxygen consumption (15-17). The final course of untreated ALCAPA syndrome is varies of mild ischemia to ventricular arrhythmia and chronic heart failure and sudden cardiac death (16).

Typical presentation is 3 to 6 months baby with symptom and sign of myocardial ischemia and left side heart failure also, with mitral insufficiency (18-20). Pediatric

cardiologist should have a high suspicion for rapid diagnosis of ALCAPA syndrome because of dismal prognosis for missed patients (10, 12). Echocardiography in hand of experienced operators can recommend diagnosis from abnormal flow in Doppler examination and severe cardiomegaly and hypokinesia and dyskinesia in anterior and lateral segment (10, 12). Possible mitral regurgitation also should be noticed. All of these findings indirectly can suggest diagnosis of possible coronary anomaly. Although, some centers and authors successfully use of Computed tomography (CT) angiography and Magnetic resonance imaging (MRI) imaging for correct diagnosis, but angiography and catheterization absolutely can confirm diagnosis. In cardiac catheterization with aortography, only one coronary is obviously that include the right coronary artery (RCA) and left coronary artery is absent. In selective injection of RCA we see that retrograde left coronary artery is clear that at the end of its course pulmonary Trunk is seen. Pediatric cardiologist can evaluate severity of mitral regurgitation in left ventricle injection. Patients with ALCAPA syndrome are candidate for surgery that should do immediately operation (21).

Historically first case of ALCAPA anomaly was reported in 1866. Early surgical attempts at repair of an anomalous left coronary artery from the pulmonary artery (ALCAPA) were palliative. In 1953, Potts proposed an aortopulmonary anastomosis to increase oxygen saturation in the main pulmonary artery. Also in 1953, Mustard described a left carotid artery-to-anomalous left coronary artery procedure (22). Sabiston et al. and Cooley et al. proposed simple ligation of the proximal origin of the anomalous left coronary artery and Coronary artery bypass grafting (CABG) with anastomosis of saphenous vein to LAD from the aorta

and in 1968, Meyer et al. described a left subclavian artery-to-anomalous left coronary artery repair. Direct anastomosis of the anomalous left coronary artery of the pulmonary artery directly to the aorta, was described in the 1970s and currently remains the procedure of choice, for patients in whom direct transfer of the coronary artery is not possible, performing the novel repair of creating an intrapulmonary aortocoronary tunnel may be appropriate, as described by Takeuchi in 1979 (22-30).

This type of complex repair for ALCAPA anomaly usually has done on Cardiopulmonary bypass (CPB) (29, 30). Takeuchi procedure involves creation of an aortopulmonary window and an intrapulmonary tunnel that baffles the aorta to the ostium of the anomalous left coronary artery. The incidence of late complications following the Takeuchi repair is unknown (30). Important key in success of this procedure is destination of bottom of left coronary artery to left side of aorta, because if this distance under 8 mm, direct reimplantation of left coronary artery can be performed but in larger distance there is so much tension on suture line of repair site and in this cases intracardiac tunnel repair or Takeuchi procedure is performed that a piece of tube graft in pulmonary artery is used for reaching of left coronary artery to aorta (21-30). In face of mitral valve regurgitation, there is controversy between referral centers and cardiac surgeon. Some of them try to repair of mitral valve, but others believe that after correction of underlying problem and reimplantation of coronary artery on aorta, after short time of surgery, reverse of myocardial ischemia is happened and we see decrease of severity of Mitral regurgitation (26, 27).

## 5- CONCLUSION

Anomalous left coronary artery from the pulmonary artery (ALCAPA) is a rare

congenital cardiovascular defect that occurs in 0.5% of children with congenital heart disease. The left coronary artery, which carries blood to the heart muscle, is connected to the pulmonary artery instead of to the aorta. An anomalous left coronary artery from the pulmonary artery is a problem that occurs when the baby's heart is developing early in the pregnancy. The developing blood vessels in the heart do not connect correctly. In the normal heart, the left coronary artery starts in the aorta. The aorta is the major blood vessel that takes oxygen-rich blood from the heart to the rest of the body. In children with ALCAPA, the left coronary artery starts at the pulmonary artery. The pulmonary artery is the major blood vessel that takes oxygen-poor blood from the heart to the lungs. When this defect occurs, blood that is lacking in oxygen, is carried to the left side of the heart. Therefore, the heart does not get enough oxygen. When the heart muscle, is deprived of oxygen, the tissue begins to die. This condition leads to a heart attack in the baby.

A condition known as "coronary steal" further damages the heart in babies with ALCAPA. The low blood pressure in the pulmonary artery causes blood from the abnormal left coronary artery to flow toward the pulmonary artery instead of toward the heart. This results in less blood and oxygen to the heart. This problem will also lead to a heart attack in a baby. Coronary steal develops over time in babies with ALCAPA if the condition is not treated early. Without treatment, most babies do not survive their first year. Children that do survive without treatment may have serious cardiovascular problems. Babies with this problem who are not treated could die suddenly during the following years. With prompt treatment such as surgery, most babies do well and can expect a normal life. Infants with anomalous left coronary artery from the pulmonary artery usually do well for a

short period then gradually become fussy and irritable. Typically, they may display pallor, irritability, and diaphoresis after feeding, which are often attributed to colic. Signs and symptoms of CHF, including tachypnea, tachycardia, diaphoresis, and poor feeding, eventually ensue, leading to poor weight gain. Usually no obvious evidence of a systemic illness is noted. In rare instances, children outgrow these symptoms and gradually become asymptomatic, although periodic dyspnea, angina pectoris, syncope, or sudden death may still occur in adulthood.

At current study, the early, midterm and long term follow up of patients with of the Takeuchi technique in ALCAPA syndrome showed good result such as our patients. Patients have a better feeding and good weight over time. Occasionally, cardiac transplantation has been required in patients with anomalous left coronary artery of the pulmonary artery with severe cardiac dysfunction (27-32).

**6- CONFLICT OF INTEREST:** None.

## 7-ACKNOWLEDGMENTS

We would like to thanks from Mrs. Elham Ghandomro and Mrs. Sakineh Boland Mahaneh, for corporation in this research.

## 8-REFERENCES

1. Chang RR, Allada V. Electrocardiographic and echocardiographic features that distinguish anomalous origin of the left coronary artery from pulmonary artery from idiopathic dilated cardiomyopathy. *Pediatr Cardiol* 2001; 22(1):3-10.
2. Crawford M, DiMarco J, Paulus W. *Cardiology*. 3rd Edition. Mosby; 2009. 229. ISBN: 0723434859.
3. Bland EF. Congenital anomalies of the coronary arteries: report of an unusual case associated with cardiac hypertrophy 1933; 8:787-801.

4. Fontana RS, Edwards JE. Congenital Cardiac Disease: a Review of 357 Case Studies Pathologically. Philadelphia:WB Saunders; 1962. 291.
5. Su LS, Burkhart HM, O'Leary PW, Dearani JA. Mitral valve arcade with concomitant anomalous left coronary artery from the pulmonary artery. *Ann Thorac Surg* 2011; 92(6):e121-3.
6. Arciniegas E, Farooki ZQ, Hakimi M, Green EW. Management of anomalous left coronary artery from the pulmonary artery. *Circulation* 1980; 62(2 Pt 2):I180-9.
7. Walsh MA, Duff D, Oslizlok P, Redmond M, Walsh KP, Wood AE, et al. A review of 15-year experience with anomalous origin of the left coronary artery. *Ir J Med Sci* 2008; 177(2):127-30.
8. He XH, Li Y, Huang MR, Gao W, Li F, Yu ZQ, et al. [Anomalous origin of the left coronary artery from the pulmonary artery: report on 10 cases]. *Zhongguo Dang Dai Er Ke Za Zhi* 2007;9(1):25-7.
9. Cowles RA, Berdon WE. Bland-White-Garland syndrome of anomalous left coronary artery arising from the pulmonary artery (ALCAPA): a historical review. *Pediatr Radiol* 2007;37(9):890-95.
10. Wu QY, Xu ZH. Surgical treatment of anomalous origin of coronary artery from the pulmonary artery. *Chin Med J (Engl)* 2008;121(8):721-24.
11. Ono M, Goerler H, Boethig D, Breyman T. Surgical repair of anomalous origin of the left coronary artery arising from the left pulmonary artery. *Ann Thorac Surg* 2009;88(1):275-76.
12. Chiu HH, Wang JK, Chen CA, Chiu SN, Lin MT, Lue HC, et al. Resolution of pathologic Q wave, left ventricular dysfunction and mitral regurgitation after dual coronary repair of the anomalous origin of the left coronary artery from the pulmonary artery. *Eur J Pediatr* 2008;167(11):1277-82.
13. Ojala T, Salminen J, Happonen JM, Pihkala J, Jokinen E, Sairanen H. Excellent functional result in children after correction of anomalous origin of left coronary artery from the pulmonary artery--a population-based complete follow-up study. *Interact Cardiovasc Thorac Surg* 2010;10(1):70-5.
14. Khatri S, Varma SK, Khatri P, Kumar RS. 64-slice multidetector-row computed tomographic angiography for evaluating congenital heart disease. *Pediatr Cardiol* 2008; 29(4):755-62.
15. Jebelli M, Kernstine K, Mandegar MH, Sarzaeem MR, Rayatzadeh H. The 64-multislice computed tomogram averts misdiagnosis of an anomalous origin of the left main coronary artery. *Pediatr Cardiol* 2009;30(8):1184-85.
16. Friedman AH, Fogel MA, Stephens P Jr, Hellinger JC, Nykanen DG, Tweddell J, et al. Identification, imaging, functional assessment and management of congenital coronary arterial abnormalities in children. *Cardiol Young* 2007;17(Suppl 2):56-67.
17. Hildreth B, Junkel P, Allada V, Sintec C, Sapin S. An uncommon echocardiographic marker for anomalous origin of the left coronary artery from the pulmonary artery: visualization of intercoronary collaterals within the ventricular septum. *Pediatr Cardiol* 2001; 22(5):406-8.
18. Yang YL, Nanda NC, Wang XF, Xie MX, Lu Q, He L, et al. Echocardiographic diagnosis of anomalous origin of the left coronary artery from the pulmonary artery. *Echocardiography* 2007; 24(4):405-11.
19. Alva C, Gomez FD, Jimenez-Arteaga S, Martinez-Sanchez A, Ortegón-Cardena J, Yanez L, et al. Anomalous origin of the left coronary artery from the pulmonary artery. Echocardiographic diagnosis. *Arch Cardiol Mex* 2008;79(4):274-78.
20. Kudo Y, Suda K, Koteda Y. Pitfalls of echocardiographic evaluation of anomalous origin of the left coronary artery from the pulmonary trunk. *Cardiol Young* 2008;18(5):537-38.
21. Cohen MS, Herlong RJ, Silverman NH. Echocardiographic imaging of anomalous origin of the coronary arteries. *Cardiol Young* 2010; 20(Suppl 3):26-34.
22. Mustard WT. Anomalies of the coronary arteries. *Pediatric Surgery*. Chicago, IL: Mosby-Year Book; 1953. Vol 1: 433-40.



23. Barbetakis N, Efstathiou A, Efstathiou N, Papagiannopoulou P, Soulountsi V, Fessatidis I. A long-term survivor of Bland-White-Garland syndrome with systemic collateral supply: A case report and review of the literature. *BMC Surg* 2005;5:23.
24. Kazmierczak P, Ostrowska K, Dryzek P, Moll JA, Moll JJ. Repair of anomalous origin of the left coronary artery from the pulmonary artery in infants. *Interact Cardiovasc Thorac Surg* 2013; 16:797–801.
25. Karolczak MA, Wieteska J, Bęc L, Mądry W. Anomalous origin of the left coronary artery (LCA) from pulmonary trunk (Bland-White-Garland syndrome) with systemic collateral supply. *Med Sci Monit* 2001;7:755–58.
26. Sodian R, Rassoullian D, Beiras-Fernandez A, Loeff M, Schmitz C, Reichart B, et al. ALCAPA with the Ectopic Orifice at the Non-Facing Sinus Successful Anatomic Repair by Creation of an Autologous Extrapulmonary Tunnel. *Tex Heart Inst J* 2008;35:32–5.
27. Callaghan MA, O'Hare B, Casey W. What other anomalies? Failure to wean post ventricular septal defect repair secondary to anomalous origin of the left coronary artery from the pulmonary artery. *Paediatr Anaesth* 2012; 22:487–89.
28. Ginde S, Earing MG, Bartz PJ, Cava JR, Tweddell JS. Late complications after Takeuchi repair of anomalous left coronary artery from the pulmonary artery: case series and review of literature. *Pediatr Cardiol* 2012; 33(7):1115-23.
29. Hoashi T, Kagisaki K, Okuda N, Shiraishi I, Yagihara T, Ichikawa H. Indication of Takeuchi technique for patients with anomalous origin of the left coronary artery from the pulmonary artery. *Circ J* 2013; 77(5):1202-7.
30. Kuroczynski W, Kampmann C, Kayhan N, Heinemann M, Pruefer D, Vahl CF. Anomalous origin of the left coronary artery from the pulmonary artery: mid-term results after surgical correction. *Clin Res Cardiol* 2008; 97(4):266-71.
31. Scholz TD, Reinking BE. Congenital heart disease. In: Gleason CA, Devaskar S, eds. *Avery's Diseases of the Newborn*. 9th ed. Philadelphia, PA: Saunders Elsevier; 2011:chap 55.
32. Ghaderi F, Gholoobi A, Moeinipour A. Unique Echocardiographic Markers of Anomalous Origin of the Left Coronary Artery from the Pulmonary Artery (ALCAPA) in the Adult. *Echocardiography* 2014; 31(1):E13–E15.