

## Survey of the Use of X-ray Beam Collimator and Shielding Tools during Infant Chest Radiography

Vahid Karami<sup>1</sup>, \*Mansour Zabihzadeh<sup>2,3</sup>, Abdolreza Gilavand<sup>4</sup>, Nasim Shams<sup>5</sup>

<sup>1</sup> Medical Physics Student, Department of Medical Physics, School of Medicine, Ahvaz Jundishapur University of Medical Sciences, Ahvaz, Iran.

<sup>2</sup> Assistant Professor, Department of Medical Physics, Faculty of Medicine, Ahvaz Jundishapur University of Medical Sciences, Ahvaz, Iran.

<sup>3</sup> Department of Radiotherapy and Radiation Oncology, Golestan Hospital, Ahvaz Jundishapur University of Medical Sciences, Ahvaz, Iran.

<sup>4</sup> Employed Expert on Faculty Appointments at Ahvaz Jundishapur University of Medical Sciences, Ahvaz, Iran.

<sup>5</sup> Department of Oral and Maxillofacial Radiology, Faculty of Dentistry, Jundishapur University of Medical Sciences, Ahvaz, Iran.

### Abstract

#### Background

The use of shielding tools and X-ray beam collimator has extensively been advocated as effective methods to reduce radiation exposure to patients underwent radiological procedures. The aim of this study was to address the use of these protection measures during infant chest radiography.

#### Material and Methods

348 digital and/or analogue infant chest radiographs were reviewed that performed between October and December 2015 at four main hospitals of Khuzestan-Iran province to assessment the beam collimation. For each radiograph the area between current and acceptable collimation was calculated. Thirty eight radiographers were deeply interviewed to investigate the actual use of shielding tools and the main reasons for not using of them.

#### Results

Only 54 (15.5%) radiographs [33(61%) analogues and 21(39%) digital] have satisfactory collimation. The total means area of diagnostic interest (ADI) and the region outside ADI for each radiograph was estimated 171 and 86 cm<sup>2</sup>, respectively. The irradiated region outside the ADI was significantly larger in digital than in analogue images (mean of 103 cm<sup>2</sup> vs. 54 cm<sup>2</sup>; P < 0.05). Shielding tools were used regularly only by 5% of radiographers.

#### Conclusion

The radiosensitive organs of infants located outside of ADI in hospitals investigated are at risk. Adherence to safety guideline urgently recommends.

**Key Words:** Beam collimation, Chest radiography, Infant, Shielding tools.

\*Please cite this article as: Karami V, Zabihzadeh M, Gilavand A, Shams N. Survey of the Use of X-ray Beam Collimator and Shielding Tools during Infant Chest Radiography. Int J Pediatr 2016; 4(4): 1637-42.

#### \*Corresponding Author:

Mansour Zabihzadeh, PhD, Department of Medical Physics, School of Medicine, Ahvaz Jundishapur University of Medical Sciences, Golestan Blvd., Ahvaz 61357-33118, Iran.

Email: manzabih@gmail.com

Received date: Jan 17, 2016; Accepted date: Mar 22, 2016

## 1- INTRODUCTION

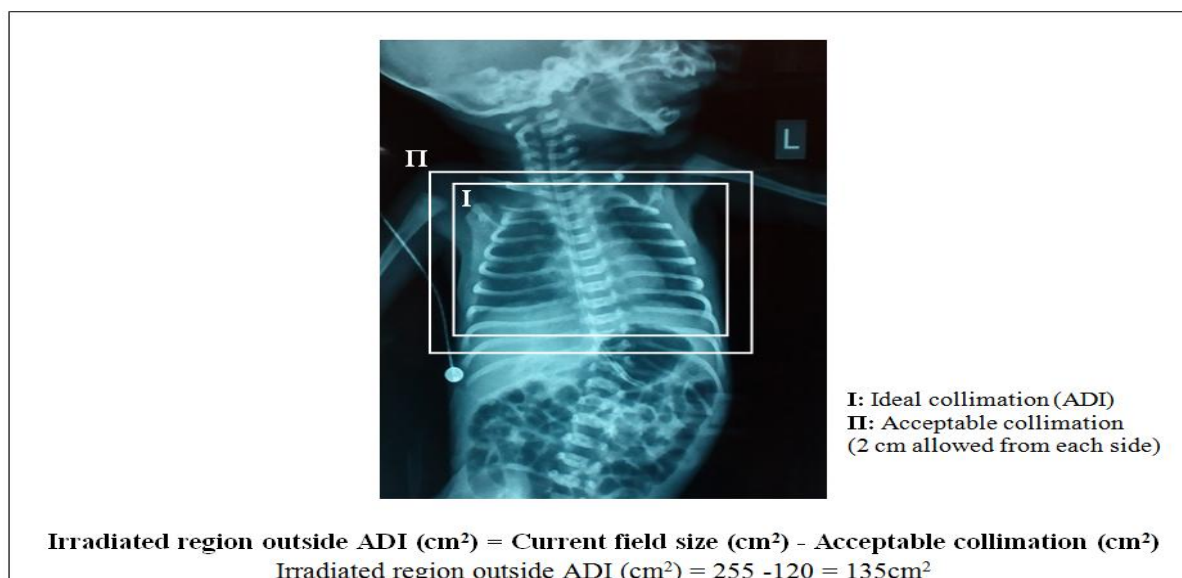
Ionizing radiations have established carcinogenesis (1, 2). Infants are particularly sensitive to the radiation effects and susceptible to radiation-induced cancers such as childhood leukemia (3, 4). It is declared that the sensitivity of infants to radiation carcinogenesis is as much as 10 times than in adults (3). This is due to the high mitotic division rate of their cells and their long life expectancy, that allow a greater period for the potential expression of radiation induced effects (3-5). The increasing risk of childhood acute lymphocytic leukemia from plain film studies have been reported by Willis and Slavis (2005) (6). Radiography of the chest is one of the most common and more frequent X-ray exams ordered, especially in infants (7). It is estimated that 68 million chest radiographs are performed annually in the United States (8) and its frequency is steadily continues to increase (9). Given the very short distance between the primary radiation field and radiosensitive organs such as the gonads, colon, and thyroid gland during infant chest radiographs, it is essential that when imaging infants and other young children the dose is kept as low as reasonably achievable (ALARA) and all applicable radiation dose reduction methods be employ. The use of shielding tools and X-ray beam collimator has extensively been advocated during radiological procedures (2, 10-12). The absorbed radiation dose can be reduced as much as 99.4% following to use of (1 mm) lead shield (13). Collimating the primary beam to the area of diagnostic interest (ADI) is important for patient dose and image quality reasons (2). Collimation reduces the overall integral dose to the patient and minimizes the radiation risks. Improving image quality by reducing scatter radiation is an added benefit when using beam collimator (2, 14). Although the

effectiveness of shielding and X-ray beam collimation at reducing radiation exposure has been well known, previous investigations (10, 15-17) have established low rates of adherence to these protection measures. The aim of this study was to address the use of X-ray beam collimator and shielding tools during infant chest radiography in four major hospitals of Khuzestan province, South West of Iran.

## 2- MATERIAL AND METHODS

This is a retrospective provincial study in the South West of Iran. After approval, we investigated the radiographic film libraries of four major hospitals of Khuzestan-Iran to identify eligible infants less than 12 months old who underwent chest radiography (anteroposterior [AP] view) during 1 October 2015 and 31 December 2015. The investigated images had digital format at two hospitals, analog format at one hospital and both formats at one another hospital. A total number of 371 radiographs were obtained of which, 23 (6%) radiographs were excluded due to chest/abdomen X-ray ordering. Images were reviewed to assessment the presence of silver lining as evidence of collimation. According to protocol reported by Debess et al. (2015) (17), correct collimation of two centimeters on all sides was recommended. For each radiograph the area between current and acceptable collimation was calculated. For digital images measurements was performed using an exact electronic ruler available at work station monitors and for analogue images, calculations were manually carried out using a physical ruler. Example of measurements and calculations is shown in (Figure.1).

Forty-one radiographers were deeply interviewed to monitor the actual use of shielding and the main reasons for not using it. All of them were asked to participate in the study. The refusal rate was 3 (7%) cases.



**Fig.1:** An Example for calculating the irradiated region outside ADI of infant underwent chest radiography

### 2-1. Ethical considerations

This study was supported financially by Student Research Committee of Ahvaz Jundishapur University of Medical Sciences (ID number: 93s.90), Ahvaz-Iran. This committee also acted as an institutional research committee and approved the concept of this study.

### 2-2. Statistics analysis

The SPSS (Version 15) software was used as statistical tools (IBM Corporation, New York, United States of America) to analysis the data. P-value < 0.05 was considered statistically significant.

### 3- RESULTS

Of 348 radiographs evaluated only 54 (15.5%) radiographs [33(61%) analogues and 21(39%) digital images] have satisfactory collimation.

The total mean ADI and irradiated region outside ADI for each radiograph was estimated 171 and 86 cm<sup>2</sup>, respectively. The irradiated region outside the ADI was significantly larger in digital than in analogue images (mean 103 cm<sup>2</sup> vs. 54 cm<sup>2</sup>; P-value<0.05) (Table.1). It is estimated that the abdomen and pelvis were unnecessarily irradiated in 63% and 18% of the images, respectively. Concerning the use of shielding tools, 5 % and 18.5 % of the radiographers used shielding tools regularly and occasionally, respectively while 76.5 % of them never used any shielding tools. The time consuming and lower radiation dose associated with infant chest X-rays were the main reasons discussed by radiographers for not using of shields in infant.

**Table 1:** Beam collimation at 117 analogue and 231 digital infant chest radiographs

Beam collimation	No. of radiographs	No. of radiographs with adequately collimation	No. of radiographs with large collimation	Mean ADI for each radiograph (cm <sup>2</sup> )	Mean irradiated field outside ADI for each radiograph (cm <sup>2</sup> ) (Min-Max)*
Digital	231	21	210	172	103 (28-228)**
Analogue	117	33	84	168	54 (22-118)**
Total	348	54	294	171	84 (22-228)

\* For radiographs with large collimation; \*\* P-value < 0.05.

#### 4- DISCUSSION

A study published in Radiologic Technology in 2013 by Hawking and Sharp (18) states that "applying additional shielding to appropriately collimated chest radiographs could significantly reduce scatter radiation and therefore the overall dose to young children". The extra confirmation on the use of shielding tools during infant chest X-rays is that collimation does not provide complete protection against scatter radiation to the regions outside ADI and shielding is necessary to be used in conjunction with collimation to reduce scatter radiation as much as possible (5). Our results showed that 76.5 % of the radiographers never used any shielding tools. Also, it was found that only 2 % (7 of 348) of the images had evidence of shielding. These results are in good agreement with the previous literatures about the use of shielding tools during computed tomography (15), general radiography (19), dental radiography (20) and pediatric pelvic radiography (21). Our group in 2015 conducted an extensive systematic review in term of radiation protection principle observance in diagnostic X-ray departments in Iran and found that the status of radiosensitive organ shielding was concerning as it has not been altered significantly between 1997 until 2015 (22). It seems that inadequate shielding in diagnostic radiology may be a global problem and reasons for not using shield should be deeply investigated. However in our study the time consuming and lower radiation dose associated with infant chest X-rays were the main reasons discussed by radiographers for not using shields in infant radiographs. In one another study the increasing time of examination and embarrassing to ask the patient to use the shields were proposed as reasons for not using gonadal shield (23). It is pertinent here to mention that although the mean absorbed radiation dose associated with a

singular chest X-ray for individual infant is very low ( $0.051 \pm 0.04$  mGy) (24), but its cumulative dose and following stochastic risks should not be underestimated due to its wide frequency. Moreover, an uncooperative mobile infant may lead to repeat examination being required, that is a common occurrence. Children with chronic diseases receive multiple X-ray exposures (5). So their cumulative dose may be significant owing to lack or inadequate shielding. Thirty three continually chest X-ray in infants at intensive care unit over a short period were reported (4). In these cases due to very short distance between the primary radiation field and radiosensitive organs, the entire colon and pelvis should be adequately shielded.

Collimating the primary beam to the ADI is one of the aspects of optimizing patients dose and image quality (14). However poor collimation has been identified as the greatest source of unnecessary integral dose to patients in diagnostic radiology (16). The results of this study revealed that of 348 radiographs evaluated, only 54 (15.5%) radiographs had satisfactory collimation. In similar study, Debess et al. (2015) (17) reported that 76 to 90% of the chest radiographs had large collimations than acceptable. Okoye and his colleagues (2013) (24) estimated that the effective radiation dose to the thyroid gland and gonads due to chest radiographs in individual infants under the age of one year was  $0.222 \pm 0.02$  and  $0.225 \pm 0.02$  mGy, respectively that are not in the range of tolerance limits recommended by the National Radiological Protection Board (NRPB). The poor radiation protection and inadequate collimation discussed as reasons for such these extra doses.

The large collimation poses two fold problems of increasing patient exposure owing to primary and scattered radiation and deteriorated image quality. Our results estimated that the colon and gonad as

radiosensitive organs were included in the primary beam in 63% and 18% of the images, respectively while they were not interested. Thyroid gland is among the radiosensitive organs that unfortunately owing to located at conjunction to the radiation field during infant chest X-rays, almost inadvertently exposed to ionizing radiation. So, referring physicians, should reduce ordering unnecessary chest X-rays in infants as much as possible. Zabihzadeh and Karami (2015) deemed that unnecessary X-ray exams are a global challenge in radiology. They highlighted that at least 25% of the radiology examinations are unnecessary and can be eliminated without reduce patient's benefits (25). Our results also found that collimation was significantly larger in digital than in analogue images. These results are similar to results reported by Zetterberg and Espeland (2014) (10) and reinforce the finding that transition from analogue to digital radiography reduced motivations toward proper collimation. The results of this study are commensurate with the previous literatures and emphasized that radiosensitive organs are at risk and following safety guideline urgently required to reduce radiation exposure as much as possible. Radiographers should make considerable effort to apply protection measures that are effective and easy to use. Formation a radiation protection team comprising: radiologists, radiographers and health physics authorities, can assist in implementation protection measures such as shielding and X-ray beam collimation.

#### 4-1. Limitations

Unavailability of images (especially analogue images) from previous months was the main limitation of the current study.

#### 5- CONCLUSION

Infants in hospitals investigated are receiving unnecessarily radiation doses

due to inadequate shielding associated with large collimation. Adherence to safety guideline urgently recommended especially for infant radiography.

**6- CONFLICT OF INTEREST:** The authors have no conflicts of interest to declare.

#### 7- REFERENCES

1. Zabihzadeh M, Karami V. Current status of the fetography: Preventing of the future radiation induced cancer. *Iran J Cancer Prev.* 2016 (In press).
2. Dowd SB, Tilson ER. *Practical radiation protection and applied radiobiology.* 2nd ed. Philadelphia, PA: Saunders: WB Saunders; 1999.
3. Hohl C, Wildberger J, Süß C, Thomas C, Mühlenbruch G, Schmidt T, et al. Radiation dose reduction to breast and thyroid during MDCT: effectiveness of an in-plane bismuth shield. *Acta Radiologica* 2006;47(6):562-67.
4. De Azevedo ACP, Osibote AO, Boechat MCB. Survey of doses and frequency of X-ray examinations on children at the intensive care unit of a large reference pediatric hospital. *Applied radiation and isotopes* 2006;64(12):1637-42.
5. Culp MP, Barba JR, Jackowski MB. Shield Placement: Effect on Exposure. *Radiologic technology* 2014;85(4):369-76.
6. Willis C, Slavis T. The ALARA concept in pediatric CR and DR: dose reduction in pediatric radiographic exams-a white paper conference executive summary. *AJR Am J Roentgenol* 2005;184(2):373-74.
7. Jensen L, Meyer C. Reducing errors in portable chest radiography. *APPLIED RADIOLOGY.* 2015.p. 7-15.
8. Hobbs DL. Chest radiography for radiologic technologists. *Radiologic technology* 2007;78(6):494-516.
9. Tigges S, Roberts DL, Vydareny KH, Schulman DA. Routine Chest Radiography in a Primary Care Setting 1. *Radiology* 2004;233(2):575-78.
10. Zetterberg L, Espeland A. Lumbar spine radiography—poor collimation practices after implementation of digital technology. *The British journal of radiology* 2014;84 (2011):566-69.
11. Engel-Hills P. Radiation protection in medical imaging. *Radiography* 2006;12(2):153-60.

12. Bailey E, Anderson V. Syllabus on Radiography Radiation Protection. Sacramento, State of California 1995, pp 35-6.
13. Winfeld M, Strubel N, Pinkney L, Lala S, Milla S, Babb J, et al. Relative distribution of pertinent findings on portable neonatal abdominal radiographs: can we shield the gonads? *Pediatric radiology* 2013;43(10):1295-1302.
14. Bomer J, Wiersma-Deijl L, Holscher H. Electronic collimation and radiation protection in paediatric digital radiography: revival of the silver lining. *Insights into imaging* 2013;4(5):723-27.
15. Karami V, Zabihzadeh M, Gholami M. Gonad shielding for patients undergoing conventional radiological examinations: Is there cause for concern? *Jentashapir J Health Res* 2015 (In press).
16. Okeji MC, Anakwue AM, Agwuna K. Radiation exposure from diagnostic radiography: an assessment of X-ray beam collimation practice in some Nigerian Hospitals. *Internet Journal of Medical Update-EJOURNAL* 2010; 5(2):31-33. Available at: <http://www.ajol.info/index.php/ijmu/article/view/56160>.
17. Debess J, Johnsen K, Vejle Sørensen K, Thomsen H, Aalborg ØD, Viborg D. Digital chest radiography: collimation and dose reduction. *ECR 2015: European society of radiology*; 2015.p. 1-13.
18. Hawking NG, Sharp TD. Decreasing radiation exposure on pediatric portable chest radiographs. *Radiologic technology* 2012;85(1):9-16.
19. Behroozi H, Tahmasebi M, Mohebifar B. Evaluation of the Prevalence of Shielding in Patients Undergoing Conventional Radiological Procedures (1 Work Shift-1 X-ray Room). *Journal of patient safety* 2015 (In press).
20. GhazikhanlouSani K, Eskandarlou A. Evaluation of radiation protection principles observance in Iranian dental schools. *Journal of Dental Medicine* 2009;22(3):125-31.
21. Warlow T, Walker-Birch P, Cosson P. Gonad shielding in paediatric pelvic radiography: Effectiveness and practice. *Radiography* 2014;20(3):178-82.
22. Karami V, Zabihzadeh M. Survey of Radiation Protection in diagnostic X-Ray Imaging departments in Iran: A Systematic Review of Published Articles. *J Maz Uni Med Sci*. 2016 (In Press).
23. Strandén E, Andersen D, Bergwitz-Larsen E, Eriksen J, Hydal J. Main factors influencing the use of scrotum shields during X-ray examinations in major hospitals in Norway and Denmark. *European Journal of Radiography* 2009;1(1):7-11.
24. Okoye PC, Avwiri GO. Optimisation of absorbed dose in chest X-rays of paediatric patients at braithwaite memorial specialist hospital, Port Harcourt. *Am J Sci Ind Res* 2013;4(4):349-58.
25. Zabihzadeh M, Karami V. The challenges of unnecessary radiological procedures. *Hong Kong Journal of Radiology*. 2016 (In press).