

Evaluation of the Prevalence and Utility of Gonad Shielding in Pediatrics Undergoing Pelvic X-Ray

Vahid Karami¹, *Mansour Zabihzadeh^{2,3}, Nasim Shams⁴, Saman Sarikhani⁵

¹Department of Medical Physics, School of Medicine, Ahvaz Jundishapur University of Medical Sciences, Ahvaz, Iran. ²Department of Medical Physics, School of Medicine, Student Research Committee, Ahvaz Jundishapur University of Medical Sciences, Ahvaz, Iran. ³Department of Clinical Oncology, Golestan Hospital, Ahvaz Jundishapur University of Medical Sciences, Ahvaz, Iran. ⁴Department of Oral and Maxillofacial Radiology, School of Dentistry, Ahvaz Jundishapur University of Medical Sciences, Ahvaz, Iran. ⁵Department of Radiology, School of Medicine, Ahvaz Jundishapur University of Medical Sciences, Ahvaz, Iran.

Abstract

Background: Gonad shielding has been recommended during pelvic x-rays since the 1950s. The popular method of gonad shielding is placement a lead shield in the midline of the pelvis. The aim of this study was to evaluate the prevalence and utility of gonad shielding in pediatrics undergoing pelvic x-rays.

Materials and Methods

Following study approval, we retrospectively retrieved data from the digital image library of ten radiology departments of Khuzestan province-Iran to identify pediatric patients who underwent pelvic x-ray (anteriorposterior [AP] view). All the images were reviewed for the probable evidence of gonad shield. If there was evidence of shielding, the accuracy positioning of the shield was also investigated by a single assistant radiologist.

Results

In all 1745 pelvic x-rays (942 girls and 803 boys) were identified of which the shield was present in 51 (5.41%) radiographs of girls and 132 (16.43%) radiographs of boys. When a shield was present; the shields has adequate positioning only in 8 (15.68%) radiographs in girls and 59 radiographs in boys. Inaccurate placement and absence of gonad shields were more common in girls than the boys. Due to the shield has concealed the anatomical criteria of the pelvis, retakes of the examination was required in 11 (21.56%) radiographs of girls and 14 (10.6%) radiographs of boys.

Conclusion

The current methods of gonad shielding in girls pelvic x-ray was not effective nor is justifiable. We no longer advocate of gonad shielding during girls pelvic x-ray. However in boys it is controversial and depends on the skill and effort of radiographers.

Key Words: Gonad shielding, Pediatrics, Pelvic X-ray, Radiation protection.

*Please cite this article as: Karami V, Zabihzadeh M, Shams N, Sarikhani S. Evaluation of the Prevalence and Utility of Gonad Shielding in Pediatrics Undergoing Pelvic X-Ray. Int J Pediatr 2016; 4(11): 3735-3740. DOI: [10.22038/ijp.2016.7589](https://doi.org/10.22038/ijp.2016.7589)

*Corresponding Author:

Mansour Zabihzadeh, PhD, Assistant Professor, Department of Medical Physics, School of Medicine, Ahvaz Jundishapur University of Medical Sciences, Golestan Blvd., Ahvaz 61357-33118, Iran.

Email: manzabih@gmail.com

Received date Aug, 23, 2016; Accepted date Sep, 22, 2016

1- INTRODUCTION

The international commission on radiological protection (ICRP) recommended that the gonads in the pelvic region are highly sensitive to radiation and should be shielded when, of necessity, they are directly in the primary beam or within 5 cm of it, unless such shielding excludes or degrades diagnostic information of the image (1). Protecting the gonads of ionizing radiation is significant; data are available that x-rays can result in direct effects on the gonads in both the somatic and genetic forms (2-4).

Pediatrics merit particular attention from the radiation protection compare to the adults for several reasons: pediatrics have rapidly dividing cells in which repair of mutations due to radiation exposure could not be easily occur (5-7). Moreover, the long life time expectancy of pediatrics allow more time to manifest radiation detriment effects (6, 8). It is believed that the risk of radiation induced cancer in pediatrics are about 10 times more than in adults received identical dose of ionizing radiation (8-10). Therefore it is essential that when medical imaging the radiation dose kept as low as reasonably achievable (ALARA) and follow a safety guideline by which to protect patients from the potential harm (11-16).

Gonad shielding has been recommended for patients undergoing pelvic x-ray since 1950s (3, 17-19). The significant gonad dose reduction of 95% for the boys and 50% for the girls has been reported following adequate gonad shielding (20, 21). Gonad shields were traditionally placed in the midline of the pelvis, on the scrotum region for the males and on the true pelvis (basin pelvis) for the girls. According to the protocol (21, 22), gonad shield should completely covered the scrotum region of the boys and the true pelvis of the girls as such shielding does not compromise diagnostic information of the image. Due to the exteriorize position of the testes,

shielding may be satisfactory. In contrast, due to the ovaries cannot be easily located using the external anatomical landmarks; their shielding is frequently suboptimal (23). Liakos et al. (23) conducted a retrospective study on 62 pelvic x-rays of females and reported that 61 (98%) of which had incorrect positioning of the shield. However appropriate shielding the gonads during pelvic x-ray examinations has been recommended in some literatures (17). The aim of this study was to contribute to the evidence on the prevalence of gonad shielding and to determine whether gonad shielding is an effective method to decrease the radiation exposure to the gonads in pediatrics referred for pelvic x-ray.

2- MATERIALS AND METHODS

Following study approval by the University Ethics Committee, We retrospectively retrieved data from the digital image library of ten x-ray departments at Khuzestan province to identify pediatric under 15 years old who underwent pelvic x-ray (anteriorposterior-AP view) during 1 January 2016 to 1 June 2016. All the images were reviewed for the probable evidence of gonad shield. If there was evidence of shielding, the accuracy positioning of the shield was also investigated. For consistent, all images were reviewed by a single assistant radiologist. According to the protocol (2, 18, 24), gonad shielding is perfect if completely concealed the true pelvic of the girls and the scrotum region of the boys, without concealing pelvic anatomy. Positioning of the shields in boys and girls was compared by independent t-test.

3-RESULTS

The images database search result in 1745 pelvic x-rays (942 girls and 803 boys) of 1670 patients (895 girls and 775 boys) of which the shield was present in 51 (5.41%) radiographs of girls and 132 (16.43%) radiographs of boys and was completely

omitted in 1562 (89.5%) radiographs. For girls, of 51 radiographs which have evidences of shielding, the shields has adequate positioning in 8 (15.68%) radiographs and in the remaining 43 radiographs, the shield has small size in 2 (3.92%) radiographs, too big in 6 (11.76%) radiographs and in 35 (68.62%) radiographs, the shield had incorrect placement. In comparison, for boys, of 132 shielded radiographs, the shield has accurate positioning in 59 (44.69%) radiographs, partially protected the testes in 15 (11.36%) radiographs, partially

concealed the bony structures in 46 (34.84%) radiographs and substantially in 12 (9.09%) radiographs. When images were reviewed, we found that retakes of the examination was required in 11 (21.56%) radiographs of girls and 14 (10.6%) radiographs of boys; due to the shield has concealed the diagnostically criteria of the pelvis (**Figure.1**). In all, gonads were irradiated with ionizing radiation in 1629 (93.35%) radiographs due to absence or inaccurate gonad shield placement which were more common in girls than in boys ($P<0.05$).

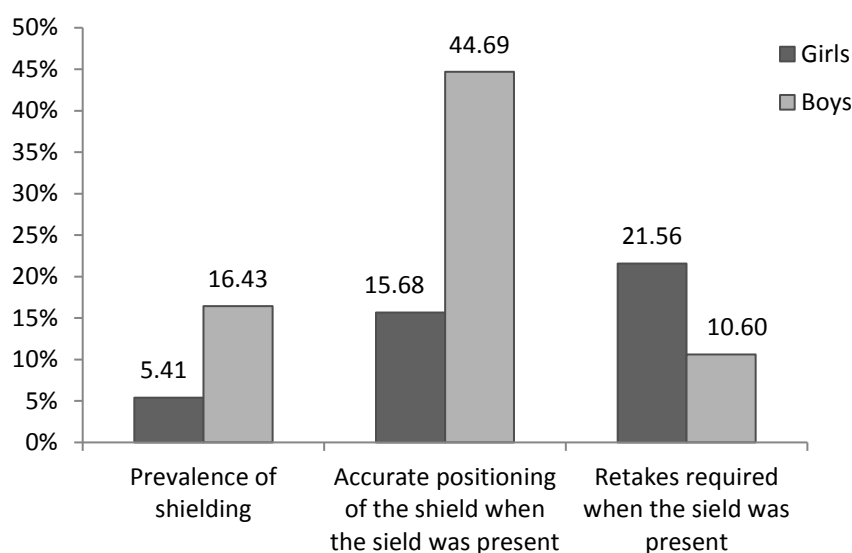


Fig.1: The prevalence, accurate positioning of the shield and repeat rate of gonad shielding in girl and boy subjects

4- DISCUSSION

In this study we demonstrated that gonad shielding is not an effective method to address ALARA in girls undergoing pelvic x-ray. Our data showed that of 51 images where gonad shields was present; only 8 (15.68%) images were likely to provide protection to the gonad without concealing pelvis anatomy. In comparison, of 132 shielded radiographs in boys, the shield has accurate positioning in 59 (44.69%) radiographs. Also due to mal-positioning of the shield, retakes of the

examination were required in 11 (21.56%) radiographs of girls and 14 (10.6%) radiographs of boys. Our results are in good agreement with ones reported by Frantzen et al. (2012) (25) and Warlow et al. (2014) (3) in which the radiographs had incorrectly positioning of the shield in 91%, 94% in girls and 66% and 41% in boys, respectively. In a similar study Frantzen et al. (2012) (25) reported because an important anatomical landmark was obscured, retakes of the exposure were required in 28% of girls and 4.14% of boy radiographs. Our results are comparable

with previous studies (**Figure-2**). It seems that accurate positioning the shield is a problematic issue during pelvic x-ray, especially in obese patients and/or when clothe is in place (21). Another challenge is that the ovaries have a misleading anatomy with variable positions in the pelvis (26-28).

A study by Bardo et al. (2009) (27) revealed that the ovaries are located far from the mid-sagittal line and almost always positioned laterally in the pelvis; hence complete ovaries protection needs shielding the entire of pelvis and clear that it is not consistent in practice. In other words, despite accurate positioning of gonad shields in 8 (15.68%) radiographs, yet it is uncertain that the shield has provided complete protection to the ovaries.

It seems that gonad shielding during pediatric girls pelvic x-ray may not be justifiable. Despite of 132 shielded radiographs in boys, the shield has concealed the anatomical landmarks in 46 (34.84%) radiographs, but retakes were not

required in 32 (70%) of them due to the shield has partially concealed the bony structures. Inaccurate gonad shield placement in boys mainly originates from the lack of confidence or skills of radiographers that can be improved by better practical training. According to the results of this study and currently published literatures (3, 23, 25, 29-32), gonad shields were frequently incorrectly placed, especially in girls. Inaccurate positioning of the shield may obscure anatomy of interest and result in increased radiation exposure to the patients followed by repeat of the examination (3).

Considering recommendation of the ICRP publication 103 (33) that state “any decision that alters the radiation exposure situation should do more good than harm”, we no longer advocate of gonad shielding during girls pelvic x-ray. However for boys its efficacy depends on the skill and effort of radiographers in accuracy gonad shield placement that lies in implementation continually on the job practical training.

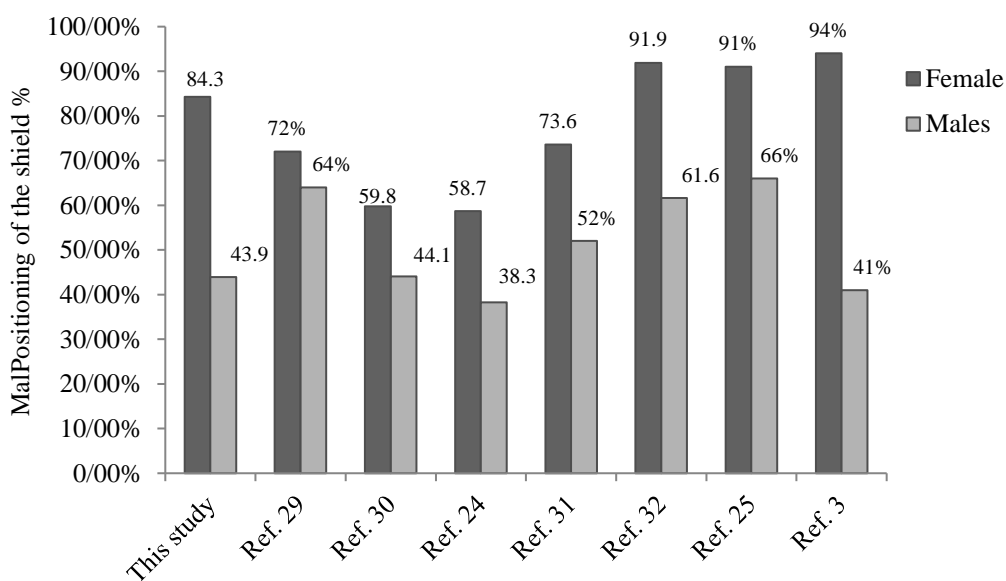


Fig.2: Inaccurate positioning of the gonad shield in male and female subjects according to the various studies

4-1. Limitations of the study

The main limitation of this study was retrospective analysis of data in which it may not include the images that may have been rejected and repeated by the radiographer due to mal-positioning of the shield in the initial image (3). Furthermore, the age of patients was not recorded for some x-rays that were excluded from the study.

5. CONCLUSION

The current methods of gonad shielding in girls pelvic x-ray is not effective nor is justifiable. However in boys it is controversial and depends on the skill and effort of radiographers.

6- CONFLICT OF INTEREST

The authors have no conflicts of interest to declare.

7- ACKNOWLEDGMENT

This research project has been financially supported by Ahvaz Jundishapur University of medical sciences, Ahvaz, Iran.

8- REFERENCES

1. International Commission on Radiological Protection (ICRP). Protection of the patient in diagnostic radiology, ICRP Publication 34. *Ann ICRP* 1982; 9: 22-40.
2. Sikand M, Stinchcombe S, Livesley P. Study on the use of gonadal protection shields during paediatric pelvic X-rays. *Annals of the Royal College of Surgeons of England*. 2003;85(6):422-25.
3. Warlow T, Walker-Birch P, Cosson P. Gonad shielding in paediatric pelvic radiography: Effectiveness and practice. *Radiography*. 2014;20(3):178-82.
4. Winfeld M, Strubel N, Pinkney L, Lala S, Milla S, Babb J, et al. Relative distribution of pertinent findings on portable neonatal abdominal radiographs: can we shield the gonads? *Pediatric radiology*. 2013;43(10):1295-302.
5. Toossi MTB, Malekzadeh M. Radiation dose to newborns in neonatal intensive care units. *Iranian Journal of Radiology*. 2012;9(3):145-9.
6. Voress M. The increasing use of CT and its risks. *Radiologic technology*. 2007;79(2):186-90.
7. Karami V, Zabihzadeh M, Danyaei A, Shams N. Efficacy of Increasing Focus to Film Distance (FFD) for Patient's Dose and Image Quality in Pediatric Chest Radiography. *Int J Pediatr*. 2016;4(9):3421-29.
8. Karami V, Zabihzadeh M, Gilavand A, Shams N. Survey of the Use of X-ray Beam Collimator and Shielding Tools during Infant Chest Radiography. *International Journal of Pediatrics*. 2016;4(4):1637-42.
9. Karami V, Zabihzadeh M, Gholami M, Shams N, Fazeli-Nezhad Z. Dose Reduction to the Thyroid Gland in Pediatric Chest Radiography. *International Journal of Pediatrics*. 2016; 4(5):1795-802.
10. Strauss KJ, Kaste SC. The ALARA (As Low As Reasonably Achievable) Concept in Pediatric Interventional and Fluoroscopic Imaging: Striving to Keep Radiation Doses as Low as Possible during Fluoroscopy of Pediatric Patients—A White Paper Executive Summary 1. *Radiology*. 2006;240(3):621-2.
11. Zabihzadeh M, Karami V. Current status of the fetography: Preventing of the future radiation induced cancer. *Iran J Cancer Prev*. 2016. Available from: <http://ijcancerprevention.com/en/articles/5209.html>. Accessed Oct 2016.
12. Zabihzadeh M, Karami V. The challenge of unnecessary radiological procedures. *Hong Kong Journal of Radiology*. 2016;19(3):23-4.
13. Karami V, Zabihzadeh M. Radiation Protection in Diagnostic X-Ray Imaging Departments in Iran: A Systematic Review of Published Articles. *J Mazandaran Univ Med Sci*. 2016 26(135):175-88.
14. Karami V, Zabihzadeh M. Prevalence of radiosensitive organ shielding in patients undergoing computed tomography examinations: an observational service audit in Ahvaz, Iran. *Asian Biomed journal*. 2015;9(6):771-5.

15. Karami V, Zabihzadeh M. Beam collimation during lumbar spine radiography: A retrospective study *J Biomed Phys Eng.* 2016;6(3):1-6.
16. Zabihzadeh M, Karami V. Poor collimation in digital radiology: A growing concern. *Internet Journal of Medical Update-EJOURNAL.* 2016;11(9):29-30.
17. Doolan A, Brennan PC, Rainford LA, Healy J. Gonad protection for the antero-posterior projection of the pelvis in diagnostic radiography in Dublin hospitals. *Radiography.* 2004;10(1):15-21.
18. Gul A, Zafar M, Maffulli N. Gonadal shields in pelvic radiographs in pediatric patients. *Bulletin-hospital for joint diseases New York.* 2005;63(1/2):13-4.
19. MacKay M, Hancy C, Crowe A, D'Rozario R, Ng C. Attitudes of medical imaging technologists on use of gonad shielding in general radiography. *The Radiographer.* 2012;59(2):35-9.
20. Raissaki MT. Pediatric radiation protection. *European radiology supplements.* 2004;14(1):74-83.
21. Karami V, Zabihzadeh M, Gholami M. Gonad shielding for patients undergoing conventional radiological examinations: Is there cause for concern? *Jentashapir J Health Res.* 2016;7(2):1-4.
22. Silva C, Silva P, Ventura SMR, editors. The use and relevance of gonad protection shields in children during hips radiography. *I Congresso Internacional da Saúde Gaia-Porto; 2010: Instituto Politécnico do Porto. Escola Superior de Tecnologia da Saúde do Porto-Politema.*
23. Liakos P, Schoenecker PL, Lyons D, Gordon JE. Evaluation of the efficacy of pelvic shielding in preadolescent girls. *Journal of Pediatric Orthopaedics.* 2001;21(4):433-5.
24. Wainwright A. Shielding reproductive organs of orthopaedic patients during pelvic radiography. *Annals of the Royal College of Surgeons of England.* 2000;82(5):318-21.
25. Frantzen MJ, Robben S, Postma AA, Zoetelief J, Wildberger JE, Kemerink GJ. Gonad shielding in paediatric pelvic radiography: disadvantages prevail over benefit. *Insights into imaging.* 2012;3(1):23-32.
26. Fawcett S, Gomez A, Barter S, Ditchfield M, Set P. More harm than good? The anatomy of misguided shielding of the ovaries. *The British Journal of Radiology.* 2012;82(2012): 442-47
27. Bardo DM, Black M, Schenk K, Zaritzky MF. Location of the ovaries in girls from newborn to 18 years of age: reconsidering ovarian shielding. *Pediatric radiology.* 2009;39(3):253-9.
28. Goodman TR, Amurao M. Medical imaging radiation safety for the female patient: rationale and implementation. *Radiographics.* 2012;32(6):1829-37.
29. McCarty M, Waugh R, McCallum H, Montgomery RJ, Aszkenasy OM. Paediatric pelvic imaging: improvement in gonad shield placement by multidisciplinary audit. *Pediatric radiology.* 2001;31(9):646-9.
30. Kenny N, Hill J. Gonad protection in young orthopaedic patients. *BMJ.* 1992;304(6839):1411-3.
31. Fawcett SL, Barter SJ. The use of gonad shielding in paediatric hip and pelvis radiographs. *The British Journal of Radiology.* 2009 2009/05/01;82(977):363-70.
32. Gürsu S, Gürsu T, Camurcu Y, Yıldırım T, Gürsu A, Şahin V. [Efficacy of gonadal shielding in pediatric pelvis X-rays]. *Eklem hastalıkları ve cerrahisi= Joint diseases & related surgery.* 2012;24(2):87-90.
33. Recommendations of the International Commission on Radiological Protection. ICRP publication 103. *Ann ICRP* 2007;37(2-4).