

Evaluation of Dento-maxillofacial Changes in Pediatric β -Thalassemia Major Patients in Northern Iran

Katayoun Salem¹, *Maedeh Aminian², Samad Seyyed Khamesi³

¹Assistant Professor, Department of Pediatric Dentistry, Dental Faculty, Azad Dental School, Tehran, Iran. ²Post Graduate, Dental Student's Research Committee, Dental Faculty, Isfahan University of Medical Science, Isfahan, Iran. ³Post Graduate Student, Department of Oral and Maxillofacial Surgery, Dental Faculty, Islamic Azad University, Isfahan (Khorasgan) branch, Isfahan, Iran.

Abstract

Background

Thalassemia is a group of congenital disorders which is characterized by a deficient synthesis of alpha or beta globulin chains in hemoglobin molecules. Due to the problems resulting from changes in face, especially in dento-maxillary regions, such patients require special attention regarding oral health. Thus in this study, we aimed to assess the dento-maxillofacial changes in Beta-thalassemia major (BTM) children and Adolescent patients in Northern Iran.

Materials and Methods

BTM subjects aged 2-15 years and their systemically healthy controls were evaluated in this case-control study. Dento-maxillary changes (spacing, crowding, Posterior cross bite, open bite, deep bite, overjet), dental occlusion, and facial changes (maxillary protrusion, malar prominence, saddle nose and frontal bossing), were evaluated. Data was analyzed SPSS version 22.0.

Results

There were 66 BTM patients and 66 healthy controls in this study, including 40.9% male and 59.1% females. The average age was 12 ± 3.31 years. Open bite ($P < 0.05$), overjet ($P < 0.05$) and all of the facial abnormalities ($P < 0.05$) observed significantly more frequent in thalassemia patients, but there was no significant difference in dental occlusion status ($P > 0.05$).

Conclusion

With regarding to high prevalence of facial changes of BTM patients (57.6 %), preventive care, education and early dento-maxillofacial evaluation and management is advised.

Key Words: Adolescent, Beta-thalassemia, Children, Iran, Maxillofacial abnormalities.

*Please cite this article as: Salem K, Aminian M, Seyyed Khamesi S. Evaluation of Dento-maxillofacial Changes in Pediatric β -Thalassemia Major Patients in Northern Iran. Int J Pediatr 2017; 5(7): 5219-27. DOI: **10.22038/ijp.2017.22270.1862**

*Corresponding Author:

Maedeh Aminian, Dental Student's Research Committee, Dental Faculty, Isfahan University of Medical Science, Isfahan, Iran. postal code: 81746-73461

E-mail: maedeh_aminian@yahoo.com

Received date: Mar.22, 2017; Accepted date: Apr. 22, 2017

1-INTRODUCTION

The term "thalassemia" is derived from Greek word "Thalassa", which means "sea", due to its high prevalence in the Mediterranean region. Thalassemia refers to a group of hereditary hemolytic anemia with various types and severities, in which the affected individuals are unable to synthesize one or several hemoglobin molecule chains adequately, resulting in the formation of abnormal hemoglobin; leads to the early hemolysis of blood cells and thus microcytic anemia with variable severities (1, 2).

Thalassemia is classified as major (homozygous), minor (heterozygous), and intermediate based on the severity of clinical and hematologic manifestations; it is also classified genetically into Alfa-thalassemia (α -thalassemia) and beta-thalassemia (β -thalassemia) based on the chain affected. β -thalassemia major is the most severe congenital hemolytic anemia and the most common single-gene genetic disorder in the Mediterranean region, the Middle East, Asia and Africa, and is also known as the Cooley's anemia (3-6).

The clinical manifestations usually appear during the first six months of life (5, 6). A yellowish facial appearance, hepatomegaly, splenomegaly and susceptibility to infections are some of the clinical manifestations of the disease. Maxillofacial manifestations mainly consist of bone marrow hyperplasia as a compensatory reaction to anemia, consisting of protrusion of the premaxilla, malar bones and frontal bone, a depressed nasal bridge, hypertelorism and exophthalmos, various degrees of malocclusion, presence of spaces between teeth and open bite or deep bite. Usually the lower jaw is enlarged less than the upper jaw due to its compact cortical plates. Widespread osteoporosis of jaw bones, enlargement of bone marrow spaces, a relatively small maxillary sinus, thinning of lamina Dura and shortening of

tooth roots are some of the possible radiographic signs of these patients (6-8). Thalassemia is the most prevalent genetic condition all over the world; so that over 180 million people (1.67%), carry the thalassemia gene and the probability of a carrier state at birth is 2.4 in 1,000 births. Iran is located on the global thalassemia ring and prevalence of thalassemia relative to the population is the highest all over the world. Its prevalence in Iran is 4-10% and currently, there are about 3 million carriers and 25,000 patients with thalassemia major in Iran. The highest prevalence rate has been reported around the Caspian Sea in the North and the Persian Gulf in the South of Iran (5, 8-10).

Guilan province, North of Iran, is one the 10 most thalassemia populated provinces in Iran. Based on previous studies, the prevalence of thalassemia major is 1 in 16,000 and currently 1,500 affected individuals live in Guilan province (11). The present study aimed to evaluate Dento-maxillofacial changes in children and adolescents with major thalassemia in Rasht city, the Provincial Capital of Guilan province, North of Iran.

2-MATERIALS AND METHODS

In the present case-control study, sixty six 2-15 years old subjects with β -thalassemia major, referring to the thalassemia wards of 3 public hospitals in Rasht city, North of Iran, were evaluate using the census method after obtaining informed written consent forms.

In addition, 66 control subjects were selected and evaluated from school children of Rasht, consisting of the same number of children and adolescents who were matched in relation to age, gender and socio-economic status based on the parents' educational status.

Inclusion criteria were age 2-15 years old, documented beta thalassemia major, and parental acceptance to participate in the

study. The subjects were excluded from the study in the case of having any mental or systemic disorders other than thalassemia.

2-1. Data collection

First, questionnaires were separately prepared for both groups, which consisted of demographic data, the educational level, the possible familial relationship of the parents and data on thalassemia, including the age at diagnosis, history of splenectomy, the number of Desferal (Deferoxamine) injection in each month, the transfusion dates and the intervals between transfusions.

The questionnaires were completed based on the patients' medical files and history, and by interview with the patients or parents by a senior dental student. Then, all the subjects underwent a clinical examination in relation to dento-maxillofacial changes with the use of graduated periodontal probes, disposable dental mirrors, tongue depressors and gloves under natural light, while they were sitting on a chair. The results were recorded in the questionnaires. The following parameters were evaluated:

2-1-1. Dento-maxillary changes

Overjet: The distance between the labial surfaces of lower central incisors and the incisal edges of upper central incisors. An overjet $>2-3$ mm was considered increased overjet.

Overbite: The vertical overlapping of lower central incisors by upper central incisors. An overbite >2 mm was considered deep bite and lack of vertical overlapping of incisors was considered open bite (12).

Spacing: A distance of >1.5 mm between the central and lateral incisors and the maxillary canine was considered spacing.

Crowding: Overlapping of maxillary incisors.

Posterior crossbite: Overlapping of posterior maxillary teeth by posterior mandibular teeth (12).

2-1-2. Facial changes

Presence of Craniofacial bony deformities in the form of maxillary protrusion, frontal protrusion, depression of nasal bridge and prominence of malar bones alone or in combination were graded as facial deformities.

Maxillary protrusion: to evaluate the patients' profile, a line was drawn from the Nasion (N) perpendicular to the hypothetical horizontal line. Maxillary protrusion was determined when this line was posterior to the junction of the upper lip and the nose (12, 13).

2-2. Dental occlusion

Angle's classification was used to evaluate occlusion as follows:

- Class I: The mesio-buccal cusp of the maxillary first molar tooth in the buccal groove of mandibular first molar or the cusp tip of maxillary canine between the mandibular canine and lateral incisor.
- Class II: The mesio-buccal cusp of the maxillary first molar anterior to the buccal groove of mandibular first molar or the cusp tip of maxillary canine between the mandibular canine and lateral incisors.
- Class III: The mesio-buccal cusp of the maxillary first molar posterior to the buccal groove of mandibular first molar or the cusp tip of maxillary canine between the mandibular first and second premolars (14).

In patients under 6 years of age the relationship of deciduous canines was used the canine was considered class I relationship; distal step of the canine and edge-to-edge relationship was considered class II and severe mesial step of the canine in association with incisor cross bite was considered class III relationship (14).

2-3. Data analysis

Data were collected and analyzed using SPSS version 22.0. In order to compare the quantitative variables of the study, first the normal distribution of data was analyzed with the use of Kolmogorov-Smirnov test.

In cases in which data were distributed normally, independent samples t-test was used for the analysis of data; in cases in which data did not exhibit normal distribution, Mann-Whitney test was used.

Chi-squared test and Fisher's exact test were used to compare frequency distributions of the quantitative variables of the study. Statistical significance was set at $P < 0.05$.

3- RESULTS

In the present study, 66 children with thalassemia major and 66 healthy controls were evaluated. The mean ages of the thalassemia group, control group and the whole subjects were 12 ± 3.33 , 12 ± 3.32 and 12 ± 3.31 years old, respectively.

There was a familial relationship between the parents in 10 cases (15.2%) in the thalassemia group, which was higher than (5 cases, 7.6%) that in the control groups; however, the difference was not significant ($P = 0.170$).

Figure.1 presents the frequencies of dento-maxillary changes in the two groups. Of all the dento-maxillary parameters

to predict the sagittal relationship of jaws in future. In this context, the mesial step of evaluated open bite ($P = 0.006$), and overjet ($P = 0.008$) were significantly more frequent in the β -thalassemia major group compared to the control group.

Figure.2 presents the frequencies of facial changes in the two groups. In the subjects in the thalassemia group, the facial changes frequencies were:

- Malar protrusion (31.8%),
- Frontal protrusion (30.3%),
- Maxillary protrusion (24.4%), and
- Saddle nose (19.7%).

There were significant differences in the incidence of each of the facial changes and the overall facial changes between the thalassemia and control groups ($P < 0.001$). The frequencies of dento-maxillary changes in the thalassemia and control groups were 75.8% and 77.3%, respectively, with no significant differences between the two groups ($P = 0.175$).

Figure.3 presents the frequencies of different dental occlusal relationships in the two groups. The majority of the subjects in the thalassemia group were in Angle's Class I classification (80.3%), with no Class III cases in this group. There were no significant differences between the two groups ($P = 0.09$).

The frequencies of maxillary protrusion, overjet and deep bite in the thalassemia group patients with Class II occlusal relationship were significantly higher than those with Class I relationship (**Table.1**).

Based on the results of Mann-Whitney U test, none of the occlusal and craniofacial changes were significantly related with the onset of the disease (**Table.2**).

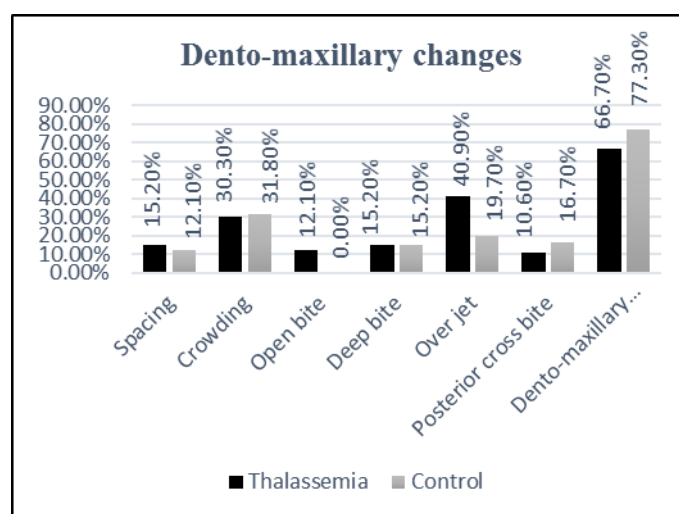


Fig.1: The frequencies of dento-maxillary changes in the thalassaemia and control groups.

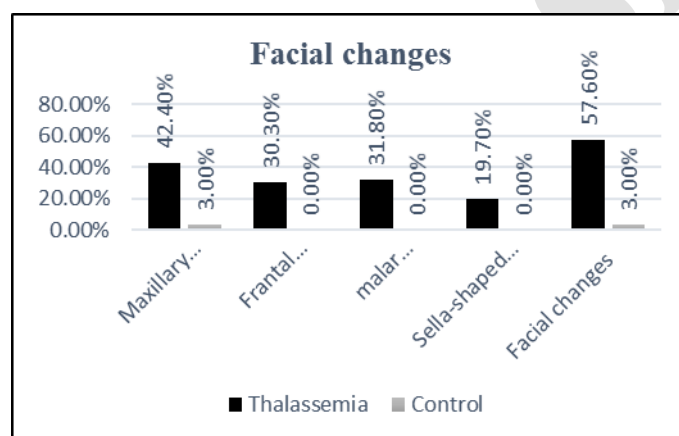


Fig.2: The frequencies of facial changes in the thalassaemia and control groups.

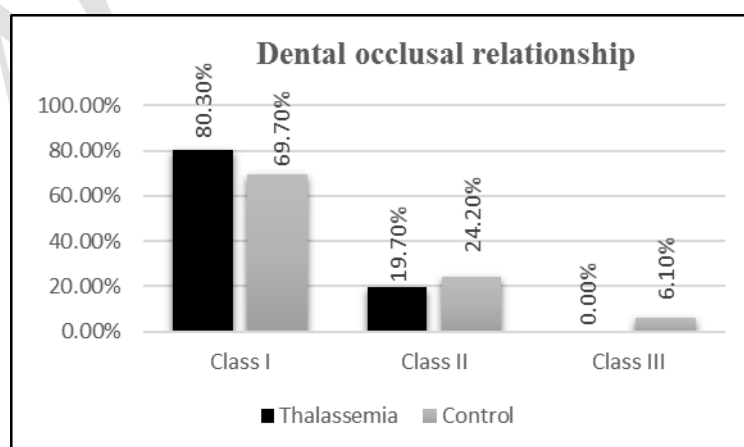


Fig.3: The frequencies of different types of dental occlusal relationship in the thalassaemia and control.

Table-1: The frequencies of dento-maxillary changes and maxillary protrusion in subjects with thalassemia in terms of dental occlusal relationship

Variables		Class I	Class II	P-value
Maxillary protrusion	Yes	2.30%	3.92%	0.001
	No	8.69%	7.7%	
Spacing	Yes	2.13%	1.23%	0.374
	No	8.86%	9.76%	
Crowding	Yes	2.30%	8.30%	0.967
	No	8.69%	2.69%	
Open bite	Yes	1.15%	0%	0.135
	No	9.84%	100%	
Deep bite	Yes	4.9%	5.38%	0.009
	No	6.90%	5.61%	
Overjet	Yes	3.28%	3.92%	0.001
	No	7.71%	7.7%	
Posterior crossbite	Yes	2.13%	0%	0.166
	No	8.86%	100%	

Table-2: The mean age of affliction with thalassemia in children evaluated in terms of the incidence of dento-maxillary and facial changes and different types of dental occlusal relationship

Variables		Number	Mean rank	Mean age at diagnosis (months)	SD	Z-value	P-value
Facial changes	Yes	38	36.79	24.4	33.4	-1.637	0.103
	No	28	36.04	10	6.85		
Dento-maxillary changes	Yes	44	34.48	15.21	31.29	-0.589	0.556
	No	22	31.55	12.59	11.5		
Dentomaxillo-facial changes	Yes	50	34.72	88.2	29.9	-0.919	0.358
	No	16	29.69	25.1	6.99		
Dental occlusal relationship	Class I	53	32.29	17.77	25.78	-1.039	0.299
	Class II	13	38.49	20.46	30.76		

SD: Standard deviation.

4- DISCUSSION

The prevalence of oral changes in thalassemia is higher than that in many other disorders. Studies all over the world have shown a prevalence rate of 45–50% for such manifestations. The most prevalent manifestation of patients with thalassemia major in the head and maxillofacial area are protrusion of the malar bones and the premaxilla, which is due to hyperplasia of bone marrow (8).

In the present study, 75.8% of thalassemia patients exhibited dento-maxillary and facial changes. The prevalence of dento-

maxillary changes were as follows: interdental spacing (15.2%), crowding (30.3%), open bite (12.1%), deep bite (15.2%), overjet (40.9%), and posterior crossbite (10.6%). In this context, there were significant differences between the healthy controls and thalassemia patients only in open bite and overjet.

In addition, all the different types of facial changes, including the malar protrusion (31.8%), frontal protrusion (30.3%), protrusion of the maxilla (24.4%), and saddle nose (19.7%), were significantly more prevalent in the thalassemia group compared to the control group. The facial

bones, especially the facial and maxillary bones, undergo hyperplasia of bone marrow, resulting in bone enlargement, in an attempt to compensate anemia and hypoxia resulting from thalassemia, which is the main factor responsible for dento-maxillary and facial changes in these patients. Maxillary hyperplasia is responsible for the malar protrusion, increased overjet, open bite (a lack of contact between the upper and lower incisors), leads to super-eruption of mandibular incisors, and overbite (open bite or deep bite). Hypoxia resulting from anemia might also result in excessive load on respiratory muscles, leading to deep and forceful inspirations in such patients, which might result in widening of the nostrils and depression of the nasal bridge in the long term (7). In A study by Hashemipour et al, the orofacial manifestations were significant in the following aspects: protrusion of the maxilla, protrusion of the mandible, saddle nose, and protrusion of anterior teeth, posterior malocclusion and the frontal protrusion, consistent with the results of the present study in some cases (8).

In study by Vahedi et al, the following problems were reported: saddle nose (71.8%), maxillary protrusion (55.5%), deep bite (28.2%), open bite (13.6%), spacing of the anterior teeth (23.7%), and a rodent face appearance (30%), which were higher than the frequencies of the present study. Such discrepancy in the results of these two studies might be attributed to a lack of age limit in the study above, in which 50% of the subjects were over 14 years of age, with a higher frequency of facial and oro-maxillary changes (13).

In a study by Shirzaii (15), the prevalence of occlusal discrepancies were as follows: deep bite (22.4%), tooth spacing (15.7%), open bite (3.6%), cross bite (5.7%), crowding (29.5%), and facial changes resulting from β -thalassemia major, consisting of a saddle nose (60.1%),

maxillary protrusion (25.6%), and rodent face appearance (34.8%). The results of the study above are different from those of the present study in relation to the prevalence of open bite and deep bite; however, the other cases are consistent with those of the present study. In that study the age range of the subjects was 2–24 years and there were significant relationships between age and complications such as deep bite, tooth spacing, rodent face appearance and saddle nose (14).

Ali et al, have found that 90% of the subjects exhibited oro-maxillary and facial manifestations, including protrusion of the frontal (54%), and parietal (88%) bones, depressed nasal bridge (70%), maxillary hyperplasia (34%), and tooth spacing (20%), all of which were higher compared to the present study; such a discrepancy between the results of these two studies might be attributed to the lack of age limit in that study. In addition, there was a direct relationship between the disease severity and aging and an indirect relationship between disease severity and early and regular treatment (7).

In the present study, 80.3% of the subjects with thalassemia major exhibited Class I occlusal relationship and 19.7% had Class II occlusal relationship; however, in the control group, 69.7%, 24.2% and 6.1% of the subjects exhibited Class I, Class II and Class III occlusal relationships, with no significant differences between the two groups. In this context, the results of the present study are consistent with those of Shirzaii, Vahedi et al., and Elangovan et al. (15-17).

The dominant occlusal relationship in these subjects was Class I, followed by Class II and Class III, in descending order. A higher rate of Class I occlusal relationship in the present study (80.3%), compared to other studies, might be attributed to the younger age of the subjects, the early diagnosis and treatment

or to the impact of thalassemia on the anterior maxilla (18). The higher frequency of maxillary protrusion, overjet and deep bite in thalassemia patients with Class II occlusal relationship compared to Class I relationship in the present study, confirms the third explanation. In the present study, there was no significant relationship between the incidence of facial and dento-maxillary changes and age at diagnosis, onset of blood transfusion, the blood transfusion intervals (in days), and regular use of Desferal. However, in a study by Vahedi et al. (16), a significant relationship was found between early blood transfusion and decreased thalassemia oral characteristic. One of the factors responsible for such differences might be the patients' age. In the present study, the age range was 2-15 years and in the study by Vahedi et al. (16), the range was less than 7 years to more than 21 years.

The mean age at diagnosis in the groups with and without facial changes, were 24 and 10 months, respectively; however, the difference between the ages at diagnosis was not significant, which might be attributed to the small number of subjects with no facial changes in our study. In addition, the facial manifestations such as depressed nasal bridges and maxillary protrusion will increase by age (15), the lower reported rate may be resulted from narrow age range.

Meanwhile, the frequency of facial changes in the present study was less than that in other studies in Iran, which might be attributed to lower age of studied patients in present study and advances in early diagnosis, treatment and regular follow-up in recent years (8, 13, 15, 17).

4-1. Limitation of study

One of the limitations of this study was a lack of access to all the patients with thalassemia major in Guilan province,

Iran; however, considering the fact that the subjects consisted of the patients who referred to continue their treatment, it might be inferred that subjects with the most severe problems were included in the study. In addition, another limitation was the fact that it was not possible to take patients' radiographs for more detailed evaluations. It is recommended that in future studies maxillofacial changes be evaluated with the use of radiographs.

5- CONCLUSION

In the present study, open bite, overjet and all the other facial changes in the thalassemia group were significantly more frequent than the control group, however the prevalence was lower than former Iranian studies.

6- ACKNOWLEDGEMENT

We appreciate thalassemia wards of Rasht's hospitals and Thalassemic patients and their families for cooperation and thanks Mr. Tavangar for data analysis.

7- REFERENCES

1. Girinath P, Vahanwala SP, Krishnamurthy V, Pagare SS. Evaluation of orofacial manifestations in 50 thalassemic patients: A Clinical Study. *J Indian Acad Oral Med Radiol* 2010; 22(3):126.
2. Arabsolghar M, Mohammadi M, Kaheh A, Norouzifard A, Ahmadzadeh S. Different type of periodontitis and gingivitis in patients with major thalassemia comparing to healthy people. *J Oral Health Oral Epidemiol* 2015; 4(1):24-9.
3. Azami M, Nikpay S, Abangah G, Sayehmiri K. Evaluation of the incidence of splenectomy and frequency of regular iron chelation therapy in patients with thalassemia Major in Iran: a meta-analysis. *Sci J Iran Blood Transfus Organ* 2016; 13(2):146-55.
4. Shamsah MS, Zaidan TF. Oro-facial manifestations, oxidative stress marker and antioxidant in serum and saliva of patients

- with Beta thalassemia major. *JBCD* 2015; 27(2):93-7.
5. Shooriabi M, Zareyee A, Gilavand A, Mansoori B, Keykhaei Dehdezi B. Investigating DMFT Indicator and its Correlation with the amount of Serum Ferritin and Hemoglobin in Students with Beta-thalassemia Major in Ahvaz, South West of Iran. *Int J Pediatr* 2016; 4(3):1519-27.
6. Ajami B, Talebi M, Ebrahimi M. Evaluation of oral and dental health status in major thalassemia patients referred to Dr. Sheikh Hospital in Mashhad in 2002. *J Mashhad Dent Sch.* 2006; 30(1-2): 99-108.
7. Ali SM, Haider SM, Ahmed S, Hassan SG, Jaffry SH. Oral and maxillofacial manifestations in 50 beta-thalassemic patients –a clinical study. *PODJ* 2016; 36(2):179-83.
8. Hashemipour M, Raad M, Ebrahimi MS. Orofacial disformation in thalassemia patients referred to Kerman special disease center in 2007. *Sci J Iran Blood Transfus Organ* 2008; 5(3):185-93.
9. Honarmand M, Amiri-Tehranizade N, Farhad-Mollashahi L. Dental health and dental treatment needs in patients with thalassemia major. *Zahedan J Res Med Sci* 2010; 12(3):34-8.
10. Arabion HR, Farhadpour AR, Fijan S, Mofidi M. Assessment of Oral Hygiene Status, Periodontal Index, and DMFT in the Thalassemia Patients Referring to Shahid Dastgheib Hospital, Shiraz in 2010. *Sadra Med Sci J* 2013; 1(3): 129-38.
11. Noorsalehi E, Mojtabaii SH, Bolookimoghdam K, Orangpour R, Frouhari A. Evaluation of Blood Transfusion and Splenectomy in Thalassemic Patients. *J Guilan Univ Med Sci.* 2006; 14(56):61-6.
12. Toman HA, Hassan R, Hassan R, Nasir A. Craniofacial deformities in transfusion-dependent thalassemia patients in Malaysia: prevalence and effect of treatment. *Southeast Asian J Trop Med Public Health* 2011; 42(5):1233-40.
13. Vahedi M, Mortazavi H, Latifian B, Abdollahzadeh SH. Prevalence of Orofacial Complications in Thalassemic Patients in Thalassemia Center of Qazvin. *J Army Univ Med Sci I.R. Iran* 2009; 7(3):217-21.
14. Krull JT, Krull GE, Dean JA. *Cephalometrics and facial Aesthetics: the Key to Complete Treatment Planning.* McDonald and Avery's Dentistry for the Child and Adolescent. 10th ed. Maryland Heights, Mosby Elsevier; 2016.
15. Shirzaii M. Occlusal abnormalities and face changes in major β -thalassemic patients. *J Qazvin Univ Med Sci* 2009, 13(3): 55-62.
16. Elangovan A, Mungara J, Joseph E, Gupta V. Prevalence of dentofacial abnormalities in children and adolescents with β -thalassaemia major. *IJDR* 2013; 24(4):406.
17. Salehi MR, Farhud DD, Tohidast TZ, Sahebamee M. Prevalence of Orofacial Complications in Iranian Patients with Thalassemia Major. *Iran J Public Health* 2007; 36(2):43-6.
18. Amini F, Jafari A, Eslamian L, Sharifzadeh S. A cephalometric study on craniofacial morphology of Iranian children with beta-thalassemia major. *Orthod Craniofac Res* 2007; 10(1):36-44.