

Acute Disseminated Encephalomyelitis; A Rare Iranian Case Report

*Seyyed-Mohsen Hosseininejad¹, Fateme-Sadat Hosseininejad², Amirhossein SalimiKordasiabi¹, Fateme-Sadat Tabatabaei³, Firouzeh Derakhshanpour⁴, Behnaz Bazrafshan⁵, Mostafa Moein⁶

¹Medical Student, Student Research Committee, Golestan University of Medical Sciences, Gorgan, Iran.

²Student Research Committee, Shahrood University of Medical Sciences, Shahrood, Iran. ³Pediatric Resident, Golestan Pediatric and Neonatal Research Center, Golestan University of Medical Sciences, Gorgan, Iran.

⁴Assistant Professor of Psychiatry, Child and Adolescent Psychiatrist, Golestan Psychiatric Research Center, Golestan University of Medical Sciences, Gorgan, Iran. ⁵Medical Cellular and Molecular Research Center, Golestan University of Medical Sciences, Gorgan, Iran. ⁶Department of Allergy and Clinical Immunology, Children's Medical Center, Tehran University of Medical Sciences, Tehran, Iran.

Abstract

Acute disseminated encephalomyelitis (ADEM) is a monophasic clinical syndrome, characterized by immune-mediated demyelination of central nervous system neurons, which yield extensive damage in the brain and spinal cord. It usually affects children and young adults following infections or immunization.

Here we describe a 9- year-old Fars female presented with acute onset of psychotic disorder, one week after an upper respiratory infection. Magnetic resonance images (MRI) of the brain were consistent with the diagnosis of the acute disseminated encephalomyelitis (ADEM). ADEM is one of the differential diagnoses to be considered when an acute psychotic disorder arises during childhood especially as post vaccination or infection.

Key Words: Acute Disseminated, Encephalomyelitis, Iran, Respiratory Tract Infections.

*Please cite this article as: Hosseininejad SM, Hosseininejad FS, SalimiKordasiabi A, Tabatabaei FS, Derakhshanpour F, Bazrafshan B. Post-Infection or Vaccination Psychosis in a 9- year-old girl; Acute Disseminated Encephalomyelitis; A Rare Iranian Case Report. Int J Pediatr 2017; 5(12): 6699-6702. DOI: **10.22038/ijp.2017.27348.2358**

*Corresponding Author:

Seyyed-Mohsen Hosseininejad, Student Research Committee, Golestan University of Medical Sciences, Shastkola, Gorgan, Iran. Fax: 01732451657

Email: hosseininejad.s.mohsen@gmail.com

Received date: Aug.15, 2017; Accepted date: Sep.12, 2017

1- INTRODUCTION

Acute disseminated encephalomyelitis (ADEM) is an acute demyelinating disorder of the central nervous system (CNS) which primarily affects the white matter of the brain and spinal cord. ADEM almost involves children with the incidence rate of 0.4/100,000 yearly in patients younger than 20 years-old. The peak incidence of ADEM is among 5 to 8 of age. Male to female ratio is the same (1-3, 4). The etiology of ADEM is unknown; however the illness is often precipitated by an infection, less often by vaccination. ADEM is characterized by acute multifocal CNS deficit, including encephalopathy with the peak dysfunction occurring in 2-4 days.

The diagnosis is based on the acute onset of neurologic signs and symptoms besides MRI evidence of multifocal, hyperintense lesions on fluid-attenuated inversion recovery (FLAIR) and T2-weighted images (5- 7). The differential diagnoses of ADEM consist of first episode of multiple sclerosis, macrophage activation syndrome and vasculitis of the CNS (8). Empirical treatment with high-dose steroids or immunoglobulins is often helpful. The prognosis of ADEM is usually favorable (7).

2- CASE REPORT

A 9- year-old Fars female was admitted to our academic psychiatric clinic of Golestan Medical University of Medical Sciences, with a 7-day history of excessive and irrelevant speech. She also complained of people trying to attack her and her mood fluctuated rapidly. She refused to go to school and had become aggressive on minor provocations. Her sleep was disturbed, but appetite was normal. One week prior to showing these symptoms she had a mild upper respiratory infection; also her caretaker reported that one month ago,

she received her national protocol vaccination. She was born of third degree consanguineous marriage and her developmental milestones were unremarkable. She was studying in the fifth degree of elementary school and had a good acceptable academic performance. She was the youngest one in a four-sibling family. Her mother suffered a minor post-partum psychotic immediately after the second delivery, which subsided with treatment well. On our neurological examination, she was alert, conscious and oriented to time, place and person. Her speech was coherent. The child was not totally cooperative.

Although she answered questions relevantly, there was flight of ideas. The reaction time was shortened. Her mood reflected predominantly elevated and occasionally irritable. Definite grandiose delusions and auditory hallucinations were also noticed. No other cranial nerve involvement or focal neurological defect was detected. Deep tendon reflexes were normal and plantar reflex was bilaterally flexor. The rest of physical examinations were normal. Her past psychiatric and medical histories were also normal.

Routine blood laboratory investigations, liver function tests, CSF study and EEG were unremarkable. The MRI images of brain illustrated focal hyperintense areas of varying sizes in the bilateral centrum semi-ovale, fronto-parietal and occipital white matter of T2 and FLAIR sequences, which were hypointense in T1 sequences (**Figure 1**). Intravenous methylprednisolone (30mg/kg/day) was prescribed when admitted to the hospital for three days and then switched on to oral prednisolone for four weeks. Risperidone (0.5mg twice daily) was given to control her behavior. Her symptoms improved within three days and complete recovery achieved after three weeks of treatment.

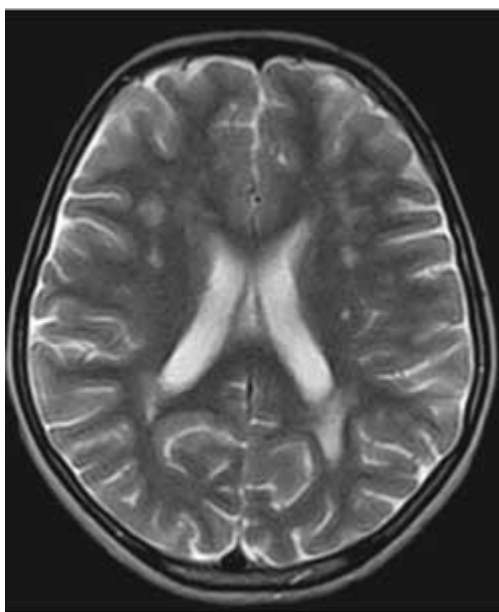


Fig.1: MRI Image, T2 axial section shows white matter hyperintensities.

3- DISCUSSION

The child showed pre-dominantly mood symptoms. Although she presented flight of ideas, the criteria for manic episode could not be satisfied in our case; the unstable clinical picture favored the diagnosis of acute and transient psychotic disorder. The MRI findings were consistent with the diagnostic for ADEM. Generally, psychosis is an uncommon presentation of ADEM. According to a Medline database search from 1965 to 1999, only nine patients who presented acute psychosis were identified (9). After 1999, few more cases of ADEM presenting with psychiatric manifestations have been reported (3, 7, 10, 11). Seemingly, to the best of our knowledge, ADEM in children presenting as acute psychotic episode in a post infection/vaccination manner has not been reported so far in Iran. An acute encephalopathy with multifocal neurologic signs and deficits is usually the first clinical manifestation, but ADEM has a wide range of presenting features (12, 13). We described an atypical case of ADEM

which initially manifested as acute psychosis. A successful diagnosis of the underlying disease necessitates an intensive and rational diagnostic evaluation of the wide spectrum of possible etiologies of psychosis. This case report suggests a new possible association between ADEM and acute psychosis and psychiatric change, which should be considered in the managing patients with acute psychosis, especially in the presence of also unassertive neurologic or neuropsychiatric symptoms.

4-CONCLUSION

Onset of psychotic disorder during childhood seems to be very rare and organic causes should be ruled out in such cases first. ADEM is one probability which should be considered in such situations; MRI imaging could be useful for a precise and earlier diagnosis.

5- CONFLICT OF INTEREST

The authors had not any financial or personal relationships with other people or

organizations during the study. So, there was no conflict of interests in this article.

6- ACKNOWLEDGMENT

We'd like to give special thanks to the nursing staff of 5-Azar hospital psychiatric ward (Gorgan, Iran).

7- REFERENCES

1. Sabayan B, Zolghadrasli A. Vasculitis and rheumatologic diseases may play role in the pathogenesis of acute disseminated encephalomyelitis (ADEM). *Med Hypotheses* 2007; 69(2):322 - 4.
2. Marchioni E, Tavazzi E, Minoli L, Del Bue S, Ferrante P, Piccolo G, et al. Acute disseminated encephalomyelitis. *Neurol Sci.*2008; 29(Suppl. 2): S286-88.
3. Samile N, Hassan T. Acute disseminated encephalomyelitis in children. A descriptive study in Tehran, Iran. *Saudi medical journal.* 2007; 28(3):396-9.
4. Murthy JM. Acute disseminated encephalomyelitis. *Neurol India* 2002; 50: 238-243.
5. Garg RK. Acute disseminated encephalomyelitis. *Postgrad Med J* 2003; 79: 11-17.
6. Murthy SNK, Faden HS, Cohen ME, Bakshi R. Acute disseminated encephalomyelitis in children. *Pediatrics* 2002; 110: e21-e21.
7. Olofsson IA, Skov L, Miranda MJ. Acute disseminated encephalomyelitis is an important differential diagnosis in the acutely affected child. *Ugeskrift for laeger.* 2015; 177(29): pii: V10140549.
8. Johnston VM. Neurodegenerative disorders of childhood. In: Kliegman RM, Behrman RE, Jenson HP, Stanton BF. Eds. *Nelson Text Book of Pediatrics.* 17th Ed. Philadelphia: Saunders; 2007. Pp. 2499– 2507.
9. Nasr JT, Andriola MR, and Coyle PK. ADEM: Literature review and case report of acute psychosis presentation. *Pediatr Neurol* 2000; 22: 8-18.
10. Lin WG, Lirng JF, Chang FC, Chen SS, Luo CB, Teng MM, et al. Sequential MR studies of a patient with white matter disease presenting psychotic symptoms: ADEM versus single-episode MS. *Kaohsiung J Med Sci* 2001; 17: 161-6.
11. Habek M, Brinar M, Brinar VV, Poser CM. Psychiatric manifestations of multiple sclerosis and acute disseminated encephalomyelitis. *Clin Neurol Neurosurg* 2006; 108: 290-4.
12. Di Costanzo M, Camarca ME, Colella MG, Buttaro G, Elefante A, Canani RB. Acute disseminated encephalomyelitis presenting as fever of unknown origin: case report. *BMC Pediatrics.* 2011; 11:103.
13. Verma R, Patil TB, Lalla R, Kumar M. Extensive acute disseminated encephalomyelitis in a young girl responding to intravenous methylprednisolone. *BMJ case reports.* 2013; 2013: bcr2013009222.