

Extubation Failure in an Adolescent Patient after General Anesthesia for Gastrostomy Tube Placement

Luz Helena Gutierrez¹, Manoochehr Karjoo², *Mirza B. Beg³

¹Pediatric Resident, Department of Pediatric, SUNY Upstate Medical University, 750 E Adams St, Syracuse, NY 13210, USA.

²Professor, Division of Pediatric Gastroenterology, SUNY Upstate Medical University, 750 E Adams St, Syracuse, NY 13210, USA.

³Associate Professor, Division of Pediatric Gastroenterology, SUNY Upstate Medical University, 750 E Adams St, Syracuse, NY 13210, USA.

Abstract

Myasthenia gravis (MG) is an autoimmune disease resulting in destruction of the post-synaptic nicotinic receptors at the neuromuscular junction. Classically, the earliest symptoms of MG are ocular, including ptosis and diplopia. Other less common early symptoms include dysphagia and fatigable chewing. Our case report describes the unusual presentation of MG in a teenager patient and presented for an elective percutaneous endoscopic gastrostomy (PEG), tube placement due to persistent weight loss.

The patient underwent the procedure without any complications. At the time of tracheal extubation, she could not maintain spontaneous ventilation, so requiring mechanical ventilation. The patient was transferred from the recovery room to the pediatric intensive care unit (PICU). Subsequent investigations including a bedside electromyography (EMG), led to the diagnosis of MG. The patient was successfully extubated after treatment with intravenous immunoglobulin, oral prednisone 40 mg per day and pyridostigmine 60 mg every 8 hours.

Key words: Anesthesia, Apnea, Intubation, Myasthenia gravis, PEG, Ventilation.

*Please cite this article as: Gutierrez LH, Karjoo M, Beg M. Extubation Failure in an Adolescent Patient after General Anesthesia for Gastrostomy Tube Placement. Int J Pediatr 2017; 5(5): 4849-53. DOI: **10.22038/ijp.2017.8499**

Corresponding Author:

Mirza B. Beg, MD, Department of Pediatric, SUNY Upstate Medical University, 750 E Adams St, Syracuse, NY 13210, USA.

Email: begm@upstate.edu

Received date Mar.10, 2017; Accepted date: Mar. 22, 2017

1- INTRODUCTION

Extubation failure, defined as the need for reinstatement of ventilatory support within 24 to 72 hours of planned endotracheal tube removal, occurs in 2 to 25% of intubated patients. The pathophysiologic causes of extubation failure include an imbalance between respiratory muscle capacity and work of breathing, upper airway obstruction, excess respiratory secretions, inadequate cough, encephalopathy, and cardiac dysfunction.

Our case report describes the unusual presentation of previously undiagnosed neuromuscular disorder who had extubation failure.

2- CASE SERIES REPORT

A 16-year-old African American female presented to the Pediatric Gastroenterology clinic with chest pain and unintentional weight loss of 15 kg over the past 5 months. The patient was previously evaluated for the chest pain at an outside emergency department in which routine laboratory works were negative.

The patient had an electrocardiogram, which was normal. She was started on omeprazole and was referred to Gastroenterology clinic. The patient denied emesis, diarrhea, constipation and abdominal pain. In addition, her complaint was reflux especially in the mornings. The physical examination was unremarkable. Because of the severity of her symptoms an upper endoscopy with biopsies and pH probe study were done. The procedures were performed without any complications and the results were normal.

Several follow ups at the clinic over a period of 12 months documented weight loss of 4 kg despite the use of appetite stimulants such as Megestrol acetate, and nutritional supplements (**Figure.1**). In the meantime, the patient's primary care physician underwent an extensive workup,

including endocrinology and rheumatology studies, all of which were normal. At this point a Percutaneous endoscopic gastrostomy (PEG) tube, was recommended for night feeding. The patient underwent a PEG tube placement without any complications until it was time to extubate.

At this time, she failed to maintain spontaneous ventilation, which triggered the use of reversal anesthetic agents such as naloxone and flumazenil. The patient was later extubated and moved to the recovery room. In the recovery room, the patient became lethargic and poorly responsive; she was treated again with naloxone and flumazenil, resulting in a gradual improvement. Neurology was consulted and her physical exam was unremarkable. Laboratory studies for metabolic abnormalities, were normal and a CT scan of the head without contrast showed no abnormalities. While in the recovery room, the patient's mental and respiratory status deteriorated again, which led to a transfer to the Pediatric Intensive Care Unit (PICU), for intubation and mechanical ventilation.

During her admission in the PICU, the patient failed several efforts for extubation. Further history was taken from the family, which resulted in a history of diplopia, dysphagia and inability to climb multiple flights of stairs in our patient. The new information of diplopia, dysphagia and inability to climb multiple flights of stairs triggered a bedside electromyography (EMG), which revealed findings supportive of myasthenia gravis (MG), with a decremental response of the ulnar nerve with repetitive stimulation (**Figure. 2**).

The patient was successfully extubated on day 4 of her PICU admission, after treatment with intravenous immunoglobulin, oral prednisone and pyridostigmine. The patient was discharged to a short-term rehabilitation

facility for 13 days, and was later discharged home on pyridostigmine 60 mg three times a day and prednisone 40 mg

daily which was gradually tapered over the next 2 months.

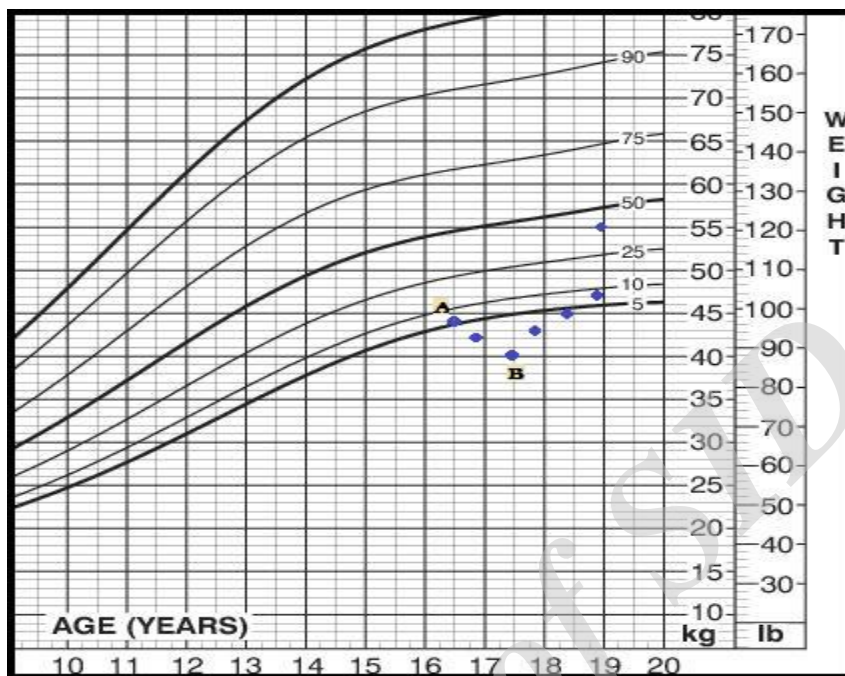


Fig.1: Patient's growth chart. (a) Represents the patient's weight on her first visit to the gastroenterology clinic, (b) represents the patient's weight 12 months after initial follow up as well as approximate time when PEG tube placement was performed.

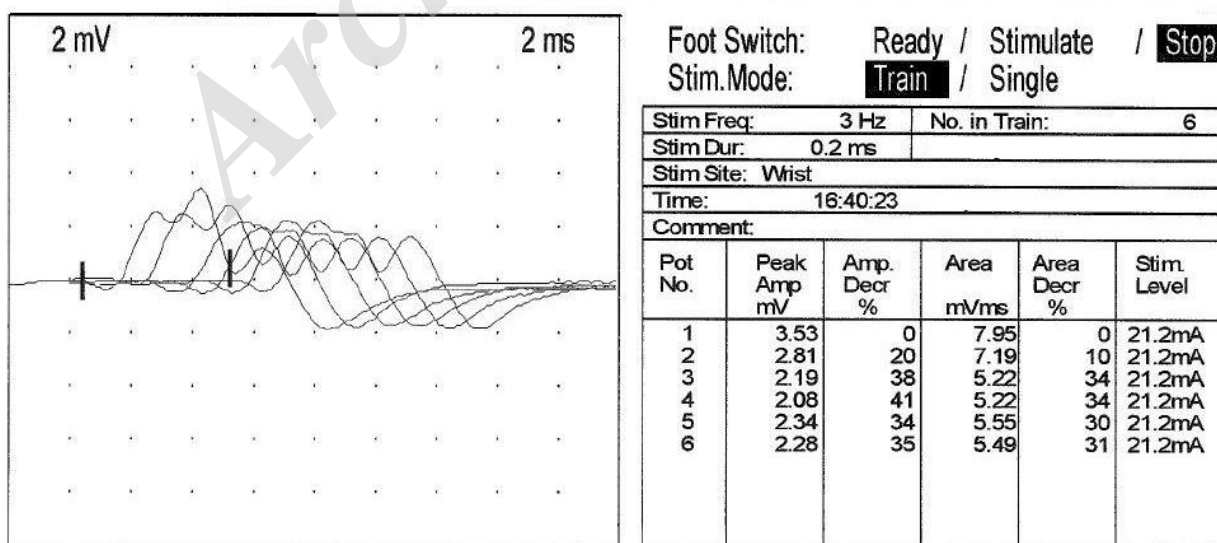


Fig.2: EMG showing a decremental responses of successive motor action potentials from the left abductor digiti minimi muscle after six stimuli of 3 Hz.

3- DISCUSSION

Myasthenia gravis (MG), is a neuromuscular disorder of autoimmune etiology in which antibodies against acetylcholine receptors attack the post-synaptic membrane at the neuromuscular junction, which results in skeletal muscle weakness and fatigue. MG is a rare disorder with the highest reported prevalence rate of 20.4 per 100,000 population (1). Ocular symptoms such as ptosis and diplopia compromise 85% of the initial complaint reported by patients (2). Bulbar weakness which can manifest as dysphagia, dysarthria, or fatigable chewing are the presenting complaint in only 6% of the patients (3).

The onset of MG is significantly earlier in women compared to men (2). The disease shows a bimodal distribution with a peak in the second and third decades, when women are affected the most, and a second peak in the sixth and seventh decades, when men are more affected (4). There are two main clinical subtypes of MG: primary ocular, and generalized (5). Respiratory muscle weakness can develop which could be life threatening (5). Myasthenia Crisis (MC), is a medical emergency defined by respiratory failure requiring mechanical ventilation; approximately 15% to 20% of patients with MG, go into MC (6). Some precipitants of MC include surgery, infections, emotional stressors, medications, and thyroid disease (6).

The muscular fatigue associated with MG was not evident in this case. It was only after further history was taken that early symptoms of MG such as diplopia, dysphagia and extremity weakness were recognized. As was mentioned above ocular symptoms compromise 85% of the initial complaint reported by patients (2), other symptoms like dysphagia are less than 6% (3). Neither diplopia nor dysphagia was severe enough to be reported by the patient in initial encounters, making the diagnosis of MG

difficult. The initial presentation of the patient, and worrisome complaint, was persistent weight loss. In the pediatric population the most common causes of weight loss include infections, depression and eating disorders (7). Less common etiologies include inflammatory bowel disease, cystic fibrosis, chronic inflammatory disease, malignancy, thyrotoxicosis, and renal failure (7).

MG is a rare autoimmune disorder that does not typically present with persistent weight loss as the presenting symptom, and to our knowledge, there is only one case reported in the literature of underlying MG in a patient presenting with weight loss. This case was an 86-year-old woman who presented with loss of weight and difficulties with feeding (8). Unintentional weight loss, with an otherwise asymptomatic pre-clinical illness is strongly associated with morbidity and mortality (9).

Gastroenterological disorders are the second most common organic etiology (malignancy being number one), identified in patients with unintentional weight loss (10). An in-depth history and physical examination, can usually reveal signs or symptoms of disorders such as inflammatory bowel disease, chronic pancreatitis, celiac disease, peptic ulcer disease, constipation, atrophic gastritis, etc. (10).

4- CONCLUSION

Upon reviewing the case one can appreciate the importance of a detailed and precise history. It can be speculated that the patient's persistent weight loss was secondary to dysphagia. The patient did not state having difficulty or painful swallowing on any of her visits to the clinic. Perhaps, the dysphagia was not properly verbalized by the patient, and as a result only the consequence of the dysphagia, i.e. weight loss, was reported.

This case beautifully highlights the importance of a thorough history and the complexity of the differential diagnoses of a patient presenting with weight loss, which should include the rare, but yet possible diagnosis of MG.

5- ABBREVIATIONS

- PEG: Percutaneous endoscopic gastrostomy,
- CT: Computerized tomography,
- PICU: Pediatric intensive care unit,
- EMG: Electromyography,
- MG: Myasthenia gravis,
- MC: Myasthenia crisis.

6- DISCLOSURES

None of the authors have financial disclosure to announce about this case. This case report was presented as a poster in the annual NASPGHAN meeting, which took place in Atlanta, October 23-26, 2014. Informed consent was obtained from the patient.

7- REFERENCES

1. Phillips LH. The epidemiology of myasthenia gravis. *Semin Neurol* 2004; 24:17.
2. Grob D, Brunner N, Namba T, Pagala M. Lifetime course of myasthenia gravis. *Muscle Nerve* 2008; 37:141.
3. Burch J, Warren-Gash C, Ingham V, Patel M, Bennet D, Chaudhuri KR. Myasthenia gravis, a rare presentation with tongue atrophy and fasciculation. *Age and Ageing* 2006; 35:87-8.
4. Klair JS, Rochlani YM, Meena NK. Myasthenia gravis masquerading as dysphagia: unveiled by magnesium infusion *BMJ Case Rep.* 2014; 2014: bcr2014204163. Published online Apr 17, 2014. doi: 10.1136/bcr-2014-204163.
5. Liew WK, Kang PB. Update on juvenile myasthenia gravis. *Current opinion in pediatrics* 2013 Dec; 25(6):694-700.
6. Thomas CE, Mayer SA, Gungor Y, Swarup R, Webster EA, Chang I, Brannagan TH, Fink ME, Rowland LP. Myasthenic crisis: clinical features, mortality, complications and risk factors for prolonged intubation. *Neurology* 1997; 48:1253-60.
7. Tunnessen WW, Roberts KB. Weight loss. In: *Signs and Symptoms in Pediatrics*. 3rd edition, Lippincott, Williams and Wilkins: Philadelphia; 1999. pp. 36-40.
8. Petit A, Constans T, Chavanne D, Hommet C. Myasthenia gravis in the elderly: a rare cause of undernutrition. *Aging clinical and experimental research* 2012; 24(4):398-9.
9. Meltzer AA, Everhart JE. Unintentional weight loss in the United States. *Am J Epidemiol* 1995; 142: 1039.
10. Bouras EP, Lange SM, Scolapio JS. Rational approach to patients with unintentional weight loss. *Mayo Clin Proc* 2001; 76: 923.