

Application of the Topical Hydrocortisone Ointment Decreases Post-Circumcision Meatal Stenosis in Neonates: A Cross-Sectional Study

Amrollah Salimi¹, Mahsa Besharati², Shervin Rashidi Nia², Sara Shahmoradi²,
*Seyed Shahin Eftekhari²

¹Department of Pediatric Surgery, Hazrat Masoume Hospital, Qom University of Medical Sciences, Qom, Iran.
²Student Research Committee of Qom University of Medical Sciences, Qom, Iran.

Abstract

Background: Meatal stenosis is of common late complication of neonatal circumcision, albeit the appropriate post-operative care and conventional consumption of topical agents such as tetracycline. Nevertheless, its underlying etiology still remained vague. Lack of protective effects of foreskin and subsequent inflammation reaction due to chemical and mechanical irritation is thought to be the most probable cause.

Materials and Methods: A retrospective review of the medical records of the male neonates, were considered eligible who referred to our pediatric tertiary center (Hazrat-e-Masumeh hospital, Qom city) for circumcision between May 2014 and April 2016. Neonates with severe phimosis and buried penis were excluded from the study. Based on the medical records the patients were divided into two groups. Patients were operated similarly, and then, those who received 1% hydrocortisone ointment post-operatively (n=91) and those who received the conventional treatment with tetracycline cream instead of hydrocortisone (n=91).

Results: The mean age of neonates was 19.2 ± 3.6 and 21.4 ± 2.1 days for tetracycline and hydrocortisone groups, respectively. Meatal stenosis has occurred in 27(29.67%) patients of the tetracycline group, and 11(12.08%) of the hydrocortisone group ($P=0.008$). Mean time to develop meatal stenosis in the tetracycline group was less than that of the hydrocortisone group (2.3 ± 0.4 vs. 3.8 ± 0.65 weeks, respectively, $P=0.03$). There was no adverse effect associated with application of 1% topical ointment of hydrocortisone.

Conclusion

According to the results, applying the topical ointment of hydrocortisone can more effectively reduce post-circumcision meatal stenosis compared with tetracycline cream. Nonetheless, conducting further investigations designing as randomized clinical trial or experimental studies is highly encouraged.

Key Words: Circumcision, Meatal stenosis, Neonates, Topical hydrocortisone.

*Please cite this article as: Salimi A, Besharati M, Rashidi Nia Sh, Shahmoradi S, Eftekhari SS. Application of the Topical Hydrocortisone Ointment Decreases Post-Circumcision Meatal Stenosis in Neonates: A Cross-Sectional Study. *Int J Pediatr* 2017; 5(6): 5061-67. DOI: [10.22038/ijp.2017.23023.1927](https://doi.org/10.22038/ijp.2017.23023.1927)

*Corresponding Author:

Seyed Shahin Eftekhari, M.D, School of Medicine, Qom University of Medical Sciences, Qom, Iran.

Email: s.shahin.eftekhari@gmail.com

Received date: Mar.05, 2017; Accepted date: May.12, 2017

1- INTRODUCTION

Meatal stenosis is a relatively common condition occurring in 9%-10% of male neonates who are circumcised. The incidence is significantly higher in neonatal circumcision compared to higher-aged groups (1, 2). Notwithstanding the fact that this condition is extremely rare in uncircumcised boys suggestive of its leading contributing effect (3-6), the underlying etiology still remained unclear. Long time urine exposure of the glandular meatus, which results in inflammation (ammoniac dermatitis), and mechanical irritation due to meatus rubbing against a wet diaper are the most probable causes of neonatal meatal stenosis (3). Accordingly, post-operative cares include the principal measurements of the prevention strategy. This approach is pivotal in terms of avoiding consequent complications such as urinary discomfort, frequent infection and potential kidney injuries.

Application of topical agents containing petroleum jelly can decrease the incidence of meatal stenosis (7, 8). In this regard, it is believed that this effect derived from lubricating property of these agents. Hydrocortisone acetate 1% is an alternative option as a low potent corticosteroid, which has lubricating effect in addition to decreasing inflammatory response so it can, theoretically, prevent adhesion formation and subsequent meatal stenosis.

Various types of corticosteroids are routinely used in different areas of body for reducing the inflammation. As an illustration, it is currently used as a treatment option of phimosis in infants without any side effect (9-11). This approach is pivotal in terms of avoiding consequent complications following anatomical disruption in urinary tract, such as urinary discomfort, urinary stasis and subsequent frequent infection and potential kidney injuries (12-14). Notwithstanding the consensus regarding the use of

lubricating agents as a successful preventing strategy (7), the most effective drug still remained somewhat vague and needs to be investigated. Each of the two drugs, tetracycline and hydrocortisone, has their particular properties in addition to their lubricating effects which made their superiority unclear. Tetracycline has its specific property of being an antibiotic agent and hydrocortisone is a well-known anti-inflammatory drug. In this study, therefore, we intend to compare these two treatment options which are both acceptable practically.

2- MATERIALS AND METHODS

2-1. Study design and subjects

The medical records of the patients who were referred to our pediatric university hospital of Hazrat-e-Masumeh in Qom city, Qom province- Iran, for circumcision due to cultural reasons between May 2014 and April 2016 were enrolled to be reviewed. Patients under the age of 1 month who received post-operative care using either the tetracycline cream or 1% hydrocortisone ointment included in this study. All neonates with severe phimosis or buried penis, fatty babies with concealed penis or those with history of significant urinary tract infection (UTI) and glandular hypospadias were excluded from the study. Total numbers of 215 hospital records were reviewed of which 98 belonged to the hydrocortisone group and remaining 117 were of tetracycline group. Patients with incomplete data were excluded as well, so that the same number of 91 patients remained within each study group.

2-2. Intervention

In a cross-sectional study, 182 neonates were included and divided into two groups depend on the medical records. All patients underwent surgery by a single senior pediatric surgeon (A.S) using the Plastibell method. Both groups received

the standard management either by tetracycline cream or hydrocortisone. Both agents provide the appropriate treatment based on previously recommended therapeutic approach (7). In the tetracycline group, tetracycline cream had been applied as a lubricate agent, at the glans as well as wound. In another group, 1% hydrocortisone ointment instead of tetracycline had been used. Parents were taught to apply medication when necessary to have the glans and the wound covered by either of topical agents. Furthermore, there was no preference between each agent at prescription since both drugs are accepted in the literature.

2-3. Measurements and outcomes

During the follow-up, patients were examined within a week of surgery and then every two weeks by a physician examiner other than the attending surgeon. Based on the medical records, examinations were focused on appearing of the meatal stenosis and identifying any complication which may negatively affect the healing process including infection, adhesion formation and skin reactions. Difficulty in passing the catheter of 5 French was considered as meatal stenosis.

2.4 Ethical consideration

Ethical issues were considered by keeping the patient information confidential and the Qom University of Medical Sciences ethics committee supervised the study in terms of ethical considerations as a retrospective study.

2-5. Statistical analysis

The statistical software of SPSS version 24.0 for windows (SPSS Inc., Chicago, IL) was used for data analysis. Results were presented as mean \pm standard deviation (SD) and were summarized using absolute

frequencies and percentages for categorical variables. Categorical variables were compared using Chi-square test or Fisher's exact test. P values of 0.05 or less were considered to be statistically significant.

3-RESULTS

Entire patients were term at the time of delivery with the mean weights of 3450 \pm 180 grams. Mean age of the neonates were 19.2 \pm 2.6 and 21.4 \pm 1.8 days for tetracycline and hydrocortisone group, respectively (P= 0.678).

The mean duration of follow-up was 11.2 weeks and ranged from 7 to 15 weeks. Meatal stenosis has been recorded in 27 (29.67%) and 11 (12.08%) for tetracycline group and hydrocortisone group, respectively (P=0.008). Mean time to develop meatal stenosis in the tetracycline group was less than that of the hydrocortisone group (2.3 \pm 0.4 weeks vs. 3.8 \pm 0.65 weeks, P=0.03). According to our data, meatal stenosis has occurred mostly in the first two months of surgery (**Figure.1**).

By this we mean that, if the meatal stenosis does not appear in this period, the probability of its occurrence would be low thereafter. The total incidence of meatal stenosis was 38 (20.88%) in our series, of which only two patients showed symptoms of urinary discomfort such as burning sensation during urination according to their parents.

Other patients were asymptomatic. Any adverse effect associated with neither application of 1% topical ointment of hydrocortisone nor tetracycline cream was recorded. The average healing period for tetracycline and hydrocortisone group was 6.1 \pm 3.2 and 6.7 \pm 4.1 days, respectively (P=0.714) (**Table.1**).

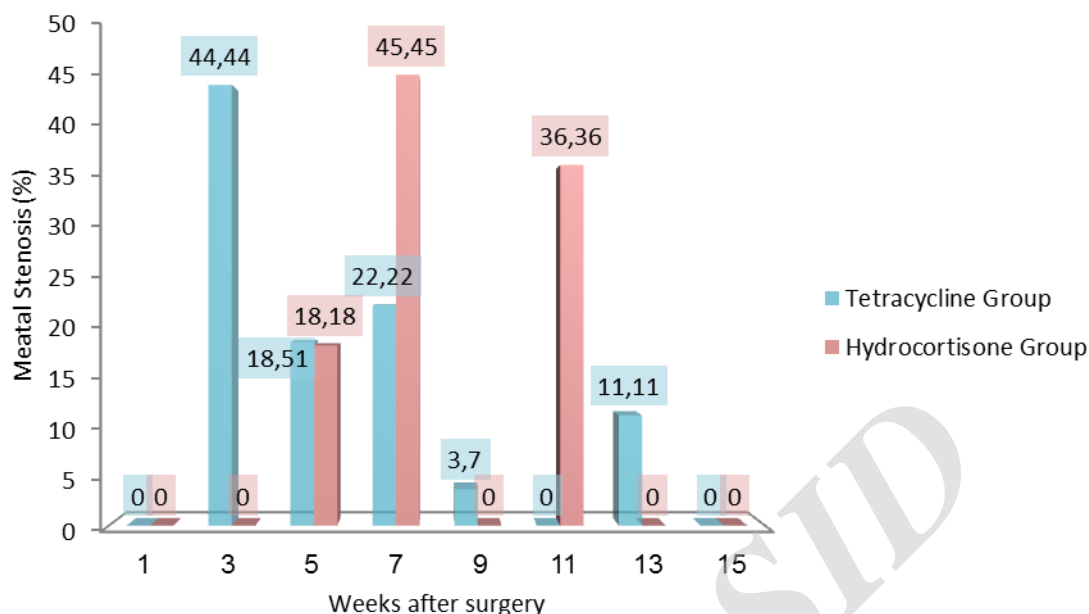


Fig.1: Incidence of meatal stenosis in both hydrocortisone group and tetracycline group through the follow-up.

Table-1: Findings comparing patient characteristics, complications, and healing process between two groups.

Findings	Hydrocortisone (n:91)	Tetracycline (n: 91)	P- value*
Age (Day; mean ± SD)	22.4±2.1	19.2±3.6	0.678
Meatal Stenosis; n (%)	11 (12.08%)	27 (29.67%)	0.008
Time of Occurrence (weeks; mean ± SD)	3.8±0.65	2.3±0.4	0.03
Recovery time (Day; mean ± SD)	6.7±4.1	6.1±3.2	0.714

*t. test was used; SD: Standard deviation.

4- DISCUSSION

Meatal stenosis is of highly prevalent complications following neonatal circumcision (1, 15). Nevertheless, underlying causes are not completely understood. Ammonia dermatitis and reduced glandular tip circulation, due to injury to frenula artery, are the most probable causes (3, 16). Both hypotheses are more prevailing in neonatal period that propound a special necessity of follow-up and genital examinations for all

circumcised infants, to detect potential meatal stenosis (16). According to Persad et al. (3), Meatal stenosis is described as a late complication of circumcision due to ammonia dermatitis. We believe if ammoniac dermatitis was the exclusive cause of meatal stenosis, this would be a slow-growing phenomenon which occurs after several weeks. According to our study, stenosis has been developed mostly through the first few weeks of surgery in patients who received tetracycline. Our

data showed 27% meatal stenosis in the tetracycline group, which takes account of an incidence rate of 29.67%. In our country neonatal circumcision has been increasing which, consequently, increases the incidence of meatal stenosis. Although the incidence of meatal stenosis after neonatal circumcision is high, the majority of them are asymptomatic.

Meatitis due to irritation from wet diapers is of mentioned leading cause of meatal stenosis through inflammation that provides. In other words, the foreskin is thought to play a protective role in this context (17); Foreskin also plays a protective role against mechanical irritation of the glans penis and thereby preserve the tissue from chronic injuries. Consequently, it is expected that by removing this protective factor in infants who have been circumcised, this series of complications occur more prevalent. Stenosis is initially a thin fibrotic material that sometimes appears following the initial recovery and healing period. Thereafter, if untreated, fibrotic material gradually becomes thicker. Mondal et al. (17), reported an acceptable experience of taking advantage of applying petroleum jelly as a lubricant agent. The authors proposed that the use of a lubricant can be helpful in reducing inflammation and preventing its subsequent events.

Applying the lubricating agents to enhance the healing process is routinely used and described in the literature (7). Tetracycline cream is the main topical agent used in our routine practice with positive effects in terms of decreasing both healing period and the incidence of meatal stenosis. Notwithstanding the lubricating agents are routinely used for all patients, meatal stenosis in neonatal circumcision prevalently occurs. Hydrocortisone is a low potent corticosteroid extensively used for many skin inflammatory processes. Hydrocortisone has been successfully applied for treating the phimosis and

unretract-able foreskin in infants (9-11). Although hydrocortisone never has been used for prevention of meatal stenosis after circumcision, theoretically, it can reduce local inflammation of the meatus post-operatively and prevent later adhesion and meatal stenosis. In hydrocortisone group, we had 11 meatal stenosis compared with 27 cases in the other group supporting our hypothesis of the positive effect of hydrocortisone in reduction of meatal stenosis. On the other hand, as can be seen, this protocol of post-operative care applying hydrocortisone ointment also delayed onset of meatal stenosis which in turn arises the possibility that this anti-inflammatory agent will be able to affect entire underlying processes.

By this we mean that, inflammation is of paramount importance in the onset and progression of this condition. Although more investigations are needed to further support this hypothesis, anti-inflammatory effect of hydrocortisone can explain the reason why meatal stenosis has been decreased. Another evidence is that, in majority of the neonates, the prepuce has tightly adhered to the glans penis and we had to retract it intra-operatively (18).

Accordingly, we suggest that initial trauma due to intra-operative forceful retraction of the prepuce potentially can play a role in intensifying and accelerating the development of meatal stenosis. Therefore, the use of hydrocortisone ointment can decrease inflammatory reaction of this minor trauma and subsequently causes reduction in meatal stenosis.

Although injury of frenular artery during circumcision can also predispose glandular area to develop dermatitis and stenosis, more investigations are needed to evaluate the role of forceful retraction of the prepuce during circumcision in meatal stenosis. Age is another influencing factor that affects wound healing process (19). It is observed that biological properties of the wound vary with age. Bermudez et al.

(20), have asserted that the level of inflammatory cytokines in wounds increase with age indicative of more severe inflammatory reaction and subsequent further risk of scar formation. Hence, these findings also confirmed the inevitable role of inflammation in wound-related complications. Prolonged use of topical hydrocortisone can cause skin thinning and atrophic changes in the area of usage, but no side effect has been reported, so far, for a short-term usage of low-potent corticosteroids such as 1% hydrocortisone. Throughout the follow-up, we have not witnessed any change in skin or appearance of the glandular area. Healing process concerning recovery time was identical between both groups.

Interestingly, we have also witnessed, a few neonates developed stenosis later in the follow-up who appeared normal after initial healing course. Out of the 38 cases with meatal stenosis, only 2 mothers complained that their sons had some degree of difficulty in urination. This indicates that symptomatic meatal stenosis is low in neonatal circumcision fundamentally, perhaps due to little attention of parents and lack of education about normal urination and post-operative cares (1).

Most of the symptomatic meatal stenosis development later in life, when the baby is older and parents pay attention to them with more precision regarding the symptoms such as narrowing, deviation and incomplete urination. The strength of our study is to compare two different approaches for post-circumcision care which is certainly challenging in the practice. However, common to all retrospective studies, our study is restricted due to potential recording biases. Therefore, conducting further prospective investigations as clinical trials with sufficient sample size is highly recommended.

5- CONCLUSION

Generally, application of the topical 1% hydrocortisone ointment compared to routine care with tetracycline can decrease the incidence of meatal stenosis and increase the time to occurrence after neonatal circumcision. Additionally, our data analysis implies that the incidence of meatal stenosis following neonatal circumcision is high and drew a particular consideration to schedule a special follow-up and genital examination for all circumcised neonates, to detect possible meatal stenosis at least for two months.

6- CONFLICT OF INTEREST

The authors have no financial disclosures or conflicts of interest.

7- REFERENCES

1. Van Howe RS. Incidence of meatal stenosis following neonatal circumcision in a primary care setting. *Clinical pediatrics* 2006;45(1):49-54.
2. Joudi M, Fathi M, Hiradfar M. Incidence of asymptomatic meatal stenosis in children following neonatal circumcision. *Journal of pediatric urology* 2011;7(5):526-8.
3. Persad R, Sharma S, McTavish J, Imber C, Mouriquand P. Clinical presentation and pathophysiology of meatal stenosis following circumcision. *British journal of urology* 1995;75(1):91-3.
4. Sijstermans K, Hack W, Bos S, van der Horst H. [Urethral meatal stenosis in boys easily overlooked]. *Nederlands tijdschrift voor geneeskunde* 2005;149(50):2765-9.
5. Brown MR, Cartwright PC, Snow BW. Common office problems in pediatric urology and gynecology. *Pediatric clinics of North America* 1997;44(5):1091-115.
6. Smith C, Smith DP. Office pediatric urologic procedures from a parental perspective. *Urology* 2000;55(2):272-6.
7. Bazmamoun H, Ghorbanpour M, Mousavi-Bahar SH. Lubrication of circumcision site for prevention of

meatal stenosis in children younger than 2 years old. *Urology journal* 2008;5(4):233-6.

8. Al-Abdi SY. Petroleum jelly for prevention of post-circumcision meatal stenosis. *Journal of clinical neonatology* 2013;2(3):113.

9. Ghysel C, Vander Eeck K, Bogaert GA. Long-term efficiency of skin stretching and a topical corticoid cream application for unretractable foreskin and phimosis in prepubertal boys. *Urologia internationalis* 2009;82(1):81-8.

10. Moreno G, Corbalán J, Peñaloza B, Pantoja T. Topical corticosteroids for treating phimosis in boys. *The Cochrane Library*. 2014.

11. Webster T, Leonard M. Topical steroid therapy for phimosis. *The Canadian journal of urology* 2002;9(2):1492-5.

12. Salimi A, Eftekhari SS, Rashidinia S, Shahmoradi S. Novel Presentation of Complete Coronal Urethral Duplication: a Case Report. *International Journal of Pediatrics* 2017;4707-12.

13. Akhavan Sepahi M, Eftekhari SS, Shahmoradi S, Talebizadeh M, Rashidinia S, Hejazi SS. Metabolic and Anatomic Abnormalities Associated with Pediatric Nephrolithiasis: a Cross-Sectional Study. *International Journal of Pediatrics* 2017;5(5):4833-8.

14. Akhavan Sepahi M, Eftekhari SS, Rashidinia S, Shahmoradi S, Shokrollahi SMR, Pormehr S. Relationship between urinary reflux and nephrolithiasis in children-

a cross-sectional study. *International Journal of Pediatrics* 2017;5(5):4965-73.

15. Weiss HA, Larke N, Halperin D, Schenker I. Complications of circumcision in male neonates, infants and children: a systematic review. *BMC urology* 2010;10(1):1.

16. Godley SP, Sturm RM, Durbin-Johnson B, Kurzrock EA. Meatal stenosis: A retrospective analysis of over 4000 patients. *Journal of pediatric urology* 2015;11(1):38. e1-e6.

17. Mondal SK, Ali MA, Alam MK, Hasina K, Talukder AR, Yusuf MA, et al. Use of lubricant at meatus and circumcision site in younger children prevent post circumcision meatal stenosis: A randomized control trial. *Journal of Shaheed Suhrawardy Medical College* 2013;5(1):35-8.

18. Kayaba H, Tamura H, Kitajima S, Fujiwara Y, Kato T. Analysis of shape and retractability of the prepuce in 603 Japanese boys. *The Journal of urology* 1996;156(5):1813-5.

19. Aykac A, Yapici O, Baran O, Oguz U, Cakan M. What is the ideal age of circumcision for wound healing time? *The European Research Journal* 2016;2(3):206-10.

20. Bermudez DM, Canning DA, Liechty KW. Age and pro-inflammatory cytokine production: Wound-healing implications for scar-formation and the timing of genital surgery in boys. *Journal of pediatric urology* 2011;7(3):324-31.