

## Combined Therapy for Anti-N-methyl D-aspartate Receptor Encephalitis

Takahiro Kido<sup>1,2</sup>, \*Chie Kobayashi<sup>3</sup>, Tatsuyuki Ohto<sup>3</sup>, Yukitoshi Takahashi<sup>4</sup>, Ryo Sumazaki<sup>3</sup>, Takashi Fukushima<sup>3</sup>

<sup>1</sup>Department of Pediatrics, University of Tsukuba Hospital, Ibaraki, Japan.

<sup>2</sup>Department of Emergency and Critical Care Medicine, University of Tsukuba Hospital, Ibaraki, Japan.

<sup>3</sup>Department of Child Health, Faculty of Medicine, University of Tsukuba, Ibaraki, Japan.

<sup>4</sup>National Epilepsy Center, Shizuoka Institute of Epilepsy and Neurological Disorders, NHO, Shizuoka, Japan.

### Abstract

#### Background

Anti-N-methyl- d-aspartate receptor (anti-NMDAR) encephalitis is an autoimmune neurological disorder that usually occurs as a paraneoplastic syndrome and is particularly associated with ovarian teratoma. Standard therapy for severe cases is not established and the prognosis in patients who do not respond to first-line treatment is poor.

#### Case Report

An 11-year-old boy complained psychiatric symptoms and rapidly lost consciousness. CT scan revealed mediastinal teratoma and serum/spinal fluid was positive for anti-NMDAR antibody. He kept comatose and his brain stem function was profoundly disturbed. His symptoms were refractory to first-line therapy, which involved tumor resection, methylprednisolone (mPSL) pulse, Intravenous immunoglobulin (IVIG), and plasma exchange. We administered a combination therapy of rituximab and cyclophosphamide as second-line therapy and achieved complete recovery without adverse effects related to treatment.

#### Conclusion

We consider early intensive treatment with a combination of rituximab and cyclophosphamide to be a safe and effective option for severe cases of anti-NMDAR encephalitis.

**Key Words:** Anti-NMDAR encephalitis, Cyclophosphamide, Immunotherapy, Mediastinal teratoma, Rituximab.

\*Please cite this article as: Kido T, Kobayashi C, Ohto T, Takahashi Y, Sumazaki R, Fukushima T. Combined therapy for Anti-N-methyl D-aspartate receptor encephalitis. *Int J Pediatr* 2017; 5(9): 5687-91. DOI: **10.22038/ijp.2017.24465.2087**

#### \*Corresponding Author:

Chie Kobayashi, Permanent address: Department of Pediatrics, University of Tsukuba, School of Medicine and Medical Science, 1-1-1 Amakubo, Tsukuba, Ibaraki, Japan.  
Fax: +81 0298533900.

Email: ckobayashi@md.tsukuba.ac.jp (Chie Kobayashi)

Received date: Jun.22, 2017; Accepted date: Jul. 12, 2017

## 1- INTRODUCTION

Anti-N-methyl-d-aspartate receptor (Anti-NMDAR) encephalitis is an acute autoimmune neurological disorder that was first described as a paraneoplastic syndrome associated with ovarian teratoma (1). Subsequent reports revealed that there are cases with extra ovarian teratomas and nontumor cases can also occur in younger patients. Symptoms and severity of the disease vary between cases. The first-line treatment is tumor resection, corticosteroids, immunoglobulin (IVIG), and plasma exchange. Scant response to first-line therapy occurs in about half of the patients (48 %). For those patients who do not respond to the first-line therapy, immunosuppressive agents should be administered as second-line therapy. Recovery can take considerable time and in previous reports 18 months of follow up was not sufficient to estimate the prognosis (2). Here, we report a severe case of anti-NMDAR encephalitis in an 11-year old boy who was successfully treated by combination therapy of rituximab and cyclophosphamide.

## 2- CASE REPORT

An 11-year-old previously healthy boy was taken to a local hospital by his parents one day after developing psychological symptoms such as agitation and hallucinations. For several months, his parents had been concerned about his apparent mild memory loss and his development of insomnia one week before presentation at the hospital. Routine brain MRI was normal. He was diagnosed with psychologic disorder, prescribed an anxiolytic agent, and discharged, but later became restless with involuntary movements and incoherent in speech. He was brought back to the hospital and admitted the following day. On admission, no neurological abnormality was detected despite exhibiting fluctuating levels of conscious.

The results of routine laboratory investigations were unremarkable. His cerebrospinal fluid (CSF) revealed mild elevation of cell count (cell: 190/3 $\mu$ l, total protein: 35mg/dl, and glucose: 59mg/dl). After admission, his consciousness level declined rapidly that he was unresponsive to pain stimulation 2 days after admission. He was diagnosed with encephalopathy of unknown origin because his electroencephalography (EEG) showed continuous slow wave activity. He was given 2 courses of methylprednisolone (mPSL) pulse and 1 course of IVIG. Acyclovir and CTRX were also administered empirically until his CSF culture and Polymerase chain reaction (PCR) analysis for herpes simplex virus returned negative one week after admission.

He did not respond to these treatments. Moreover, he began to exhibit severe involuntary movements and autonomic nervous symptoms (paroxysmal tachycardia, increased secretion of saliva, and priapism). Eighteen days after admission, CT scan revealed a 4.5cm  $\times$  6.0cm tumor with heterogeneous components, considered to be a teratoma tumor, on his mediastinum. He was diagnosed with paraneoplastic encephalopathy and transferred to our hospital the following day.

At the intensive care unit of our hospital, we began mechanical ventilation due to profound coma (Glasgow Coma Scale [GCS]; GCS 3 [E1V1M1]), lack of cough reflex, and instability of spontaneous breathing. Complete tumor resection was performed 4 days after transferal. The pathological diagnosis was mature teratoma. But due to the elevation of serum alpha-fetoprotein (AFP) level (36ng/ml), we diagnosed his tumor as being mature teratoma with a germ cell component. Anti-NMDAR antibodies by enzyme-linked immunosorbent assay (ELISA) were detected in his serum and CSF

collected at the onset of the disease (3). His condition was thus diagnosed as anti-NMDAR encephalitis related to mediastinal teratoma. We conducted another course of mPSL pulse therapy and plasma exchange 4 times. Serum AFP level decreased 2 weeks after surgery. He showed limited response to the first-line therapy mentioned above. His autonomic nervous symptoms and involuntary movement ceased. He was also withdrawn from mechanical ventilation because his cough reflex and spontaneous breathing had recovered.

However, 2 months after onset, his condition did not show any further improvement; he was in deep coma (GCS; E1V1M1) and his EEG showed only slight activity. As a second-line therapy, we sought an intense immunosuppressive and decided on a combination therapy of rituximab and cyclophosphamide, based on the treatment protocol proposed by Dalmau et al. (4). We started 4 cycles of monthly cyclophosphamide (750mg/m<sup>2</sup>) with 4 infusions of weekly rituximab (375mg/m<sup>2</sup>) followed by 4 times of monthly dose.

With this regimen, he began to recover, pain response had returned 86 days after initial onset, and 112 days after onset he opened eyes and could track movements. 150 days after onset he could walk without support. His cognitive functions were difficult to assess at first, because he showed severe autistic features such as echolalia and insistence. However, these autistic symptoms also recovered gradually.

Antibody titers against each subunit of anti-NMDAR (GluN2B-NT2, GluN2B-CT, GluN1-NT) and GluD2-NT were evaluated by ELISA. The antibody titers in CSF were from 5 to 6 times greater compared with controls and from 2 to 3 times greater in serum at disease onset. The antibody titers showed no response to first-line treatment. However, they

decreased in parallel with combined therapy with rituximab and cyclophosphamide in his clinical course.

All planned therapy was ended 7 months after initial onset. At discharge, mild memory loss was only the remaining symptom. At 10 months, he was full recovered and returned to school without any social support. Details of his clinical course and treatments are shown in **Figure.1** (*Please see the end of paper*).

Concurrent with the second-line treatment, we administered sulfamethoxazole-trimethoprim as a prophylaxis against opportunistic infection. Indeed, B cell was disappeared completely from his peripheral blood (0/μL) 7 days after first administration of rituximab. However, serum IgG level did not decrease below 600mg/dL. Bone marrow suppression up to Grade 2 (Common Terminology Criteria for Adverse Events (CTCAE) Version 4.0. 4) was the only adverse effect recorded. No episode of infection was observed and the B cell count and IgG level returned to normal range.

### 3- DISCUSSION

In anti-NMDAR encephalitis, standard criteria for using combination therapy of rituximab and cyclophosphamide are not established. Both rituximab and cyclophosphamide were first proposed as second-line treatment by Dalmau et al. in 2011 (4), and after they indicated their efficacy in a large cohort study in 2013 (2) clinicians began to follow these treatment protocol (5, 6). The majority of recent cases have reported the benefits of rituximab or cyclophosphamide alone and combination therapy is, therefore, only appropriate in certain cases. After second-line treatment (rituximab and/or cyclophosphamide), more than 20% of patients still have a poor outcome (modified Rankin scale >3) and even in cases with good outcomes recovery can take over 24 months (2). Physicians should

aim to identify cases with a poor prognostic earlier and use this combination therapy to provide strong immunosuppression. In this case, deep coma and suppressed EEG activity that had continued for over 1 month after initiating first-line treatment were the cues to choosing the combination of rituximab and cyclophosphamide. The need for admission to an intensive care unit, delayed treatment, and high severity of disease within 4 weeks of onset are known as poor prognostic factors for anti-NMDAR encephalitis (2).

In our patient, despite his antibody titers revealing no response to the first-line treatment, they decreased soon after initiating the combination therapy. Thus, if circumstances allow, fluctuation of antibody titer in CSF might be helpful to determine the intensity of second-line treatment. The therapeutic challenge in anti-NMDAR encephalitis is not only better neurocognitive prognosis and shorter duration of recovery, but also reduction of adverse events. Because rituximab is a relatively new drug, especially in pediatric application, reports of long-term safety and toxicity are lacking. Russel reported the utility and safety of rituximab in a retrospective cohort consisting of 144 pediatric patients with autoimmune and inflammatory CNS disease including anti-NMDAR encephalitis. Only 11 (7.6%) of them had reported infectious episodes (6).

#### 4- CONCLUSION

In this report, we introduced an extremely severe case of anti-NMDAR encephalitis related to mediastinal teratoma tumor in an 11-year-old boy. His symptoms were catastrophic and developed rapidly. Second-line treatment with rituximab and cyclophosphamide brought him complete recovery within 10 months of onset, indicating that this combination therapy could be a safe and

effective treatment strategy for severe cases of anti-NMDAR encephalitis.

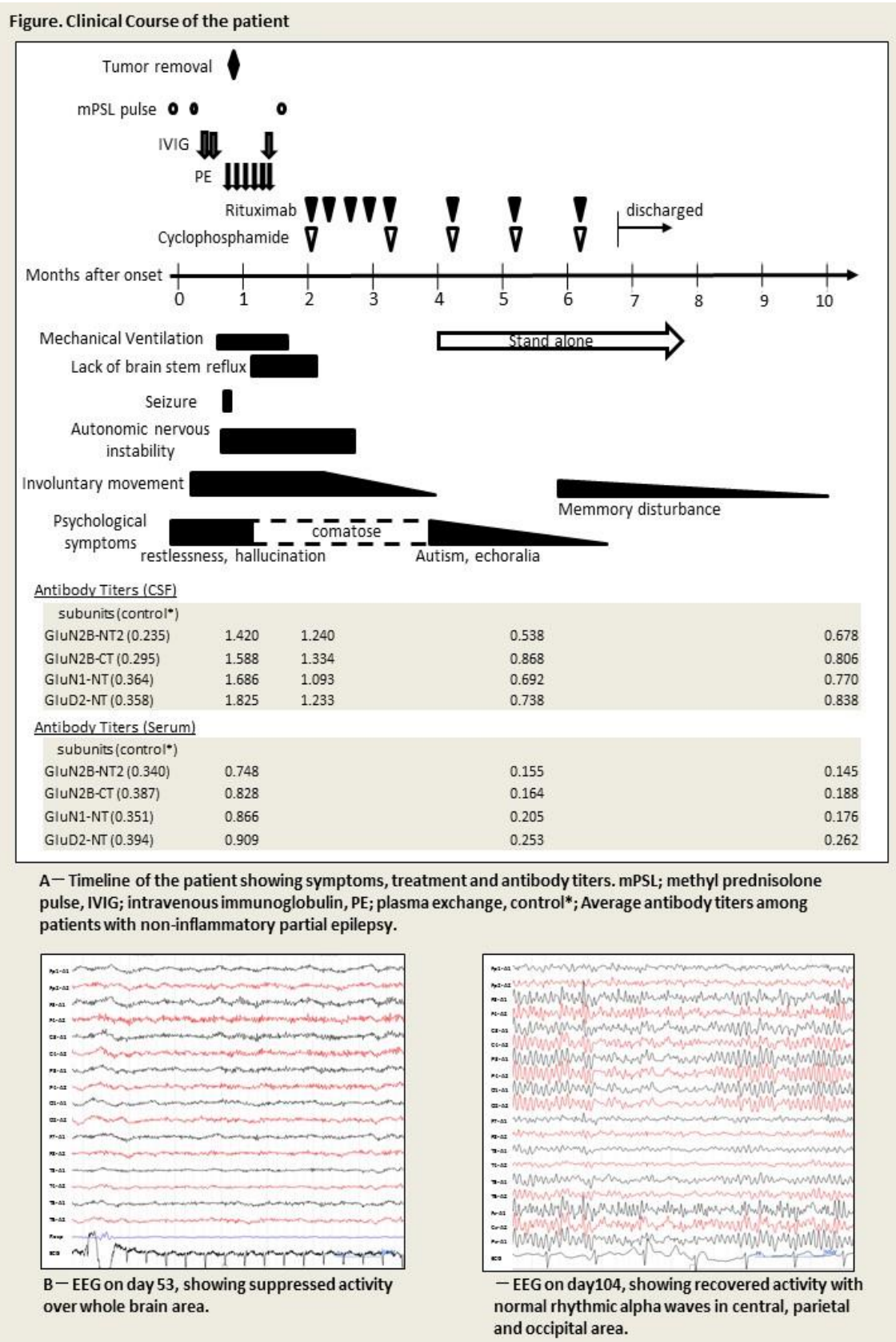
**5- CONFLICT OF INTEREST:** None.

#### 6- ACKNOWLEDGMENT

We are grateful to Thomas D. Mayers, Medical English Communications Center, University of Tsukuba, for grammatical revision of this paper.

#### 7- REFERENCES

1. Joseph D, Erdem T, Hai-yan W, Jaime M, Jeffrey E. R, Alfredo V, et al. Paraneoplastic Anti-N-methyl-D-aspartate Receptor Encephalitis Associated with Ovarian Teratoma. *Ann Neurol* 2007; 61(1): 25-36.
2. Titulaer MJ, McCracken L, Gabilondo I, Armangué T, Glaser C, Iizuka T, et al. Treatment and prognostic factors for long-term outcome in patients with anti-NMDA receptor encephalitis: an observational cohort study. *Lancet Neurol*. 2013; 12:157-65.
3. Takano S, Takahashi Y, Kishi H, Taguchi Y, Takashima S, Tanaka K, et al. Detection of autoantibody against extracellular epitopes of N-methyl-D-aspartate receptor by cell-based assay. *Neurosci Res*. 2011; 71(3):294-302.
4. Dalmau J, Lancaster E, Martinez-Hernandez E, Rosenfeld M, Balice-Gordon R, et al. Clinical experience and laboratory investigations in patients with anti-NMDAR encephalitis. *Lancet Neurol*. 2011; 10(1):63-74.
5. Charlotte Sommeling, Patrick Santens. Anti-N-methyl-D-aspartate (anti-NMDA) receptor antibody encephalitis in a male adolescent with a large mediastinal teratoma. *J Child Neurol*. 2014; 29(5):688-90.
6. Dale RC, Brilot F, Duffy LV, Twilt M, Waldman AT, Narula S, et al. Utility and safety of rituximab in pediatric autoimmune and inflammatory CNS disease. *Neurology* 2014; 83(2):142-50.



**Fig.1:** Clinical course of the patient.