

## A Novel Experience in Treatment of Liver Hydatidosis in Pediatrics: A Clinical Trial Study

Marjan Joodi<sup>1</sup>, Ali Alamdaran<sup>1</sup>, Elham Bazrafshan<sup>1</sup>, Morteza Peyvandi<sup>1</sup>, Mehdi Fathi<sup>1</sup>, Reza Nazarzadeh<sup>1</sup>, Elmira Zohorian<sup>1</sup>, Aghigh Ziaee-mehr<sup>1</sup>, Farideh Jamali-Behnam<sup>1</sup>, Amir mohammad Dalili<sup>2</sup>, Mahdi Parvizi- Mashhadi<sup>1</sup>, Khalil Alizadeh<sup>1</sup>, \*Ali Azadmand<sup>1</sup>

<sup>1</sup>Surgical Oncology Research Center, School of Medicine, Mashhad University of Medical Sciences, Mashhad, Iran. <sup>2</sup>Medical Student, School of Medicine, Mashhad University of Medical Sciences, Mashhad, Iran.

### Abstract

#### Background

Hydatidosis is a conventional health public problem in most parts of the world. Safe treatment of patients with hydatidosis has been a topic of debate for a long time. Surgical treatment always was associated with high morbidity and mortality. Medical treatment is also controversial. In this study, alternative procedure named Percutaneous, Aspiration and hypertonic Saline Instillation (PAHSI) was applied to treat patients with hydatidosis.

#### Materials and Methods

In this single-blind clinical trial, thirty-eight patients, ranging in age between 6 months and 16 years, with 81 hepatic hydatid cysts underwent PAHSI treatment. The consecutive steps including sonographic guidance, aspiration of cyst content and injection of 15% saline hypertonic were carried out in this method. Patients with multiple cysts also were treated by this procedure.

#### Results

Participants were 18 boys (47.3%) and 20 girls (52.6%) with mean age of  $8.08 \pm 3.92$  years. Almost half of the patients had single cyst (52.63%). During 2- year follow- up, no recurrences were observed; therefore, re-hospitalization and possible complications reduced considerably. Furthermore, this method was applicable to cure multiple cysts.

#### Conclusion

In PAHSI strategy, it seems that the complications of surgery (laparotomy and anesthesia) decreased since no complications observed after procedure, and cosmetic results in future are much better due to avoidance of incision.

**Key Words:** Children, Clinical Trial Study, Hydatidosis, Iran, Treatment.

\*Please cite this article as: Joudi M, Alamdaran A, Bazrafshan E, Peyvandi M, Fathi M, Nazarzadeh R, et al. A Novel Experience in Treatment of Liver Hydatidosis in Pediatrics. Int J Pediatr 2017; 5(10): 5945-52. DOI: **10.22038/ijp.2016.7998**

#### \*Corresponding Author:

Ali Azadmand, Surgical Oncology Research Center, School of Medicine, Mashhad University of Medical Sciences, Mashhad, Iran.

Email:Azadmanda931@mums.ac.ir

Received date: Dec.11, 2016; Accepted date: Aug. 12, 2017

## 1- INTRODUCTION

Hydatidosis or echinococcosis is a parasitic disease caused by the larval form of the tapeworm genus *Echinococcus* (1). Humans become infected by oral intake of cestodes eggs (diameter 40  $\mu\text{m}$ ) through hands, food, drinks, or other materials contaminated with canid feces. The larvae reach the blood and lymphatic circulation and are transported to the liver, lungs, and other organs where they develop into a hydatid cyst (2). The commonest areas where hydatid cyst develop including Mediterranean countries, New Zealand, Australia, North America, South America, Central America, and Asia (3). It is still a major public health problem in areas where hydatid disease is endemic (4).

Most individuals who are in touch with this parasite are young, and a large number of patients are less than 40 years of age. The hydatid cysts mostly affects the liver (70%), followed by the lungs (20%) (1). Sometimes no sign of disease is observed, but sometimes the disease may lead to severe complications and eventually death (5). The major adverse effects of the cyst are rupture into the peritoneal cavity, infection, compression of or communication with the biliary tree, anaphylaxis, and secondary hydatidosis.

Early diagnosis and appropriate therapeutic strategy will help to reduce the complication rate and prevent recurrence. Some available approaches for managing cystic echinococcosis (CE), include surgery, percutaneous management (puncture, aspiration, injection, and respiration), medical therapy, and observation (6). For many years surgery is the recommended effective therapy despite having relatively high morbidity, relapse and mortality rates (7). Medical treatment is another choice to treatment of hydatid cyst. Benzimidazoles carbamates were proven to be effective against larval stage of *Echinococcus granulosus* and later, mebendazole (Vermox), and albendazole

(Albenza), have been vastly applied for the therapy of hydatid cysts (8). In 1980s, accidental punctures of abdominal hydatid cysts with no severe complications reported in different studies led to deliberate puncture of abdominal hydatid cysts followed by injection of a scolical agent for hydatid cyst which became known as puncture, aspiration, injection, and respiration (PAIR) (9). PAIR as a safe technique is confirmed by the outcomes of more than 2,500 cases treated in several regions of the world and low morbidity (4.1%), and mortality (0.08%) rates were reported (10).

Other privileges of this technique are the comfort for the patient, significantly shorter hospital stay and its feasibility in areas with poor equipments compared with surgery (11). The reason why we didn't perform PAIR was we couldn't reaspirate the scolical material (hyper tonic saline) after instillation and decided to redo the pair again next week, but after a week we found accidentally that the cysts instilled before leading to parasites killing and shrinkage of the cysts without any complications arose. This strategy enables us to reduce the procedure and anesthesia duration, especially in patients with multiple cysts. Additionally, during reaspiration the possibility of leakage to adjacent organs is limited. Thus, we decided to do Percutaneous, Aspiration and hypertonic Saline Instillation (PAHSI) instead of PAIR procedure and investigate the short and long term outcomes and any possible complications. This technique has not been carried out in any studies yet and was conducted for the first time by the authors. The aim of this study was to evaluate the treatment of liver hydatidosis in 38 patients aged 6 months to 16 years with (PAHSI) method and compare the results with other reports.

## 2- MATERIALS AND METHODS

### 2-1. Study design and Procedure

In this single-blind clinical trial, from June 2013 to Jan 2016, 38 patients (18 [47.4%] female and 20 [52.6%] male) less than 16 years of age, with 81 hepatic hydatid cysts underwent PAHSI and were followed-up 2 years. All patients were treated in Dr Sheikh hospital located in Mashhad/Iran. Cases with hepatic hydatidosis were diagnosed on the basis of typical ultrasonographic findings that revealing double layered unilocular or multilocular cysts in the liver. The cyst volume was measured by sonography and registered. Then, aspiration of cyst content was carried out. First, Prophylactic albendazole treatment was given before the procedures for two weeks. Percutaneous drainage was performed under general anesthesia and continuous ultrasonographic guidance with close monitoring for complications, such as anaphylaxis, bronchospasm, and laryngeal edema. The procedure was typically performed for only unilocular cysts with puncture by an 18 gauge needle (gray angiocath or shiba needle). In this minimally invasive method, a needle is introduced into the cyst under ultrasound guidance (Esoate. Mylab50).

After cyst suction, for non-biliary secretions, saline hypertonic 15% was injected after aspiration of total cyst volume under sonographic guidance. We tried to equalize the cyst volume that was aspirated and injected saline 15%. These volumes were practically matched together. Only hypertonic saline is used to wash out cyst contents and to kill scolices. The real-time sonography shows a gradual decrease in cyst size and separation of the endocyst (germinal layer) from the pericyst (**Figure.1**). On the third postoperative day, the patients discharged. After drainage of univesicular cysts, oral albendazole continued for three month.

## 2.2. End point

In this technique, we tried to reduce the duration of PAIR procedure by elimination

of further reaspiration. Furthermore, application of a method with less complication was attempted.

## 2-3. Statistical analysis

Data were analyzed using SPSS software version 20.0. Frequencies, percentage, mean and standard deviation (SD) were determined in this research. In this study, non-probability sampling was used and all patients with hydatidosis who had the inclusion criteria were studied.

## 2-4. Participant

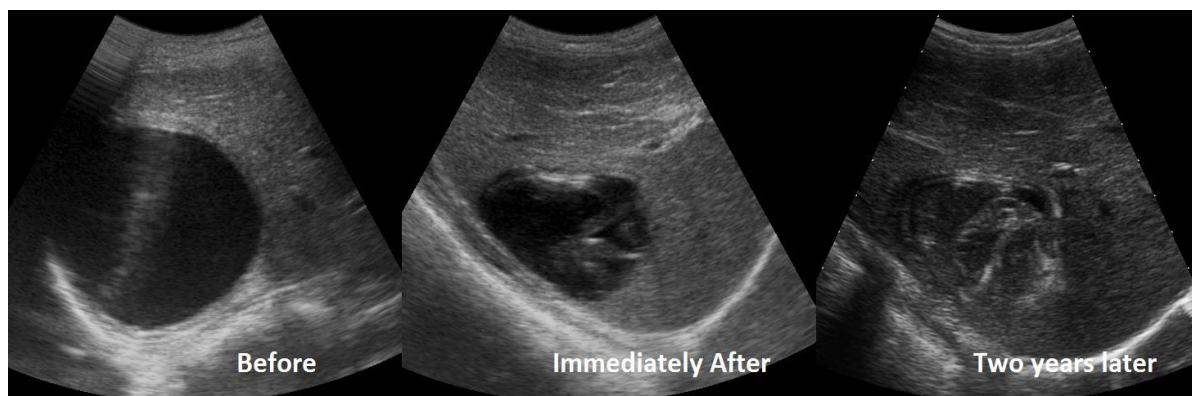
All the patients with active unilocular hepatic hydatidosis were included in the study. Patients that underwent PAIR procedure and whom didn't agree to participate in the PAHSI trial despite of enough explanation were excluded from the study.

## 2-5. Follow-up

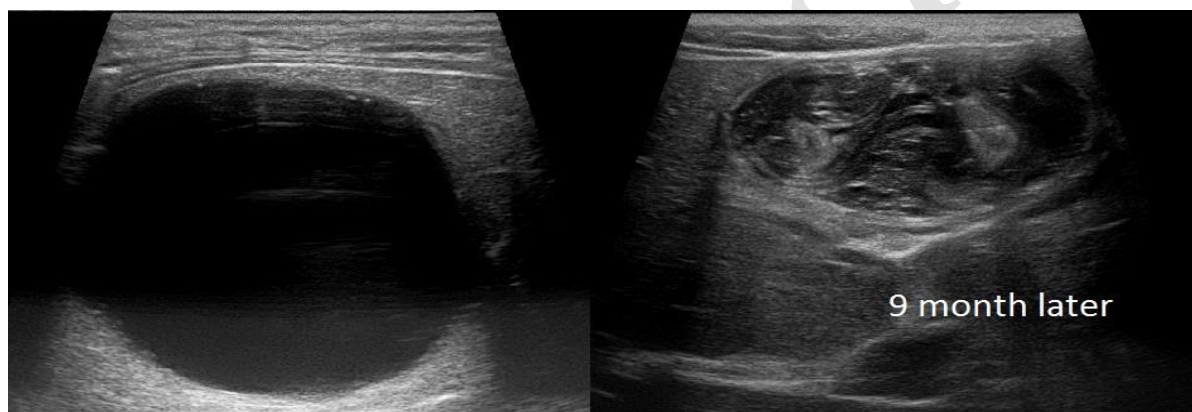
After completing the procedure, follow up started. Our patients' follow up was done from 2013-2016 in Dr. Sheikh pediatric hospital, Mashhad-Iran, by a consultant pediatric surgeon and radiologist intervention. Follow-up ultrasounds were performed in the first and third days, 1 weeks and then at 1, 3, 6, 9, 12, 24 months for patients. Signs of inactive cyst were decreased in the dimensions of the cysts, solid contents of cyst, and irregularity in the walls of cysts and separation of endocyst from pericyst (**Figure.2**). None of the treated cysts disappeared completely.

## 2-6. Ethical consideration

The research proposal was investigated in ethical committee of Mashhad University of Medical Sciences/Iran (ethical ID- code: 1386.131). This study was also registered on the Thai clinical trial site (TCTR.20170821006 ). Participation in the trial was totally optional after explaining the treatment modalities and success rates to the parents.



**Fig.1:** Pre-procedural ultrasonography showed unilocular liver hydatid cyst. Immediately after procedure, detached endocyst and its collapsed wall is shown and after two years later, solid inactive cyst is seen.



**Fig.2:** Pre-procedural ultrasound shows univesicular hydatid cyst of left lobe of liver. In 9 months after PAHSI procedure, solid residual hydatid cyst with detached wall is seen.

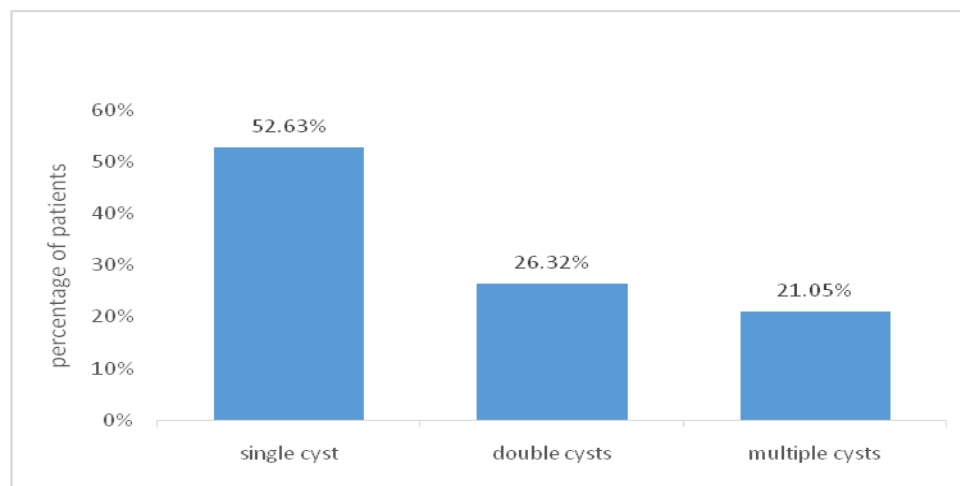
### 3-RESULTS

In this study, 38 patients underwent PAHSI treatment. The group consisted of 18 (47.4%) boys (47.3%) and 20 girls (52.6%) ranging in age between 6 months to 16 years with an average age of  $8.08 \pm 3.92$  years. A total of 81 cysts were present in 38 patients. Cysts were found in the range of 23 to 199 mm. Nineteen patients (52.63%), had only one cyst, ten patients (26.32%), with two cysts and in the remaining 9 patients (21.05%), multiple cysts (3-11cysts) were recognized **Table.1** and **Figure.3**. In this method of treatment,

incision was avoided. It seems that complications of open surgery were not detected. In other words, the patients suffered less pain, infection and adhesion compared to open surgery since we considered size decreasing and shrinkage of the cysts until 2 years and no recurrence evidence was established. No complication is either seen. Success rate during the 2 years follow up was 100% and no active cyst was found. Other notable results of this study were the short hospital stay, lower cost, simplicity and the comfort for the patient.

**Table-1:** Results of treatment of 81 hepatic hydatid cysts with Percutaneous, Aspiration and hypertonic Saline Instillation (PAHSI) method in patients infected with Echinococcus granulosus

Number	Gender	Age	Cyst number	The diameter of biggest cyst (mm)
1	Female	8	1	23
2	Male	13	4 (active cysts) 2(in-active cysts)	85 27
3	Male	4	2	36
4	Female	6	1	-
5	Female	6	1	55
6	Male	8	1	55
7	Male	13	1	199
8	Female	13	2	105
9	Male	9	1	-
10	Female	11	11	45
11	Male	7	3	52
12	Female	13	1	107
13	Male	12	2	113
14	Male	6-month	2	72
15	Female	6	5	100
16	Female	7	1	65
17	Male	9	1	-
18	Female	11	1	45
19	Male	10	5	37
20	Male	8	2	96
21	Female	6	4	88
22	Male	13	2	32
23	Male	14	2	37
24	Female	13	1	47
25	Male	12	1	82
26	Female	9	2	90
27	Male	6	2	83
28	Male	7	2	80
29	Male	8	4	38
30	Female	3	1	124
31	Male	1	1	89
32	Female	1	3	83
33	Male	2	1	120
34	Female	11	1	91
35	Male	12	1	89
36	Female	1	1	51
37	Female	1	1	28
38	Female	1	1	38



**Fig. 3:** Percentage of patients with different number of cysts.

#### 4- DISCUSSION

Although hydatidosis has been eliminated in some regions, the disease remains endemic in some parts of the world, especially in developing countries (4). There are various studies all around the globe which investigate the hydatidosis in adults, but few studies focus on pediatric population. As is evident, a common therapeutic method against hydatidosis, is surgery which has been associated with a considerable morbidity and mortality (0.3-7%), and recurrence rates (12). Fortunately, the advent of pair method overcomes such difficulties. The result of a study showed that in 355 patients with five hundred and ten hydatid liver cysts (HLCs), PAIR recurrence rate was 3.5% in comparison with recurrences rates of 16.2% and 3.3% for open and laparoscopic surgery, respectively (13).

In our study, PAHSI had the ability to treat multiple cysts; as a result, need for larger surgery such as segmentectomy or lobectomy was eliminated. Percutaneous treatment under sonographic guidance, PAIR, play an important role in the therapy of hydatid cyst and its efficacy has been proved both by short-and long term follow-ups (7). Goktay et al. reported that successful percutaneous treatment of

hepatic hydatid disease in 33 patients (97.1%) aged 4-17 years in 2005. During the follow-up of 1-6 years (mean, 3.1 years), there were no recurrences or additional lesions and the median hospital stay for the whole studied group was 3.5 days (14). In other words, if there are no complications in the patients treated percutaneously, the hospitalization period is almost 1 day (15). In present study, because of the safer characteristic of hypertonic solution compared to other solutions like ethyl alcohol, hydrogen peroxide, etc. this compound was used and no recurrences were observed (16).

In this method, sedation was used rather than general anesthesia; therefore, the complications of general anesthesia like possible hypoxia, brain apoptosis, cognitive disorders, etc. were disappeared. Acunas et al., published the results of percutaneous treatment with injection of hypertonic saline on 15 patients aged 11-56 years. No major complications occurred during or after the procedures. This method was detected as an effective and alternative method to surgical interventions to cure the disease (17). Bosanac et al. treated 55 HLCs in fifty-two patients aged 13-84 years and followed-up them for 6-9 years. The treatment of all patients was successful; however, only 3

patients showed a secondary infection, because of persistent catheter drainage (18). Another research studying the long term follow-up results of the percutaneous treatment of liver hydatid cysts in 1996 (mean follow-up: approximately 32.5 months), revealed that fifty seven cysts in 31 patients were treated (type I–III) by PAIR or catheterization methods. Just one recurrence took place in this study and was treated percutaneously (2%). Anaphylactic shock or abdominal dissemination was not seen and the minor complications were treated symptomatically (19).

## 5- CONCLUSION

The effectiveness of PAHSI method on pediatrics aged 6 months to 16 years was conducted for the first time in this study and led to good results. Based on analyzed results, the PAHSI method is identified an efficient, safe and acceptable method to totally cure this target group with a short hospitalization and no recurrences.

**6- CONFLICT OF INTEREST:** None.

## 7- REFERENCES

- Rossi UG, Rubis Passoni G, Cariati M. Hydatid cyst of the liver. *Revista de Gastroenterología de México (English Edition)* 2016;81(2):105-6.
- Biava M-P, Marie-France, Dao M, AHU, Anne, Fortier M, PU-PH, Bernard. Laboratory diagnosis of cystic hydatid disease. *World J Surg* 2001;25(1):10-4.
- Liang Q, Wen H, Yunus A, Tian Z, Jiang F, Song X. Treatment experiences of pelvic bone hydatidosis. *International Journal of Infectious Diseases* 2014;18:57-61.
- Anna Reddy D, Venkatarami Reddy V, Sivaramakrishna G, Chandramaliteeswaran C, Brahmeswara Rao M. Predictive factors for cystobiliary communication in hepatic hydatidosis: A 15 yr experience at a tertiary care institute in South India. *HPB* 2016;18(Supplement.1):e294.
- Sayek I, Yalin R, Sanaç Y. Surgical treatment of hydatid disease of the liver. *Archives of Surgery* 1980;115(7):847-50.
- Quail JF, Gramins DL, Dutton WD. Hydatidosis of the liver and posterior mediastinum. *International Journal of Surgery Case Reports* 2015;7:26-8.
- Baraket O, Moussa M, Ayed K, Kort B, Bouchoucha S. Predictive factors of morbidity after surgical treatment of hydatid cyst of the liver. *Arab Journal of Gastroenterology* 2014;15(3–4):119-22.
- González-Redondo R, DiCaudo C, García-García D, Zubieta JL, Viteri-Torres C. Spinal hydatidosis relapse related to albendazole withdrawal after 20-year treatment. *The Spine Journal* 2013;13(6):715-6.
- Pelaez V, Kugler C, Correa D, Del Carpio M, Guangiroli M, Molina J, et al. PAIR as percutaneous treatment of hydatid liver cysts. *Acta trop* 2000;75(2):197-202.
- Filice C, Brunetti E, Crippa F, Bruno R. Treatment of Echinococcal Abdominal Cysts. *Ultrasound quarterly* 1999;15(4):223-33.
- Nepalia S, Joshi A, Shende A, Sharma S. Management of echinococcosis. *JAPI* 2006;54:458-62.
- Giorgio A, Tarantino L, de Stefano G, Francica G, Mariniello N, Farella N, et al. Hydatid liver cyst: an 11-year experience of treatment with percutaneous aspiration and ethanol injection. *J Ultrasound Med* 2001;20(7):729-38.
- Giorgio A, Sarno AD, de Stefano G, Farella N, Matteucci P, Scognamiglio U, et al. Percutaneous treatment of hydatid liver cyst. *Recent Pat Antiinfect Drug Discov* 2009;4(1):29-36.
- Goktay AY, Secil M, Gulcu A, Hosgor M, Karaca I, Olguner M, et al. Percutaneous treatment of hydatid liver cysts in children as a primary treatment: long-term results. *J Vasc Interv Radiol* 2005;16(6):831-9.
- Akhan O, Özmen MN. Percutaneous treatment of liver hydatid cysts. *Eur J Radiol* 1999;32(1):76-85.

16. Besim H, Karayalcin K, Hamamci O, Güngör C, Korkmaz A. Scolicidal agents in hydatid cyst surgery. *HPB surg* 1998;10(6):347-51.

17. Acunas B, Rozanes I, Celik L, Minareci O, Acunas G, Alper A, et al. Purely cystic hydatid disease of the liver: treatment with percutaneous aspiration and injection of hypertonic saline. *Radiology* 1992;182(2):541-3.

18. Bosanac ZB, Lisanin L. Percutaneous drainage of hydatid cyst in the liver as a primary treatment: review of 52 consecutive cases with long-term follow-up. *Clin radiol* 2000;55(11):839-48.

19. Akhan O, Ozmen MN, Dincer A, Sayek I, Göçmen A. Liver hydatid disease: long-term results of percutaneous treatment. *Radiology* 1996;198(1):259-64.

Archive of SID