

Neuromyelitis Optica in Children: A Rare Entity

Shamsuddin Hassan¹, *Shyam Sundar Mina², Shobha Sharma³, Ajay Kumar³, Rhea Shriyan⁴

¹DNB, Pediatrician, Department of Pediatric, VMMC and Safdarjung Hospital, New Delhi, India.

²Assistant Professor, Department of Pediatrics, VMMC and Safdarjung Hospital, New Delhi, India.

³Professor, Department of Pediatrics, VMMC and Safdarjung Hospital, New Delhi, India.

⁴Post Graduate Resident, Department of Pediatrics, VMMC and Safdarjung Hospital, New Delhi, India.

Abstract

Neuromyelitis optica (also known as Devic's disease or Devic's syndrome) is an uncommon disorder in pediatric age group, and is characterized by acute or subacute optic neuritis and transverse myelitis. Here we report an 11- year- old female child with relapsing Neuromyelitis optica (NMO) confirmed by positive NMO- IgG antibody and had clinical recovery with high dose methyl prednisolone therapy.

Key Words: Children, Neuromyelitis optica, Optic neuritis, Transverse myelitis.

*Please cite this article as: Hassan Sh, Mina SS, Sharma Sh, Ajay Kumar, Shriyan4R. Neuromyelitis Optica in Children: A Rare Entity. Int J Pediatr 2017; 5(11): 6145-49. DOI: **10.22038/ijp.2017.25821.2202**

*Corresponding Author:

Dr. Shyam S. Mina, Assistant Professor, Deptt. of Pediatrics, VMMC and Safdarjung Hospital, New Delhi (110029); Tel: +91-9013677438

Email: dr.shyamsnmc2000@gmail.com

Received date: Aug.12, 2017; Accepted date: Sep. 12, 2017

1- INTRODUCTION

Neuromyelitis optica (also called Devic's disease) is a rare and aggressive inflammatory, demyelinating disease of the central nervous system that preferentially affects the optic nerves and spinal cord, simultaneously or consecutively, with monophasic or a relapsing course (1).

In pediatric age group, only a few cases of Neuromyelitis optica (NMO) with positive neuromyelitis optica immunoglobulin G antibody are reported till date. We present an 11- year- old female child with relapsing Neuromyelitis optica confirmed by positive Antibodies to aquaporin-4 (NMO-IgG or AQP4-Ab).

2- CASE REPORT

An 11- year- old female child presented with complains of acute onset painless diminution of vision in both eyes and sudden onset weakness of all four limbs without any bladder bowel incontinence. She had no recent history of trauma or any infectious illnesses. On examination she had normal higher mental functions, with finger counting present at 1 m in both the eyes. Fundus examination and rest of the cranial nerves were normal.

The power was symmetrically decreased to < 2.5 in all four limbs at all the joints in different range of motion, with decreased muscle tone. The deep tendon reflexes were absent in all the limbs, and the superficial reflexes were present. Babinski sign was negative bilaterally.

Pain, temperature and crude touch were impaired in upper limbs bilaterally. Rest of sensory examination including cortical sensations was within normal limits. Rest of the systemic examination was within normal limits. She had a similar episode one year back, for which she got treatment in some other hospital and was diagnosed as optic neuritis.

Initially we kept the possibility of some relapsing demyelinating disorder. For this we planned blood and radiological investigations. The routine blood investigations and Cerebrospinal fluid (CSF) analysis including oligoclonal bands were done which were within normal limits. The visual evoked potentials (VEP) showed decreased amplitude and delayed latencies bilaterally, suggestive of optic neuritis (**Figure.1**).

So, Magnetic resonance imaging (MRI) brain with orbit and spine were planned which showed T2 hyperintensities in proximal bilateral optic nerve with post contrast nodular enhancement in bilateral retrobulbar distal optic nerve (**Figure.2**). MRI spine also showed T2 hyperintense plaques at C2 and T2 involving central and peripheral cord with post contrast enhancement (**Figure.3**).

However, the MRI brain did not show any significant changes. To confirm the diagnosis as per the latest NMO Spectrum Disorder diagnostic criteria, the CSF anti aquaporin 4 antibodies were sent and found to be positive in titers 80 U/l (normal <3U/l) by immunofluorescence. After confirmation of diagnosis, the child was started on pulse methylprednisolone therapy for 5 days, followed by oral prednisolone (2 mg/kg/day).

After this the child's vision and power improved. After 2 weeks oral prednisolone was tapered to 1mg/kg/d, and oral Azathioprine was added at 2 weeks (2 mg/kg/day). Then the patient was discharged and advised follow up. She was able to walk independently, dress and eat herself, vision improved to 6/24 bilaterally.

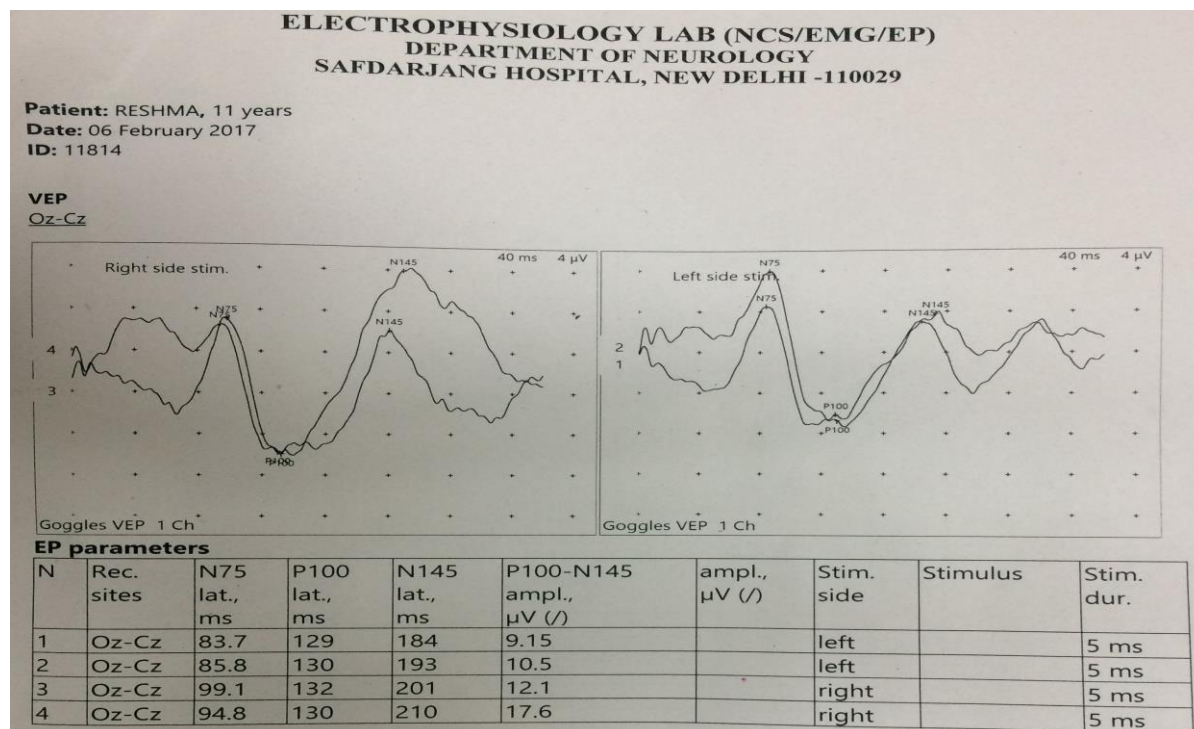


Fig.1: VEP study showing decreased amplitude and delayed latencies bilaterally, suggestive of optic neuritis.

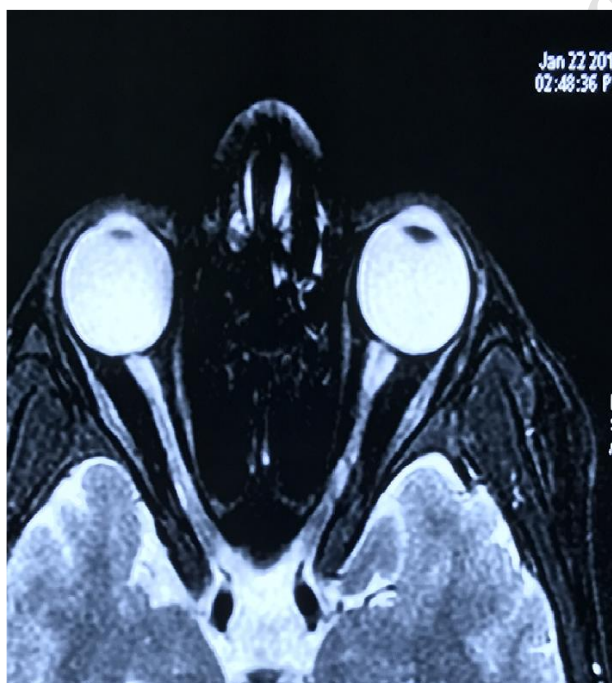

Fig.2: MRI Orbit T2 Hyperintensities in proximal bilateral optic nerve with post gadolinium contrast nodular enhancement in bilateral retrobulbar distal optic nerve.

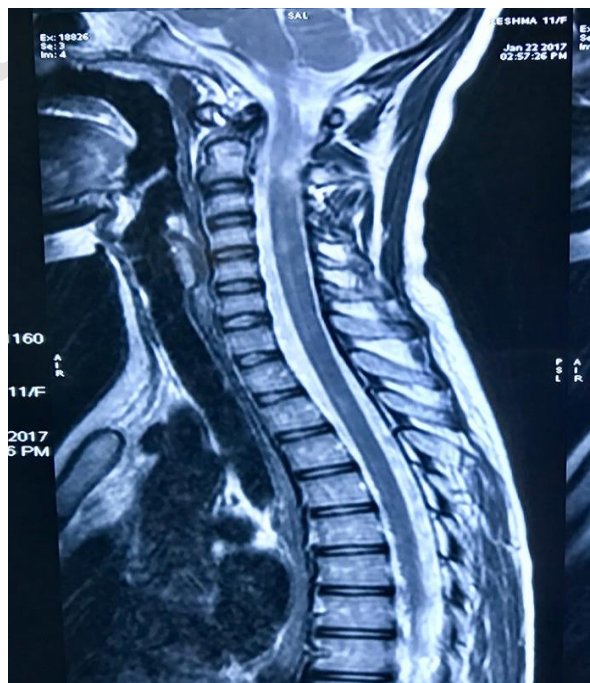

Fig.3: MRI Spine T2 Hyperintense plaques at C2 and T2 levels involving with central and peripheral cord with post gadolinium contrast enhancement.

3- DISCUSSION

Neuromyelitis optica is a rare disorder, the incidence and prevalence of which varies between populations and geographic region. The prevalence of NMO in children with demyelinating diseases varies between 3.2 to 8.5% (2). In both NMO as well as Multiple sclerosis (MS), the body's immune system attacks the myelin surrounding nerve cells. Unlike standard MS, the attacks are not believed to be mediated by the immune system T cells, but rather by antibodies called NMO-IgG. These antibodies target the protein aquaporin 4 in the cell membranes of astrocytes (within periventricular regions, brainstem, optic nerves, and spinal cord) which acts as a channel for the transport of water across the cell membrane (3).

Most of the cases of NMO are idiopathic. However, occasional familial as well as post infectious cases (associated with HIV, syphilis, chlamydia, varicella, cytomegalovirus, and Epstein-Barr virus) are also reported (4). Clinical course of NMO is variable. It may occur as a monophasic illness that is either fulminant and fatal or associated with varying degrees of recovery. Pediatric cases typically have a monophasic course and many have complete neurological recovery (5). Polyphasic courses characterized by relapses and remissions also occur.

The main symptoms include loss of vision and spinal cord function. Optic neuritis that is simultaneously bilateral may manifest as visual impairment with decreased visual acuity, although visual field defects, or loss of color vision may occur in isolation or prior to formal loss of acuity. Spinal cord dysfunction can lead to muscle weakness, reduced sensation, paroxysmal tonic spasms or loss of bladder and bowel control (6). In young children with relapsing disease and central lesions, multiple sclerosis may be a

diagnostic consideration. Our patient never developed symptoms implicating other CNS regions outside the optic nerves and spinal cord. More importantly, no NMO-IgG titers have been identified in cases of pediatric relapsing remitting multiple sclerosis (2). NMO-IgG was first discovered in 2004 and its seropositivity has shown significant correlation with relapsing NMO in several studies (7). Banwell et al. reported NMO-IgG seroprevalence in childhood inflammatory demyelinating disorders to be 78 % in children with relapsing NMO against 12.5% in monophasic cases (2). The patient reported herein has optic neuritis, as well as acute myelitis as core clinical characteristics along with positive NMO-IgG as per the latest Diagnostic criteria for NMO Spectrum Disorder (SD) with AQP4-IgG by Wingerchuk et al. (6).

MRI lesion patterns are a major arbiter of CNS demyelinating disease differential diagnosis. Several brain, optic nerve, and spinal cord patterns are characteristic or highly suggestive of NMO Spectrum Disorder. Detection of a longitudinally extensive transverse myelitis (LETM) spinal cord lesion associated with acute myelitis is the most specific neuroimaging characteristic of NMO SD and is very uncommon in adult with MS. Although the LETM pattern is characteristic of NMO SD, 7%–14% of initial and 8% of subsequent myelitis attacks in AQP4-IgG-seropositive patients do not meet the LETM definition (6).

Therefore, NMO SD must be considered in the differential diagnosis in patients presenting with short myelitis lesions. During optic neuritis attacks, increased signal within the optic nerve may be detected with fat suppressed T2-weighted orbital MRI sequences, typically with gadolinium enhancement seen on T1 weighted sequences. Bilateral optic nerve involvement, posterior nerve predominance (especially with extension

into the optic chiasm), or extensive lesions of the optic nerve (more than half of its length) are all suggestive of NMO Spectrum Disorder (6). Our case also had similar MRI findings (**Figures 1 and 2**). On MRI spinal cord, our patient had discrete T2 hyperintense plaques at C2 and T2 levels involving with central and peripheral cord with post contrast enhancement, unlike the typical LETM lesion described by Wingerchuk et al. This could be explained by the fact that occasionally the lesions of less than 3 segments are detected in NMO SD because the MRI was performed early in the evolution of acute myelitis or in clinical remission, during which a LETM lesion may fragment into discontinuous lesions (6). At this time, there is no established protocol for long term preventive immunotherapy for relapsing neuromyelitis optica (7).

Disability in NMO is attack-related, so early treatment is important for acute attacks as well as for prevention of relapses. Long term combination treatment with prednisone and azathioprine was reported to be beneficial in a small adult series (8). Other treatment options like interferons, and glatiramer acetate are not as effective as prophylaxis for relapsing neuromyelitis optica as they are for multiple sclerosis (9). In our case study, the patient appears to have responded well clinically to the combination of azathioprine and prednisone followed by azathioprine alone. Larger pediatric case series need to be conducted to evaluate the management issues in conjunction with clinical presentations, MRI findings, and response to therapies.

4- CONCLUSION

Neuromyelitis optica is a rare neurological disorder with an overall small number of patients in pediatric age group. Awareness to be created among General pediatric practitioner and pediatric

neurologists about this rare demyelinating disorder with a generally poor prognosis so that early detection and management is possible to limit the disabilities.

5- CONFLICT OF INTEREST: None.

6- ACKNOWLEDGMENT

We are grateful to Thomas D. Mayers, Medical English Communications Center, University of Tsukuba, for grammatical revision of this paper.

7- REFERENCES

Wingerchuk DM, Hogancamp WF, O'Brien PC, Weinshenker BG. The clinical course of neuromyelitis optica (Devic's syndrome). *Neurology* 1999; 53:1107-14.

1. Banwell B, Tenenbaum S, Lenn VA, Ursell E, Kennedy J, Bar-Or A, et al. Neuromyelitis optica-Immunoglobulin in childhood inflammatory demyelinating CNS disorders. *Neurology* 2008; 70: 344-52.
2. Wingerchuk DM. Neuromyelitis optica. *Int MS J* 2006; 13: 42-50.
3. Kliegman R, Stanton B, St. Geme JW, Schor NF, Behrman RE. *Nelson textbook of pediatrics* (Edition 20). Philadelphia, PA: Elsevier; 2016.
4. Cree BA, Goodin DS, Hauser SL. Neuromyelitis optica. *Semin Neurol.* 2002; 22: 105-22.
5. Wingerchuk DM, Banwell B, Bennett JL, Cabre P, Carroll W, Chitnis T, et al. International consensus diagnostic criteria for neuromyelitis optica spectrum disorders. *Neurology.* 2015; 85: 177-89.
6. Wingerchuk DM, Lennon VA, Lucchinetti CF, Pittock SJ, Weinshenker BG. The spectrum of neuromyelitis optica. *Lancet Neurol.* 2007; 6: 805-15.
7. Mandler RN, Waseem A, Dencoff JE. Devic's neuromyelitis optica: A prospective study of seven patients treated with prednisone and azathioprine. *Neurology* 1998; 51: 219-20.
8. Mandler RN. Neuromyelitis optica-Devic's syndrome, update. *Autoimmun Rev* 2006; 5: 537-43.