

Hip Joint Trevor Disease: Literature Review and a Case Report

Mohammad Hallaj Moghadam¹, *Ali Parsa^{2,3}, Mohammad Hassani⁴, Maryam Mirzaie⁵, Reza Habibzadeh Shojaei⁶

¹Orthopedic Research Center, Department of Orthopedic Surgery, Mashhad University of Medical Science, Mashhad, Iran.

²Rothman Orthopedic Institute at Thomas Jefferson university Hospital, Philadelphia, USA.

³Orthopedic Research Center, Department of Orthopedic Surgery, Mashhad University of Medical Science, Mashhad, Iran.

⁴Orthopedic Research Center, Department of Orthopedic Surgery, Mashhad University of Medical Science, Mashhad, Iran.

⁵Department of Community and Preventive Medicine, Mashhad University of Medical Sciences, Mashhad, Iran.

⁶Orthopedic Research Center, Department of Orthopedic Surgery, Mashhad University of Medical Science, Mashhad, Iran.

Abstract

Trevor disease or dysplasia epiphysealis hemimelica (DEH) is an extremely rare condition with incidence of about 1:1,000,000. Male to female ratio of reporting case is 3:1, and usually diagnosed between two and eight years old. It usually affects the medial portion of the joint, but lateral involvement is not uncommon. Hip-joint was affected in less than 4% of existing cases in the literature. It would be very important to precisely manage the hip involvement to prevent further articular cartilage destruction in this very young age.

We report an infant boy with isolated DEH of hip. We found a total of 271 cases of DEH that reported between 1926 and 2017. The most sites of involvement are ankle joint and around the knee. Our search reaches out to ten cases of hip involvement. Hip involvement needs a patient specified decision. We observed our patient for three years with a desirable hip joint function.

Key Words: Dysplasia epiphysealis hemimelica, Hip, Trevor disease.

*Please cite this article as: Hallaj Moghadam M, Parsa A, Hassani M, Mirzaie M, Habibzadeh Shojaei R. Hip Joint Trevor Disease: Literature Review and a Case Report. *Int J Pediatr* 2018; 6(1): 6809-14. DOI: **10.22038/ijp.2017.27224.2342**

*Corresponding Author:

Ali Parsa MD., Sheridan building 925s, 19107 Philadelphia, USA.

Email: aliparsadr@yahoo.com, Parsaa@mums.ac.ir

Received date: Oct.15, 2017; Accepted date: Dec.12, 2017

1- INTRODUCTION

Dysplasia epiphysealis hemimelica (DEH) was first named "tarsomegalie" by French surgeons Albert Mouchet and Joseph Belot in 1926 (1). Twenty four years later, in 1950, David Trevor fully described this disease and named it "Trevor syndrome"(2). Finally, in 1956, the name "dysplasia epiphysealis hemimelica" was proposed by Thomas John Fairbank due to the one-sided involvement reported in most cases (3). It is a very rare condition with an incidence

of about 1:1,000,000 (4). Azous et al. presented a classification for DEH based on 24 cases (**Table.1**) (5). Through an extensive search of Medline (via PubMed) and Google Scholar, we have found a total of 271 cases of DEH reported between 1926 and 2017. The most sites of involvement are at the ankle joint and around the knee. Trevor disease in the hip joint is extremely rare; fewer than 4% of reported patients have had hip involvement (**Table.2**).

Table-1: Azous classification of DEH (Dysplasia Epiphysialis Hemimelica) (5).

Localized	Single epiphysis involvement.
Classic	Unilateral involvement of more than one epiphysis (2/3 of cases).
Generalized	Whole limb involvement.

Table-2: Anatomic distribution of reported DEH in our literature review.

Location	Number (%)
Ankle	126 (46.3%)
Knee	79 (29%)
Upper extremity/Spine	37 (13.6%)
Foot	19 (7%)
Hip	11 (4.1%)

DEH: Dysplasia epiphysealis hemimelica.

2- CASE PRESENTATION

A 10-months male infant visited our outpatient clinic (Emam Reza Hospital, Mashhad University of Medical sciences) in Dec 2013 with limping in the left lower limb. There were no positive associated signs in the patient's medical history such as metabolic bone disease, trauma or family history of bone dysplasia. Infantile and neonatal history was normal and had no important illness. Physical examination revealed near normal hip range of motion and it was painful at extreme abduction and internal rotation. Pelvic X-ray showed left femoral head enlargement (**Figure-1**). Hip ultrasound was performed and

revealed hypertrophic epiphyseal cartilage without any excess fluid. The patient's major joints and long bones were again thoroughly examined for any other abnormalities. There was no history found of osteochondroma. The patient was evaluated sequentially for one year. At the age of two years magnetic resonance imaging (MRI) scan of the hip was performed .It indicated hypertrophy of the cartilaginous femoral head without acetabular side involvement (**Figure-2**). With diagnosis of DEH a skeletal survey was done to find any other region involvement and it was negative. The patient had no pain so we described two different treatment options to the

family: surgical excision versus a non-operative alternative. They refused the surgical procedure. At the latest follow-up examination in February 2017, X-rays showed acceptable containment and the

femoral head shape was round (**Figure-3**). The patient had no limitation in activity and was feeling only pain sporadically.

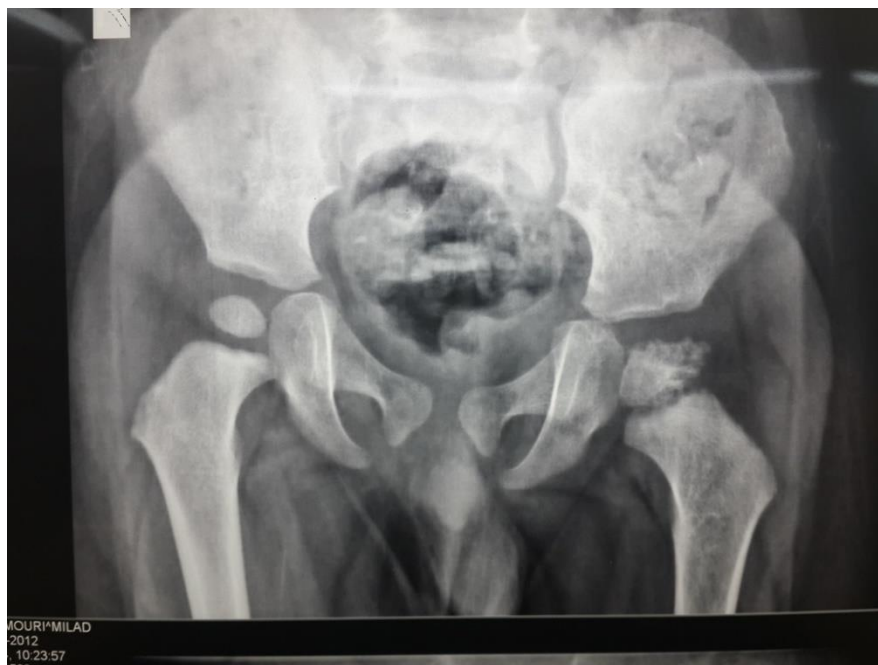

Fig.1: The Initial Pelvic X-ray. Right: normal, Left: femoral head enlargement.

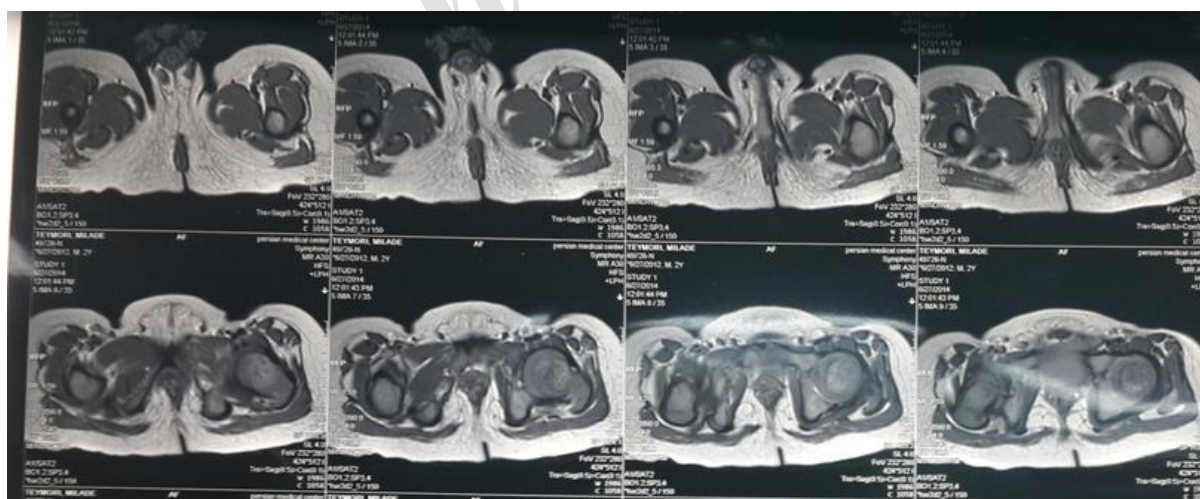


Fig.2: Hip MRI (shows thickened cartilaginous part of left femoral head).

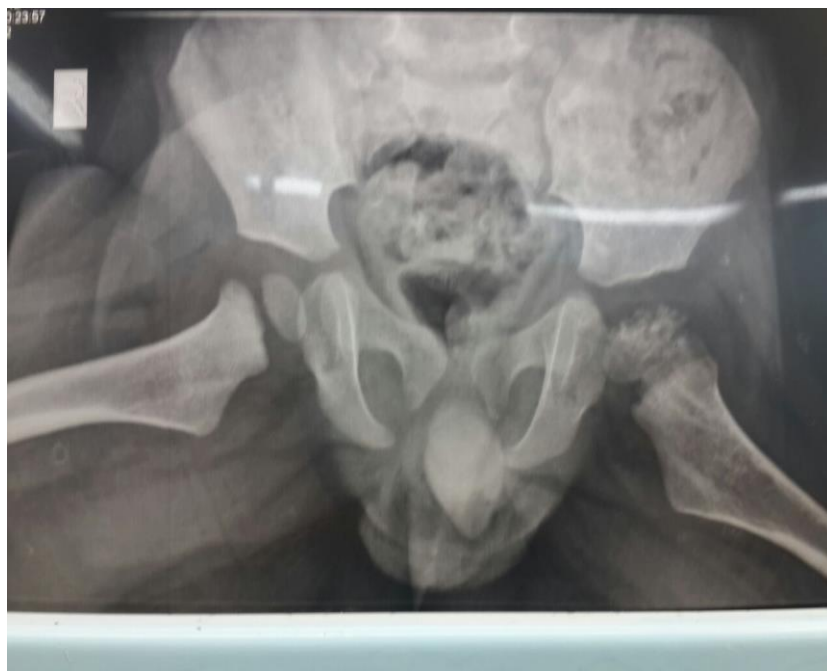

Fig.3: Follow-up X-ray pelvis anteroposterior.

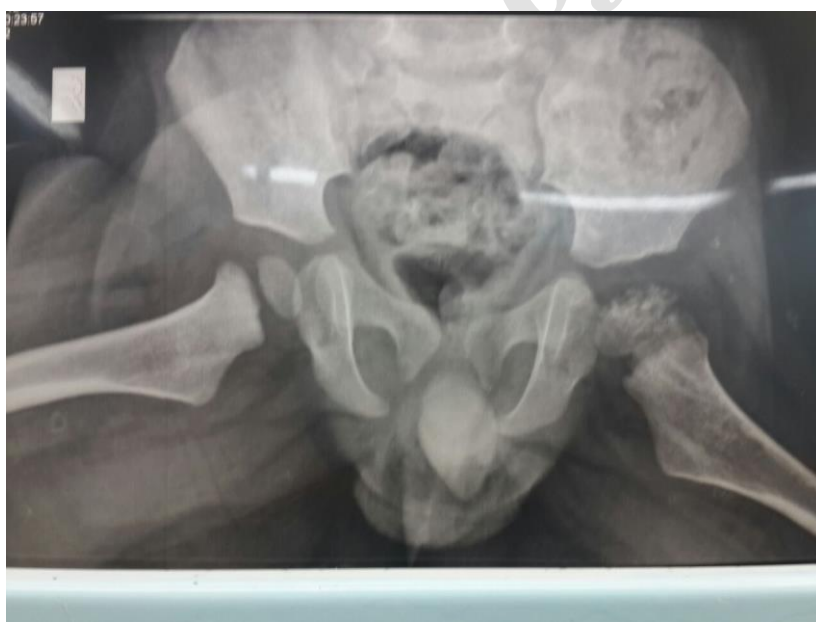

Fig.4: Follow-up X-ray frog-leg (containment is acceptable).

4- DISCUSSION

DEH is a rare benign disease that occurs with a frequency of one in a million, with no risk of malignancy. Overwhelmingly, only one limb and a single epiphysis are affected, but, rarely, multiple involvements within the same limb or, bilateral involvement is seen (6). DEH closely resembles osteochondroma. In fact, it particularly resembles osteochondroma in the physis (7). However, there are genetic differences between osteochondroma and Trevor syndrome. In fact, the EXT1 and EXT2 genes are normal in DEH, whereas in osteochondroma, the expression of these genes is lower due to genetic mutations (8). For diagnosis MRI and computed tomography are more helpful than radiography. Biopsy is the gold standard for the diagnosis of DEH (9).

The ankle is the most commonly affected joint but hip involvement is very rare. Trevor reported the first case; a three-year-old boy who had proximal femoral epiphysis involvement (2). We summarized all 10 earlier cases involving the hip, not including our patient with the type of treatment for each in **Table-3**. Most

manifestations of this disease are associated with pain. A common manifestation of this condition is reduced joint mobility. In our patient just a mild limping at early walking age was the only symptom. Eight of 10 reported cases of Trevor disease in the hip had a femoral head lesion and five had an acetabular lesion. No clear guidelines were presented concerning the treatment strategy for hip-joint Trevor disease. Four cases of hip-joint DEH were treated by surgical resection; of those, one experienced restricted postoperative range of motion in the hip and one had premature proximal femoral physeal closure. Some surgeons recommend observation for DEH cases that are not causing pain, femoral head and/or socket deformity or, interference with normal daily function. Due to the nature of these lesions which arise from the epiphyseal region, and articular surface involvement, surgical resection may lead to secondary arthritis that is more important in hip-joint (10). Kuo et al. recommend surgical excision only for symptomatic localized, peri-articular lesions. Post-operative degenerative joint changes occurred in two patients of their series (11).

Table-3: Descriptive data of reported cases with hip joint DEH.

Author (year)	Age (year)	Gender	Proximal femoral epiphysis	Acetabular cartilage	Other joints	Surgical excision	Outcome
Trevor (1950) ²	3	Male	+	-	+	-	Good
Fairbank(1956) ³	5	Male	+	-	+	-	N/A
Kettelkamp (1966) ¹²	4	Male	+	-	+	-	N/A
Merzoung (2002) ¹³	13	Male	+	+	+	-	N/A
Merzoung (2002) ¹³	0.2	Male	+	+	+	-	N/A
Tschauner (2004) ¹⁴	1	Male	+	+	+	+	Good
Linke (2005) ¹⁵	8	Male	-	+	-	+	Good
Rosero (2007) ¹⁶	18	Male	+	-	-	-	Good
Haddad (2008) ¹⁰	1.5	Male	+	-	+	+	Premature physeal closure
Wenger (2005) ⁷	7	Female	-	+	-	+	Restricted hip motion

DEH: Dysplasia epiphysealis hemimelica.

5- CONCLUSION

Based on existing reports and the outcome of our patient, we believed that in the case of early involvement of the hip joint with DEH, a "wait- and -see" strategy is a wise approach. Of course, close follow-up is needed to avoid any delay if surgical intervention does become necessary.

6- CONFLICT OF INTEREST: None.

7- REFERENCES

1. Rosero VM, Kiss S, Terebessy T, Köllö K, Szöke G. Dysplasia epiphysealis hemimelica (Trevor's disease): 7 of our own cases and a review of the literature. *Acta orthopaedica*. 2007; 78(6):856-61.
2. Trevor D. Tarso-epiphysialaclasis; a congenital error of epiphysial development. *J Bone Joint Surg Br*. 1950; 32-B(2):204-13.
3. Fairbank TJ. Dysplasia epiphysealishemimelica (taro-epiphyseal aclasis). *J Bone Joint Surg Br*. 1956; 38: 237-57.
4. Skaggs DL, Moon CN, Kay RM, Peterson HA. Dysplasia epiphysealis hemimelica of the acetabulum. A report of two cases. *J Bone Joint Surg*. 2000; 82-A: 409-14.
5. Azouz E., Slomic A, Marton D, Rigault P, Finidori G. The variable manifestations of dysplasia epiphysealis hemimelica. *Pediatric Radiology* 1985; 15(1): 44-9.
6. Kruger N, D. Thompson. Dysplasia epiphysealishemimelica: An interesting case report involving the talus and literature review. *SA Orthopaedic Journal* 2015; 14(2):43-7.
7. Wenger DR, Adamczyk MJ. Evaluation, imaging, histology and operative treatment for dysplasia epiphysealis hemimelica (Trevor disease) of the acetabulum: a case report and review. *The Iowa orthopaedic journal*. 2005; 25: 60.
8. Suh JH, Cho KH. Case report of imaging analyses of the dysplasia epiphysealishemimelica (Trevor's disease). *Journal of the Korean Society of Radiology* 2013; 69(2): 149-52.
9. Bosch C, Assi C, Louahem D, Alkar F, Mazeau P, Delfour C, et al. Diagnosis and surgical treatment of dysplasia epiphysealis hemimelica. A report of nine cases. *Orthopaedics and Traumatology: Surgery and Research*. 2014; 100(8):941-6.
10. Haddad F, Chemali R, Maalouf G. Dysplasia epiphysealis hemimelica with involvement of the hip and spine in a young girl. *Bone Joint Journal*. 2008; 90(7): 952-6.
11. Kuo RS, Bellemore MC, Monsell FP, Frawley K, Kozlowski K. Dysplasia epiphysealis hemimelica: clinical features and management. *Journal of Pediatric Orthopaedics*. 1998; 18(4):543-8.
12. Kettelkamp D, Campbell C, Bonfiglio M. Dysplasia epiphysealis hemimelica, a report of fifteen cases and a review of the literature. *J Bone Joint Surg (Am)* 1966; 48: 746-65.
13. Merzoug V, Wicard P, Dubousset J, Kalifa G. Bilateral dysplasia epiphysealis hemimelica: report of two cases. *Pediatr Radiol* 2002; 32: 431-4.
14. Tschauner C, Roth-Schiffel E, Mayer U. Early loss of hip containment in a child with dysplasia epiphysealis hemimelica. *Clin Orthop* 2004; (427): 213-9.
15. Linke L C, Buckup K, Klachs Schmidt K. Dysplasia epiphysealis hemimelica (Trevor's disease) of the acetabulum. *Arch Orthop Trauma Surg* 2005; 125: 193-6.
16. Rosero VM, Kiss S, Terebessy T, Köllö K, Szöke G. Dysplasia epiphysealis hemimelica (Trevor's disease): 7 of our own cases and a review of the literature. *Acta orthopaedica*. 2007; 78(6):856-61.