

A *CDH3* Mutation is Segregated in an Iranian Family with Congenital Hypotrichosis and Juvenile Macular Dystrophy

Soudeh Ghafouri-Fard¹, Majid Fardaei², Seyed Mohammad Bagher Tabei², Mehdi Dianatpour², *Mohammad Miryounesi³

¹Department of Medical Genetics, Shahid Beheshti University of Medical Sciences, Tehran, Iran.

²Department of Medical Genetics, Shiraz University of Medical Sciences, Shiraz, Iran.

³Genomic Research Center, Shahid Beheshti University of Medical Sciences, Tehran, Iran.

Abstract

Backgrounds

Hypotrichosis with juvenile macular dystrophy (HJMD) is a rare genetic disorder caused from mutations in the *Cadherin 3 (CDH3)* gene.

Results

In the present study, we reported an Iranian family with three affected members born to a consanguineous parent. Mutational analysis using whole exome sequencing has revealed a nucleotide change in *CDH3* gene (NM_001793:exon8:c.830delG) which leads to a frame-shift mutation (p.G277Afs*20). No intra-familial phenotypic variation was found.

Conclusion

Identification of disease-causing mutation in this family facilitated the effective genetic counseling and prenatal diagnosis.

Key Words: Cadherin-3, Gene, Mutation.

*Please cite this article as: Ghafouri-Fard S, Fardaei M, Bagher Tabei SM, Dianatpour M, Miryounesi M. A *CDH3* Mutation is Segregated in an Iranian Family with Congenital Hypotrichosis and Juvenile Macular Dystrophy. *Int J Pediatr* 2018; 6(1): 6999-7002. DOI: **10.22038/ijp.2017.27276.2350**

*Corresponding Author:

Mohammad Miryounesi, Genomic Research Center, Shahid Beheshti University of Medical Sciences, Tehran, Iran. Tel and Fax: 00982123872572

E- mail: miryounesi@razi.tums.ac.ir

Received date: Aug.10, 2017; Accepted date: Aug. 22, 2017

1- INTRODUCTION

Hypotrichosis with juvenile macular dystrophy (HJMD) is a rare genetic disorder caused from mutations in the *Cadherin 3 (CDH3)* gene which codes P-cadherin (1, 2). P-cadherin is expressed in retinal pigment epithelium (RPE) together with E-cadherin (3). The first report of co-occurrence of juvenile macular dystrophy and congenital hypotrichosis was published in 1935 (4). Afterwards, several cases of association between these two distinct phenotypes have been published (5-8). However, the underlying genetic cause was unclear till 2001 when Sprecher et al. through homozygosity mapping in four consanguineous families mapped the gene on chromosome 16q22.1 (1).

Mutation analysis of HJMD patients has resulted in identification of several *CHD3* mutations up to now. The first identified mutation has been a homozygous deletion in exon 8 of the *CDH3* gene (1). Subsequently, Indelman et al. detected a missense mutation (R503H) in all affected members of a family with HJMD (2). Afterwards, other mutations have been detected in *CHD3* gene in patients affected with HJMD from diverse ethnic backgrounds (9). Notably, *CDH3* mutations have also been associated with another syndrome consisted of hypotrichosis, macular dystrophy, ectodermal dysplasia and ectrodactyly (EEM Syndrome) (10). Here we present a consanguineous Iranian family with HJMD.

2- CASE REPORT

Here we present an Iranian family with three affected members referred to Shiraz Comprehensive Medical Genetics Center, Shiraz University of Medical Sciences, Iran. Their pedigree is presented in **Figure.1**. All three patients were full term

with no perinatal complications. All of them suffered from reduced visual acuity and hypotrichosis. They complained from progressive deterioration of visual function which was started from teenage years. Ophthalmologic examination with indirect ophthalmoscope had shown abnormalities in the posterior pole. Fundus examination demonstrated primary involvement of the macular region. The pattern of hair was normal at birth but hypotrichosis was apparent around 4 months of age. After puberty, they had fractional regrowth of short and thin hair. There was no other dermatologic complication apart from mild eczema. No developmental delay was reported in cases. No other abnormality has been detected in affected members.

In order to find the underlying mutation, DNA was extracted from blood samples of patients after obtaining written informed consent. Whole Exome Sequencing (WES) was carried out using paired-end sequencing method with 100X coverage in Illumina HiSeq4000 (Laboratory for Molecular Diagnosis, University of Leuven, Belgium). Afterwards, bioinformatics analysis of the sequencing data was performed using international databases and standard bioinformatics software. Combined Annotation Dependent Depletion (CADD) was used for scoring the deleteriousness of detected nucleotide changes (11). The detected mutation was confirmed by Sanger sequencing.

A homozygous mutation was found in *CDH3* gene (NM_001793:exon8:c.830delG) which leads to a frame-shift mutation (p.G277Afs*20) and is pathogenic based on ClinVar database (<https://www.ncbi.nlm.nih.gov/clinvar/>). As its CADD score is 34, it is predicted to be highly pathogenic.

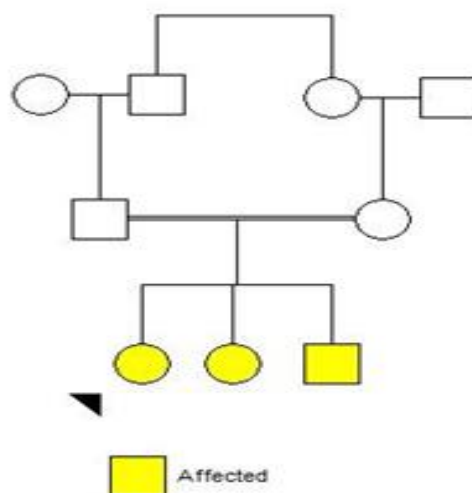


Fig.1: The family pedigree demonstrates three affected members.

3- DISCUSSION

We have detected a previously reported mutation in *CDH3* gene in an Iranian family affected with HJMD (NM_001793:exon8:c.830delG). This mutation leads to production of a truncated fusion protein with a premature stop codon at amino acid residue 295. This protein is predicted to be deficient in intracellular and membrane spanning domains as well as extracellular cadherin repeats (10).

Notably, it has been associated with both HJMD in a Turkish family (9) and EEM syndrome in a Brazilian family (10). A recent study has also confirmed the association of this mutation with inherited retinal disease using whole-genome sequencing (12). The patients presented in the current study, did not have characteristic features of ectodermal defect such as partial anodontia, absence deformities of digits, ectrodactyly and syndactyly (10) except for hypotrachosis. So, we describe them as having HJMD

rather than EEM syndrome. Future studies are needed to assess if these so-called distinct syndromes are the same disorder at diverse areas of a severity spectrum. In addition, the wide spectrum of phenotypes associated with a single mutation should be considered in genetic counseling of affected families as well as prenatal diagnosis.

4- CONCLUSION

Similar mutations might be associated with distinct phenotypes of HJMD and EEM syndrome. Gene-gene interactions or environmental factors might modulate the phenotypic characteristics in each family.

5- CONFLICT OF INTEREST: None.

6- ACKNOWLEDGMENT

The authors are grateful to the patient's family for their participation in the study.

7- REFERENCES

1. Sprecher E, Bergman R, Richard G, Lurie R, Shalev S, Petronius D, et al. Hypotrichosis with juvenile macular dystrophy is caused by a mutation in CDH3, encoding P-cadherin. *Nat Genet.* 2001 Oct;29(2):134-6. PubMed PMID: WOS:000171374100015. English.
2. Indelman M, Bergman R, Petronius D, Ciubutaro D, Sprecher E, Lurie R, et al. A missense mutation in CDH3, encoding P-cadherin, causes hypotrichosis with juvenile macular dystrophy. *Journal of investigative dermatology.* 2002;119(5):1210-3.
3. Burke JM, Cao F, Irving PE, Skumatz CM. Expression of E-cadherin by human retinal pigment epithelium: delayed expression in vitro. *Investigative ophthalmology & visual science.* 1999;40(12):2963-70.
4. Wagner H. Maculaaffektion, vergesellschaftet mit Haarabnormität von Lanugotypus, beide vielleicht angeboren bei zwei Geschwistern. *Graefe's Archive for Clinical and Experimental Ophthalmology.* 1935;134(1):74-81.
5. Marren P, Wilson C, Dawber R, Walshe M. Hereditary hypotrichosis (Marie-Unna type) and juvenile macular degeneration (Stargardt's maculopathy). *Clinical and experimental dermatology.* 1992;17(3):189-91.
6. Souied E, Amalric P, Chauvet M-L, Chevallier C, Hoang PL, Munnich A, et al. Unusual association of juvenile macular dystrophy with congenital hypotrichosis: occurrence in two siblings suggesting autosomal recessive inheritance. *Ophthalmic genetics.* 1995;16(1):11-5.
7. BJÖRK A, JAHNBERG P. Retinal dystrophy combined with alopecia. *Acta ophthalmologica.* 1975;53(5):781-9.
8. Jalili I. Cone-rod congenital amaurosis associated with congenital hypertrichosis: an autosomal recessive condition. *Journal of medical genetics.* 1989;26(8):504-10.
9. Indelman M, Hamel CP, Bergman R, Nischal KK, Thompson D, Surget MO, et al. Phenotypic diversity and mutation spectrum in hypotrichosis with juvenile macular dystrophy. *The Journal of investigative dermatology.* 2003 Nov;121(5):1217-20. PubMed PMID: 14708629. Epub 2004/01/08. eng.
10. Kjaer KW, Hansen L, Schwabe GC, Marques-de-Faria AP, Eiberg H, Mundlos S, et al. Distinct CDH3 mutations cause ectodermal dysplasia, ectrodactyly, macular dystrophy (EEM syndrome). *J Med Genet.* 2005 Apr;42(4):292-8. PubMed PMID: 15805154. Pubmed Central PMCID: PMC1736041. Epub 2005/04/05. eng.
11. Kircher M, Witten DM, Jain P, O'Roak BJ, Cooper GM, Shendure J. A general framework for estimating the relative pathogenicity of human genetic variants. *Nat Genet.* 2014 Mar;46(3):310-+. PubMed PMID: WOS:000332036700017. English.
12. Carss KJ, Arno G, Erwood M, Stephens J, Sanchis-Juan A, Hull S, et al. Comprehensive Rare Variant Analysis via Whole-Genome Sequencing to Determine the Molecular Pathology of Inherited Retinal Disease. *American journal of human genetics.* 2017 Jan 05;100(1):75-90. PubMed PMID: 28041643.