

Agenesis of Right Lung: A Rare Congenital Disorder

*Vasudha Nikam¹, Pramod Nagure²

¹Professor and Head of the Department of Anatomy; Dr. D.Y. Patil Medical College, DYPatil Education Society, Deemed to be University, Kasaba Bawada, Kolhapur, India.

²Consulting Radiologist, Eureka Diagnostics and Research Centre, Kolhapur, India.

Abstract

Pulmonary agenesis is a rare congenital anomaly in which there is absence of pulmonary parenchyma as well as its bold vessels. It is an unusual cause of respiratory distress in newborn. Unilateral agenesis of lung is often associated with other congenital anomalies. The condition may lead to diagnostic difficulties.

Right pulmonary agenesis has poor prognosis. Here we present a case of female child of one year with a history of recurrent chest infection, fever and respiratory distress and on investigations was diagnosed with right pulmonary agenesis.

Key Words: Congenital anomalies, India, Pulmonary agenesis, Opaque hemithorax.

*Please cite this article as: Nikam V, Nagure P. Agenesis of Right Lung: A Rare Congenital Disorder. Int J Pediatr 2018; 6(4): 7473-78. DOI: **10.22038/ijp.2018.29561.2593**

*Corresponding Author:

Dr. Vasudha Nikam, Postal address: A-1; Nirmal Prabha Residency, Vishalgadkar house compound, Nagala park, Kolhapur, Maharashtra state, India.

Email: drmsrezaii@yahoo.com

Received date: Dec.13, 2017; Accepted date: Feb. 22, 2018

1- INTRODUCTION

Agenesis of the lung is a rare developmental imperfection in which there is complete absence of one or both lungs and its bronchus (1, 2). This is rare type of deformity which can occur isolated or associated with other anomalies such as oesophageal atresia, trachea-oesophageal fistula, tracheal stenosis, cardiac malformations, musculoskeletal anomalies, anal atresia, horse shoe kidney, etc. Bilateral pulmonary agenesis is condition which is incapable of coexisting with life (3-5). This rare congenital anomaly present with respiratory distress. This respiratory distress is due to retention of bronchial secretions, inflammations and poor respiratory inspiratory capacity. Rarely lung agenesis may be associated with gastric duplication cysts, which gives rise to nausea, vomiting, hematemesis and pain in abdomen (6, 7).

Pulmonary agenesis leads to diagnostic difficulties. More than 50% of these patients die before the first five years of life. Few patients may remain asymptomatic in their entire life (8). In unilateral pulmonary agenesis, the right or left bronchus does not develop and there is absence of bronchi, parenchyma and pulmonary vessels. The origin of pulmonary agenesis is unknown and its prevalence including the bilateral and unilateral forms is 0.5- 1.0 per 1,000 live births (9). In unilateral pulmonary agenesis, the mortality rate in the neonatal period is about 50% especially if there are associated malformations especially cardiac anomalies (10).

Mortality rate is higher when there is agenesis of right lung. It may be greater due to mediastinal shift leading to tracheal compression (11). Agenesis of left lung is more common causing compensatory

growth of the remaining lung and its herniation into the contralateral hemithorax (12). This condition was first described by De Pozze in 1960; who was discovered it accidentally at the autopsy of an adult female in 1673. Munch Meyer in 1944 first diagnosed unilateral agenesis of lung clinically in 1885. From India the first case was reported by Muhamed in 1923 of a left sided pulmonary agenesis in a medicolegal autopsy. Subsequently a few more case reports have appeared and by 1977, over 200 cases of under development of lung have been reported (13-15). Genetic, teratogenic and mechanical factors have a bearing on the etiology (15).

Here we report a case of one year old female child with right pulmonary agenesis who presented recurrent chest infection and respiratory distress.

2- CASE REPORT

A one year old female child was admitted to a Pediatrician at Kolhapur, India, with chief complaints of fever, cough and expectoration. The parents also complained of breathlessness on exertion. No history of hemoptysis. On physical examination no gross abnormalities were noticed. Milestones were at normal pace.

On examination of respiratory system; on auscultation it was noticed that there was decreased respiratory sounds and decreased air entry on the right side. Percussion revealed dull node over the right thoracic cage. Other systems were normal. Lower respiratory tract infection and pneumonitis was suspected hence X-ray chest was advised. The X-ray chest revealed abnormal right hemithorax opacification with severe mediastinal shift towards right side (**Figure.1**).

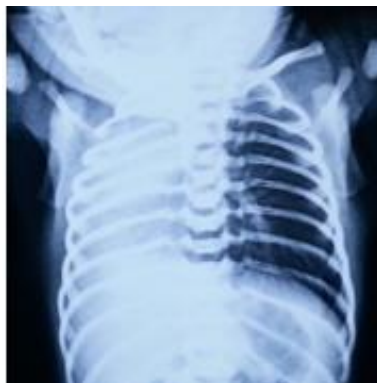

Fig.1: Frontal chest radiograph shows opacification of right hemithorax. Mediastinum appears to be deviated towards the right.

To rule out a perfect diagnosis Computerized Tomography was advised which showed agenesi

asymmetry of thorax; herniation of left lung towards affected side; hyperinflation of left lung was noticed (**Figures 2, 3**).

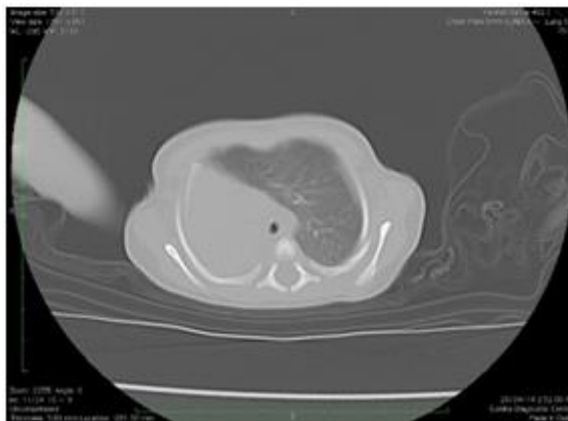


Fig.2: CT Axial Image shows compensatory hyperinflation of left lung which is crossing the midline.

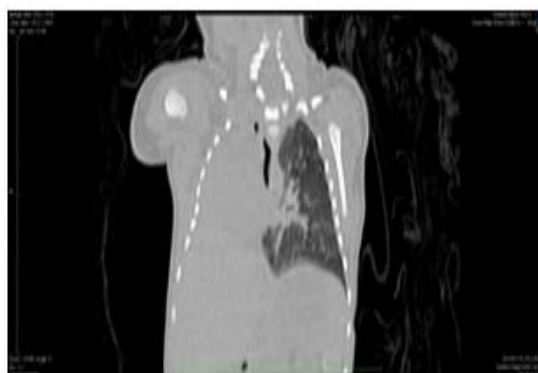

Fig.3: CT Axial Coronal Image in lung window. Mediastinum is displaced towards the right side.

Further to see the details of respiratory tract, CT Virtual Bronchoscopy was done (**Figure.4**) which revealed the absence of right bronchus and trachea was continued as left main bronchus. Patient had fever,

cough and breathlessness hence was treated with antibiotics and symptomatic drugs. Patient was advised for follow-up every 15 days to prevent any further complications.

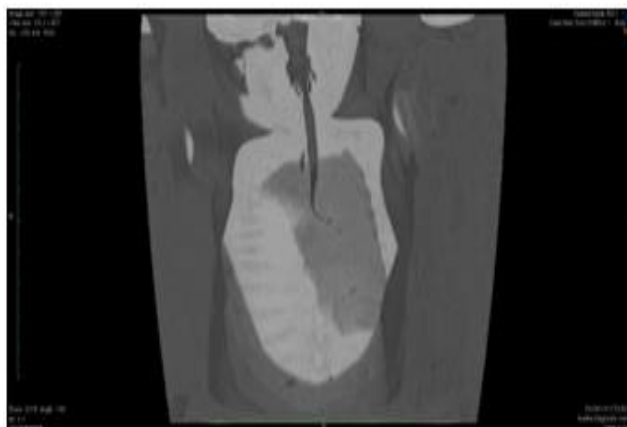


Fig.4: CT Virtual bronchoscopy images shows trachea as continuing the left main bronchus with aplasia of right main bronchus which is almost diagnostic of the condition

3- DISCUSSION

Agenesis of lung is a rare developmental defect in which there is complete absence of one or both lungs (1). Unilateral pulmonary agenesis is a rare disorder and about 200 cases have been reported in the current literature (2, 3). In our case there was right pulmonary agenesis. Left sided lung agenesis is prevalent in 70% cases and occurs more frequently in male patient (3). In our case there was right pulmonary agenesis in one year old female child. More than 50% of cases with pulmonary agenesis have associated congenital anomalies such as cardiovascular, skeletal, gastrointestinal and genitourinary (8, 16). In our case there was no any other congenital anomaly was noticed. In unilateral pulmonary agenesis the mortality rate in the neonatal period is approximately 50% especially if there are cardiac anomalies (10). But in our case no cardiac anomalies were seen. The mortality rate is higher when there is agenesis of right lung. This may be due to greater mediastinal shift leading to tracheal

compression (9). In our case also right pulmonary agenesis was diagnosed but there was no tracheal compression noticed. In many cases presence of such anomaly usually comes in picture due to recurrent chest infections (13). In our case also the child had recurrent chest infection and fever. However, patients with one lung have been reported to survive well in adulthood without much complaints and the oldest patient with such anomaly was of 72 years. May be left sided agenesis is more common and the subjects have a longer life expectancy than those with right sided agenesis (13, 17). This may be due to excessive mediastinal shift and malrotation of carina in right sided agenesis which impedes proper drainage of the functioning lung which adds the chances of respiratory infections (13, 15). In our case also there was mediastinal shift and recurrent chest infections. The developmental anomalies of lung can be classified into three groups according to the classification of Schneider and Schwalbe. It is as follows:

- a) Group-I-Agenesis; complete absence of bronchus, lung and pulmonary vessels.
- b) Group-II-Aplasia; rudimentary bronchus is present but there is no lung tissue and pulmonary vessels.
- c) Group-III-Hypoplasia; fully formed bronchus, lung hypoplasia and pulmonary vessels (14, 18).

Our patient was of type-I; Group I and Group II are for practical and developmental purposes, the same, there is no lung tissue and pulmonary vessels are absent on the affected side and main pulmonary artery sends its only branch to the existing lung. It appears that the existence of embryonic pulmonary tissue is important for the growth and the vascularization of pulmonary artery (19).

The age of presentation is inconstant and depends on the type of lesion present. Sometimes a solitary lesion may get detected in later year on routine X-ray done for the same other illness. Majority of patients presents with recurrent chest infections since early life (20). In our case also it was diagnosed at early age due to recurrent chest infection and respiratory distress. To manage such cases of pulmonary agenesis, cases which are asymptomatic needs no intervention but it is very important to prevent infection of solitary lung which when infected can be life threatening and should be treated as an emergency (21). In our case patient is advised for follow up for every 15 days and the infections are treated as an emergency.

4- CONCLUSION

Right sided pulmonary agenesis of lung without congenital anomalies is rarely seen and is diagnosed after birth. Asymptomatic patients have good prognosis; but keeping in mind right sided pulmonary agenesis which is thought to have poor prognosis which is consistent with our case; but

unlike other cases reported in literature the present case is not associated with any major congenital anomalies. Also, care should be taken with only one functioning lung which will remain always at a higher risk of infection leading to respiratory distress.

6- CONFLICT OF INTEREST: None.

7- ACKNOWLEDGMENT

Thanks to Chancellor, Vice Chancellor, Dean of the Medical College, and my colleagues, Dr. D.Y. Patil Medical College, Kolhapur, India.

8- REFERENCES

1. Mardini MK, Nyhan WL. Agenesis of the lung. Report of four patients with unusual anomalies. *Chest*. 1985; 87(4):522-7.
2. Tan KK, Chin CN. Unilateral pulmonary agenesis: an unusual cause of respiratory distress in the newborn *Singapore Med J*. 1996; 37(6):668-9.
3. Pavlovic Vesna, Stojanovic Vesna, Doronjski Aleksandra, Kovacevic Branka. Unilateral Agenesis of Lung Associated with Total Anomalous Pulmonary venous return and Atrial Septal Defect. *Central European Journal of Medicine* 2011; 6 (3); 353-55.
4. Nazaroglu H, Mete A, Bukte Y, Simsek M. Agenesis of the Right Lung presenting as a Pulmonary Infection; *Clinical Radiology*; 2002; 57: 529-30.
5. Sivanand G, Mukhophadyay S, Vashist S. An Unusual Cause of Recurrent Respiratory Tract Infection: Unilateral Pulmonary Agenesis; *European Journal of Radiology*. 2003; 48: 67-9.
6. Hemant Kumar, Arjun Bahadur, and Arun Kumar S. Bilodi. A Rare Case of Agenesis of Right Lung; *Indian Journal of medical case reports*. 2013; 2(3); 64-9.
7. Halilbasic A, Skokic F, Hotic N, Husaric E, Radoja G, Muratovic S, et al. Unilateral pulmonary agenesis and gastric duplication cyst; a rare association. *Case Reports in Pediatrics* 2013; 608-706.

8. Mir Sumsam Ali Khurram, Sundari Pratap Rao, Akkena Vamshipriya. Pulmonary Agenesis: A Case Report With Review of Literature. *Qatar Med J.* 2013; 2013(2): 38–40.9. Nandan d, Bhatt GC, Dewan V, Pongener I. Complete right lung agenesis with dextrocardia: an unusual cause of respiratory distress. *J Clin Imaging Sci.* 2012; 2: 81.
10. Eroglu A, aper F, Turkyilmaz A, karaoglanoglu N, Okur A. pulmonary agenesis associated with dextrocardia, sternal defects and ectopic kidney; *Pediatr Pulmonol* 2005; 40 (6): 547-9.
11. Nulma Souto Jentsch; Unilateral Pulmonary Agenesis. Letter to Editor. *Journal of Bras Pneumol* 2014; 40 (2): 322-24.
12. Alvarez AJ, Vaccaro MI, Verdejo HP, Villarroel CQ, Puentes RR. Unilateral Pulmonary Agenesis associated with multiple malformations-a case report. *Rev Chil Pediatr;* 2000; 71: 41-5.
13. Dyaneshwar, Ch. Sudhakara Babu. Left Lung Aplasia with Other Congenital Abnormalities: A Case Report. *International Journal of Pharma Medicine and Biological Sciences* 2013; 1-2 (4):34-6.
14. B Rajshekar, Sunil Gomber, Anurag Krihna. Pulmonary Agenesis; Brief Reports; *Indian Pediatrics* 1997; 34; 534-38.
15. I Safa Kaya, U Dilmen. Agenesis of the Lung. *Eur Respir J* 1989; 2: 690-92.
16. Sbokos C B, Mcmillan I R K. Agenesis of Lung; *Brit J of Chest* 1997; 3:183-97.
17. Oymada A, Gasul B M, Holinger P M. Agenesis of Lung; *Am J Dis Child* 1953; 85: 182-87.
18. Schneider P, Schwalbe E. Die Morphologie der Missbildungen des Menschen und der Thiere 1912; 3: pt-2; Jena: G, Fischer; 1912:812-22.
19. Smith RA, Bech AO. Agenesis of Lung. *Thorax.* 1958; 13(1):28-33.
20. Kresch MJ, Maxowitz RJ, Smith GJ. Respiratory distress and cyanosis in term newborn infant; *J Pediatr* 1988; 113: 937-43.
21. Singh U, Jhim D, Kumar S, Mittal V, Singh N, Gour H, et al. Unilateral agenesis of the lung: a rare entity. *Archives of Anesthesiology and Critical Care* 2016; 2(4):258-62.