

New-Onset Bacterial Sinusitis in Pediatric Liver Transplant Recipients; Case Series and Review of Literature

Naghi Dara¹, Farid Imanzade¹, *Amir Hossein Hosseini¹, Saleheh Tajalli², Seyed Mohsen Dehghani³, Ali Akbar Sayyari¹, Katayoun Khatami¹, Pejman Rohani¹, Roxana Azma⁴, Mitra Khalili⁴

¹Pediatric Gastroenterology, Hepatology and Nutrition Research Center, Research Institute for Children Health, Shahid Beheshti University of Medical Sciences, Tehran, Iran.

²Neonatal Health Research Center, Research Institute for Children Health, Mofid Children's Medical Center, Shahid Beheshti University of Medical Sciences, Tehran, Iran.

³Department of pediatric Gastroenterology and Hepatology, Nemazee Teaching Hospital, School Of Medicine, Shiraz University of Medical Sciences, Shiraz, Iran.

⁴Department of Radiology, Mofid Children's Medical Center, Shahid Beheshti University of Medical Sciences, Tehran, Iran.

Abstract

Background

As a standard measure in some chronic liver disorders, liver transplantation (LT) is being performed for about three decades in pediatric populations. In the post-operative period, some patients suffer from infectious complications by viral, bacterial, and fungal etiologies. Here we present 10 children diagnosed with bacterial sinusitis along with prolonged fever and upper respiratory tract symptoms post LT and review the literature.

Case Presentation

Ten pediatric LT recipients, including seven boys and three girls, aged 1.5 to 8 years (4.7 ± 2.34) with a mean weight of 15.6 ± 4.8 Kg (range; 11.4–27.5 Kg), were diagnosed with bacterial sinusitis from December 2013 to March 2017. The patients were suffering from respiratory symptoms and prolonged fever. After ruling out other diagnosis and by performing a thorough investigation, we confirmed bacterial sinusitis by sputum culture and antibiogram and paranasal computed tomography (CT) scan. All the patients dramatically responded to intravenous broad-spectrum antibiotics.

Conclusion

In the post-LT period, for patients suffering from fever or prolonged fever with upper respiratory signs and symptoms, acute sinusitis should be kept in mind. Therefore, timely diagnoses, coupled with therapeutic measures using broad-spectrum antibiotics, could prevent disease progression and complications.

Key Words: Children, Complications, Liver transplantation, Systematic review.

*Please cite this article as: Dara N, Imanzade F, Hosseini AH, Tajalli S, Dehghani SM, Sayyari AA, et al. New-Onset Bacterial Sinusitis in Pediatric Liver Transplant Recipients; Case Series and Review of Literature. Int J Pediatr 2018; 6(1): 7479-88. DOI: **10.22038/ijp.2017.27624.2387**

*Corresponding Author:

Amir Hossein Hoseini (M.D), Assistant Professor of Pediatric Gastroenterohepatology, Pediatric Gastroenterology, Hepatology and Nutrition Research Center, Research Institute for Children Health, Shahid Beheshti University of Medical Sciences, Tehran, Iran.

E-mail: ah_hosseini@sbmu.ac.ir

Received date: Nov.27, 2017; Accepted date: Dec. 22, 2017

1- INTRODUCTION

Pediatric LT is a standard lifesaving treatment in some chronic and debilitating liver diseases. LT has saved many children's lives in numerous healthcare centers around the world since the first LT was performed three decades ago. Improvements in surgical techniques, increase in the number of donors, advancement in preoperative and postoperative care, newer immunosuppressive regimens, and improvement in immunosuppressive strategies play a key role in reducing the odds of rejection (1). The most prevalent indications that should be strictly considered in children undergoing LT include cholestatic liver disease, chronic liver diseases with extrahepatic presentations such as Wilson's disease and autoimmune hepatitis, metabolic diseases treatable with LT, unresectable liver tumors (hepatoblastoma, hepatocellular carcinoma), and vascular anomalies leading to heart failure and acute liver failure (1-3). Over 50% of children undergoing LT suffer from biliary atresia, followed by metabolism-associated liver diseases. Not only does LT save the patient's life, but also modifies the disease phenotype. The success of LT depends on maintaining the transplanted graft function and preventing and treating post-LT complications including infections. Nevertheless, immunosuppressive medications render liver recipients susceptible to numerous post-LT infections at different time points (1).

Despite the extensive use of prophylactic antibiotic regimens, viral, bacterial, and fungal infections cause post-LT mortality and morbidity. Many factors contribute to increasing infection risks in this group of children. Children awaiting LT are susceptible to infections due to secondary immune deficiency. Moreover, infections can easily become problematic in these patients after LT due to immune system

suppression (2, 4). The failure to detect early and appropriately diagnose these infections can result in serious consequences for patients. Every LT recipient annually suffered 1.5 to 2.5 infections before the advent of new antibiotics and modern prophylactic regimens, and approximately 60%–80% of these patients experienced different infections (5, 6). Here we present 10 patients who underwent LT in Shiraz Transplant Center affiliated to the Shiraz University of Medical Sciences. These patients had fever and upper respiratory symptoms; they were referred to Mofid Children's Medical Center affiliated to the Shahid Beheshti University of Medical Sciences (Tehran, Iran) from December 2013 to March 2017. After ruling out other diseases by carefully consider their history and performing physical examination and paramedical modalities, these patients were ultimately labeled to have acute febrile pansinusitis and received intravenous antibiotic therapy.

2- MATERIALS AND METHOD

This is a prospective review of 10 patients treated for acute bacterial sinusitis following LT in children with liver diseases (**Table.1**) in a tertiary pediatric hospital (Mofid Children's Hospital, Tehran, Iran) (*Please see the table in the end of paper*).

The mean age and weight of the patients were 4.7 ± 2.34 (range: 1.5–8 years) and 15.58 ± 4.8 kg (range: 11.4–27.5 Kg) respectively. The mean body mass index (BMI) for patients aged over 2 years was 15.42 kg/m^2 , with a BMI Z-score range of 1.4–9.8. **Table.2** presents diagnoses leading to LT, anthropometric characteristics, and paraclinical findings in these children (*Please see the table in the end of paper*).

It should be emphasized that we have excluded other diseases such as viral infections (EBV and CMV) and fungemia

with quantitative real-time polymerase chain reaction (RT-PCR) and serum galactomannan respectively. Bone marrow aspiration/biopsy and radiological imaging (HRCT, Abdominal CT scan and bone survey) excluded post-transplant lymphoproliferative disorders. In addition, in otolaryngologist consultation, this procedure was highly recommended, but parents of the children declined this investigation. Appropriate antibiotic regimens were selected empirically in accordance with their general condition (hypotension, oral mucositis, and toxicity) and then were changed to sensitive antibiotics by considering the sputum culture result and antibiogram. The course of antibiotics completed for 14 to 21 days. The respiratory manifestation and general condition relived after a full course of antibiotics was received.

3- CASE REPORT

Patient 1

An eight-year-old male patient underwent LT due to Alpha-1 antitrypsin deficiency—this patient was presented with fever (oral temperature: 39°C), chills, diarrhea, vomiting, sweating, anorexia, headache, productive cough, vertigo, rhinorrhea, and redness around the eyes accompanied by submandibular lymphadenopathy. Examinations revealed thick postnasal discharge with maxillary bone tenderness and bilateral diffuse coarse rales; the tympanic membrane was inflamed bilaterally. Sinusitis was diagnosed through the CT scan of paranasal sinuses. The patient recovered after receiving a two-week intravenous antibiotic regimen (**Figure.1**).

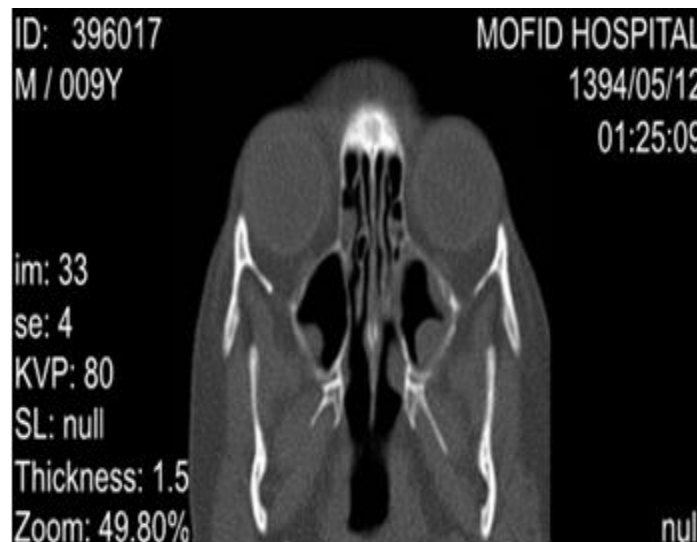


Fig.1: (case 1). Spiral CT scan of the Paranasal sinuses without IV contrast (axial view): Mucosal thickening of the bilateral ethmoid and maxillary sinuses with retention cysts in maxillary sinuses more on left side. Bilateral OMCS are obliterated.

3-1. Liver failure (Patients 2 and 3)

A four-year-old and a seven-year-old boys underwent LT for cryptogenic cirrhosis; they were presented with fever (oral temperature: 39°C), anorexia, tachypnea,

frontal headache, productive cough, and rhinorrhea. During the examination, they had high-grade fever, sore throat, thick postnasal discharge, and wheeze in both lungs.

Patient 4

A four-year-old girl underwent LT for cryptogenic cirrhosis and then was referred to our center with chills, fever (oral temperature: 39.5°C), respiratory distress, productive cough, frontal headache, and nasal congestion. She was ill and her respiratory rate was abnormally higher than the cut-off normal rates of her age. Examinations revealed thick postnasal discharge and purulent rhinorrhea. Also, she had nasal stiffness, exophthalmia, and proptosis. Ophthalmologist counseling ruled out orbital involvement.

Patient 5

An eight-year-old girl underwent LT for cryptogenic cirrhosis and was referred to our center with chills, fever (oral temperature: 39.4°C), productive cough, frontal headache, and malaise. She was tachypneic. Examinations revealed thick purulent postnasal discharge and rhinorrhea.

Patient 6

A girl aged three years and three months underwent LT for extra-hepatic biliary atresia (EHBA). She was presented with prolonged fever (oral temperature: 38.5°C) for more than three weeks, productive cough, rhinorrhea, anorexia, vomiting, and drowsiness. She was tachypneic. Examinations revealed nasal congestion, thick purulent postnasal discharge, and rhinorrhea. The tympanic membrane was red and inflamed bilaterally.

Patient 7

A two-year-old boy underwent LT for Crigler–Najjar syndrome type I; he was presented with fever (oral temperature: 38.2 °C), sore throat, productive cough, rhinorrhea, and diarrhea. He was tachypneic. Examinations revealed nasal congestion, thick purulent postnasal discharge, and rhinorrhea, with bilaterally harsh breathing sound and basilar rales (Figure.2).

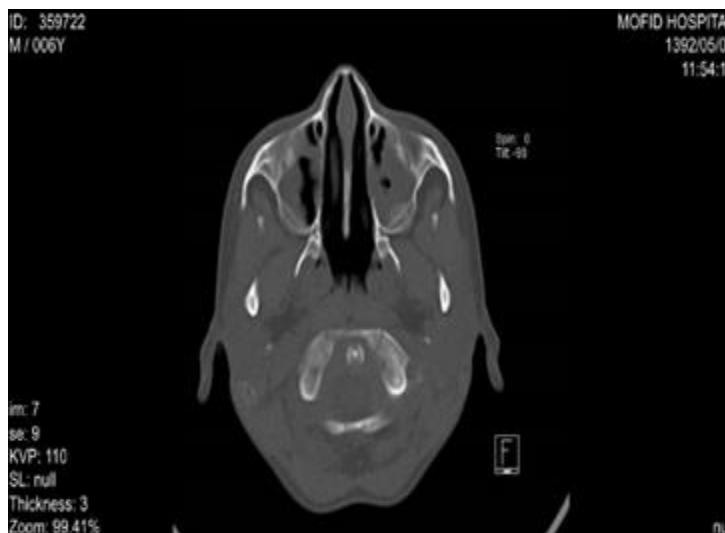

Fig.2: (case 8). Spiral CT scan of the Paranasal sinuses without IV contrast (axial view): Diffuse mucosal thickening in all paranasal sinuses, bilateral OMC is obliterated.

Patient 8

A boy of four years and three months underwent LT for hepatoblastoma. He was presented with chills, high-grade fever

(oral temperature: 39.8°C), lethargy, periorbital edema, productive cough, and rhinorrhea. He was ill and toxic. Examinations showed thick purulent postnasal discharge and exophthalmia.

Patient 9

A 5.5-year-old boy underwent LT for autoimmune hepatitis. This patient was presented with fever (oral temperature: 39.8 °C), productive cough, frontal headache, nasal discharge, diarrhea and anorexia. He was ill and tachypneic. Examinations showed throat congestion with thick purulent postnasal discharge.

Patient 10

An 18-month-old boy underwent LT for Crigler-Najjar syndrome type I. This patient presented with prolonged fever for one month (oral temperature: 39° C), productive cough, respiratory distress, drowsiness, and anorexia. Thick postnasal discharge and nasal mucosal erythema were found in examinations. It is worth noting that pre-transplant investigations indicated the absence of active and passive respiratory infections in all the patients.

4- DISCUSSION

The first successful Iranian LT was performed in Shiraz Organ Transplant Center in 1993. Advancement of the medical equipment and surgical techniques have saved many patients' lives in the last two decades. LT can currently be carried out in children less than 18 years with different indications. A total of 3,663 LT (2,760 adult and 903 children) have been carried out in Shiraz, Iran, since 1993. Many complications have been reported in these patients (**Table.3**) (*Please see the table in the end of paper*).

By considering the result of our prospective study, pansinusitis as an infection and a serious treatable complication should be considered in patients with prolonged fever and with or without other respiratory symptoms, particularly six months after transplantation. According to reports in scientific resources, infections contribute to more than half of post-LT mortality (4).

Diagnosing and treating active and passive infections is crucial in protocols for LT preparation (1, 7, 8). Post-transplant infections have been divided into early infections within the first 30 days after transplantation and infections in the long-term follow-up. About one-third of the patients suffer from infections within 30 days after transplantation (9, 10). These infections are mostly gram-negative aerobic with intestinal origins. However, anaerobic infections are uncommon. Other organisms, such as *Enterococcus* and *Staphylococcus*, isolated in the blood culture were also reported. Fungal infections are also very uncommon; they contribute to less than 8% of visceral rupture cases (10). Severe viral infections include cytomegalovirus (CMV), Epstein Barr Virus (EBV), and adenoviruses that typically emerge long after LT. CMVs account for 6% of all viral infections within the first 30 days after transplantation (9).

Most of the infections caused by EBV occur at least one month after transplantation (10, 11). In terms of the prevalence of post-transplantation infectious agents, 50%–60%, 20%–40%, 5%–15% of the infections are caused by bacterial, viral, and fungal agents respectively. Given that the maximum immunosuppression occurs in the first two months after LT, the risk of infection is maximum during this period (1, 9, 12, 13).

Infections rarely emerge after six months of LT and mostly involve patients with chronic rejection, vascular, or biliary complications as well as those needing re-transplantation (1, 7, 8). These late-onset infections mostly comprise urinary tract infection (UTI), community-acquired pneumonia, invasive pneumococcal disease, and varicella-zoster infections (8, 9). Antifungal and antiviral prophylactic regimens are currently used in these patients. Thus, bacterial pathogens are considered the most common infectious

problem in patients receiving LT (14-16). In the broad literature review (Cochrane, PubMed, Clinical key, and Google Scholar), acute bacterial sinusitis is not reported in post-LT recipients. Here, just like the first series, we reported 10 cases of acute bacterial sinusitis in post-LT recipients. Children are more vulnerable than adults to recurrent infections of upper and lower respiratory tracts, and primary and acquired immune deficiency increases the risk of these infections. Therefore, timely diagnosis, coupled with therapeutic measures using broad-spectrum antibiotics, reduce the intensity. It also prevents the disease progression and complications such as pneumonia, severe sepsis, liver abscesses, transplant rejection, and ultimately, morbidity and mortality. Although pansinusitis is a common infectious problem in pediatric age groups, it is not considered as a significant problem in post-LT period. Here we report this case series to highlight the importance of this entity. One of limitations of our study is the lack of sinuscopy and fluid culture.

5- CONCLUSIONS

In conclusion, investigating respiratory system infections, febrile acute sinusitis, or pansinusitis is crucial in patients with long-term fever, chronic and persistent dry or productive cough, headache, and nasal congestion along with anorexia, weakness, and lethargy.

6- CONFLICT OF INTEREST

All the authors declare that they have no conflict of interest.

7- ACKNOWLEDGMENT

The authors gratefully acknowledge the contribution of Mrs. Sayeh Hatefi for her great co-operation in data gathering from hospital records.

8- REFERENCES

1. Romero FA, Razonable RR. Infections in liver transplant recipients. *World J Hepatol*. 2011;3(4):83–92.
2. Kim S II. Bacterial infection after liver transplantation. *World J Gastroenterol WJG*. Baishideng Publishing Group Inc; 2014;20(20):6211.
3. Dehghani SM, Haghghat M, Imanieh MH, Honar N, Negarestani AM, Malekpour A, et al. Autoimmune hepatitis in children: Experiences in a Tertiary Center. *Iran J Pediatr*. 2013;23(3):302–8.
4. Avkan-Oguz V, Ozkardesler S, Unek T, Ozbilgin M, Akan M, Firuzan E, et al. Risk factors for early bacterial infections in liver transplantation. In: *Transplantation proceedings*. 2013. p. 993–7.
5. Reddy KR, O’leary JG, Kamath PS, Fallon MB, Biggins SW, Wong F, et al. High risk of delisting or death in liver transplant candidates following infections: Results from the North American consortium for the study of end-stage liver disease. *Liver Transplant*. Wiley Online Library; 2015;21(7):881–8.
6. Dara N, Dehghani SM, Safarpour A, Sepehrimanesh M. Liver function, paraclinical tests, and mortality risk factors in pediatric liver transplant candidates. *Comp Clin Path*. Springer; 2016;25(1):189–95.
7. Avery RK, Snyderman DR. Recipient screening prior to solid-organ transplantation. *Clinical infectious diseases*. 2002; 35(12):1513-9.
8. Dara N, Imanzadeh F, Sayyari AA, Nasri P, Hosseini AH. Simultaneous Presentation of Wilson’s Disease and Autoimmune Hepatitis; A Case Report and Review of Literature. *Hepat Mon*. Kowsar Medical Institute; 2015;15(6).
9. Singh N. Fungal infections in the recipients of solid organ transplantation. *Infect Dis Clin North Am*. Elsevier; 2003;17(1):113–34.
10. Fishman JA. Infection in solid-organ transplant recipients. *New England Journal of Medicine*. 2007 ;357(25):2601-14.
11. Mularoni A, Bertani A, Vizzini G, Gona F, Campanella M, Spada M, et al. Outcome of Transplantation Using Organs From Donors

Infected or Colonized With Carbapenem-Resistant Gram-Negative Bacteria. *American Journal of Transplantation*. 2015;15(10):2674-82.

12. Hagerty JA, Ortiz J, Reich D, Manzarbeitia C. Fungal infections in solid organ transplant patients. *Surg Infect (Larchmt)*. Mary Ann Liebert, Inc.; 2003;4(3):263–71.

13. Fishman JA, Marr KA, Thorner AR. Evaluation for infection before solid organ transplantation. *UpToDate* March. 2015.

14. Singh N, Paterson DL, Gayowski T, Wagener MM, Marino IR. Predicting bacteremia and bacteremic mortality in

livertransplant recipients. *Liver Transplant Elsevier*; 2000;6(1):54–61.

15. Said A, Safdar N, Lucey MR, Knechtle SJ, D'alessandro A, Musat A, et al. Infected bilomas in liver transplant recipients, incidence, risk factors and implications for prevention. *Am J Transplant. Wiley Online Library*; 2004;4(4):574–82.

16. Shepherd RW, Turmelle Y, Nadler M, Lowell JA, Narkewicz MR, McDiarmid S V, et al. Risk factors for rejection and infection in pediatric liver transplantation. *Am J Transplant. Wiley Online Library*; 2008;8(2):396–403.

Table-1: Indications of liver transplantation (our patients with pan sinusitis)

Indication of Liver Transplantation	Number (percent)
Cryptogenic liver cirrhosis	4 (40)
Autoimmune Hepatitis	1(10)
CN-I	2 (20)
Alfa 1 Antitrypsin Deficiency	1 (10)
Hepatoblastoma	1 (10)
EHBA	1 (10)

CN-I: Crigler Najjar syndrome type-1; EHBA: Extrahepatic Biliary Atresia.

Table-2: Presents diagnoses leading to liver transplantation, anthropometric characteristics and paraclinical findings in t children with sinusitis after liver transplantation.

Case number	Age (year)	Sex (male/female)	BMI (Kg/m ²)	Z-score BMI	Diagnosis before Tx	Time from Tx (>12mo)	Abnormal Laboratory Index	Para nasal sinus CT- scan: (1), (2), (3), (4)	Antibiotic regimen
1	8	M	25.4	2.4	Alfa-1 anti trypsin deficiency	24	ESR=94 CRP=16 Leukocyte=6,500 PMN=73%	Maxillary, Ethmoid, Sphenoid sinuses (1), (3)	Cefotaxime + Vancomycin
2	4	M	17.0	1.1	Cryptogenic cirrhosis	10	ESR=24 CRP=71 Leukocytosis=15,900 PMN=74%	Maxillary and Ethmoid sinuses (1)	Cefotaxime + Azithromycin
3	7	M	10.2	-9.8	Cryptogenic cirrhosis	54	ESR=70 CRP=45 Leukopenia= 3,400 PMN=42%	Frontal, Ethmoid, sphenoid, maxillary sinuses (1), (3)	Vancomycin + Meropenem
4	8	F	12.85	-2.4	Cryptogenic cirrhosis	48	ESR=33 CRP=59 Leukopenia=1,500 PMN=41%	Maxillary, Ethmoid, Sphenoid sinuses (1), Maxillary sinus (2), (4)	Ceftazidime + Amikacin
5	4	F	14.70	0.5	Cryptogenic cirrhosis	18	ESR=55 CRP=80 Leukocyte=15,500 PMN=78%	Maxillary, Ethmoid, sphenoid sinuses (1), (4)	Vancomycin + Cefotaxime
6	3y + 3m	F	15.5	-10	Extra-hepatic biliary atresia	21	ESR=78 CRP=43 Leukocyte= 9,600 PMN=65%	Maxillary and sphenoid sinuses (1), (4)	Clindamycin + Cefotaxime
7	2	M	16	0	Criggler-Najjar1	10	ESR=26 CRP =45 Leukocyte=19,650 PMN=49%	Frontal sinus (1)	Cefotaxime + Azithromycin
8	4y + 3m	M	17.5	1.4	Hepatoblastoma	10	ESR=72 CRP=74	Maxillary, Ethmoid, sphenoid sinuses (1),	Meropenem + Vancomycin

							Leukopenia=3,300 PMN=48%		
9	5y + 6m	M	14.6	0.7	Autoimmune hepatitis	8	ESR=31 CRP=18 Leukopenia=7,700 PMN=80%	Frontal ,maxillary sinuses (1 and 2),	Cefotaxime + Azithromycin
10	1y + 6m	M	Weight for length percentile :81.9	0.9	Crigger-Najjar1	2.5	ESR=42 CRP=38 Leukopenia=9,000 PMN=75%	Maxillary, Ethmoid, sphenoid sinuses (1), (3)	Vancomycin + Meropenem

Para nasal sinus CT scan: Mucosal thickening (1) Air Fluid level (2) Bilateral Osteomeatal Complex Obliteration (3) Mastoid air cell opacification (4); ESR: Erythrocyte Sedimentation Rate; CRP: C-Reactive Protein ; PMN: Polymorphonuclear; BMI: Body Mass Index; Tx: transplantation; IBD/ PSC: Inflammatory Bowel Disease/ Primary Sclerosing Cholangitis.

Table-3: Indications and number of pediatric liver transplantation from Iran.

Indication of Liver Transplantation	Number
Biliary Atresia	143
PFIC	118
Wilson Disease	114
Tyrosinemia	92
Autoimmune Hepatitis	79
Crigger-Najjar type1	78
IBD with PSC	11
Autoimmune hepatitis and HCC	8
Hepatoblastoma	5
Other rare indications	280
Total	903

PFIC: Progressive familial intrahepatic cholestasis; IBD: Inflammatory bowel disease; PSC: Primary Sclerosing Cholangitis; HCC: hepatocellular carcinoma.