

## Laparoscopic-Assisted Percutaneous Extraperitoneal Closure for Inguinal Hernia Repair in Children: An Initial Experience

\*Hamdi Louati<sup>1</sup>, Mohamed Jallouli<sup>1</sup>, Mohamed Zouari<sup>1</sup>, Hayet Zitouni<sup>1</sup>, Mahdi Ben Dhaou<sup>1</sup>, Riadh Mhiri<sup>1</sup>

<sup>1</sup>Department of pediatric surgery, Hedi Chaker Hospital, 3029 Sfax, Tunisia.

### Abstract

Over the past two decades, laparoscopy has advanced and multiple techniques for inguinal hernia repair have been established. Laparoscopic-assisted percutaneous extraperitoneal closure (LAPEC) for inguinal hernia repair in children, is one of the most simple and reliable methods. The present study aimed to assess the safety and feasibility of the LAPEC of inguinal hernia in children. From January 2014 to January 2016; 21 conventional LAPEC procedures were performed prospectively at our center (Group 1). Over this period, 21 patients of the same age and the same gender had open inguinal herniorrhaphies (Group2). The choice of whether to perform a LAPEC procedure was made according to the surgeon preference.

All operations were performed by the same surgeon. No significant differences were found between the 2 groups in terms of sex ratio, mean age, and operating time ( $p=0.19$ ; student test). There were no operative complications in group 1. Two patients (9.5%) in group 2 presented inguinal hernia recurrence. Despite a relatively high recurrence rate, LAPEC may be a practical alternative to conventional open herniorrhaphy. Comparative studies must be conducted to test advantages and disadvantages of this procedure in comparison with standard open herniorrhaphy and conventional laparoscopic repair techniques in a more extensive trial.

**Key Words:** Children, Hernia, Laparoscopic, Inguinal, Percutaneous.

\*Please cite this article as: Louati H, Jallouli M, Zouari M, Zitouni H, Ben Dhaou M, Mhiri R. Laparoscopic-Assisted Percutaneous Extraperitoneal Closure for Inguinal Hernia Repair in Children: An Initial Experience. Int J Pediatr 2018; 6(8): 8039-46. DOI: **10.22038/ijp.2018.31284.2765**

---

### \*Corresponding Author:

Hamdi Louati, Department of Pediatric Surgery. Hedi Chaker Hospital. 3029 Sfax. Tunisia.

Email: drhamdilouati85@yahoo.com

Received date: Mar.15, 2018; Accepted date: Apr.22, 2018

## 1- INTRODUCTION

Inguinal hernia repair is one of the most commonly performed surgical procedures in pediatric surgery (1). Over the past two decades, laparoscopy has advanced and multiple techniques for inguinal hernia repair have been established (2); however, a high recurrence rate was the main concern (3, 4). Laparoscopic-assisted percutaneous extraperitoneal closure (LAPEC) for inguinal hernia repair in children, is one of the most simple and reliable methods (5, 6).

The present study aimed to assess the safety and feasibility of the LAPEC of inguinal hernia in children. Between January 2014 and January 2016, 21 children with primary inguinal hernias were treated prospectively with LAPEC in our department. The choice of whether to perform a LAPEC repair was made according to the surgeon preference. Cases were performed by the same surgeon. The LAPEC procedure was performed under general endotracheal anaesthesia with muscle relaxation. The patient was in the supine position.

## 2- MATERIALS AND METHODS

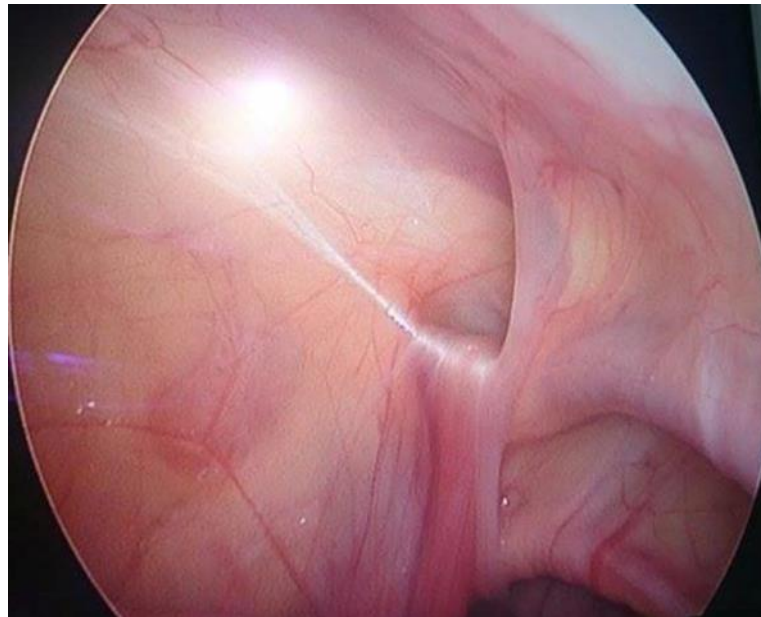
Pneumoperitoneum was established with an open technique by introducing a 2.5- or 5-mm reusable trocar through a transumbilical incision. Insufflation pressure was between 8 and 10 mm Hg. The size of the trocar was 3 or 5-mm. A 3-mm flexible-tip laparoscope 30° was used for visualization throughout the procedure. The whole peritoneal cavity was inspected.

We checking for metachronous hernia systematically; any hernia was reduced manually or with the aid of the telescope tips (**Figure.1**). All needle movements were performed from outside the body cavity under camera control. A non-absorbable thread (Prolene suture 3-0) was used. To choose the location for the needle puncture (**Figure.2**), the position of the internal inguinal ring was assessed by pressing the inguinal region from the outside with the tip of a Pean, the needle into the thread loop (**Figure.3**) and the needle was withdrawn.

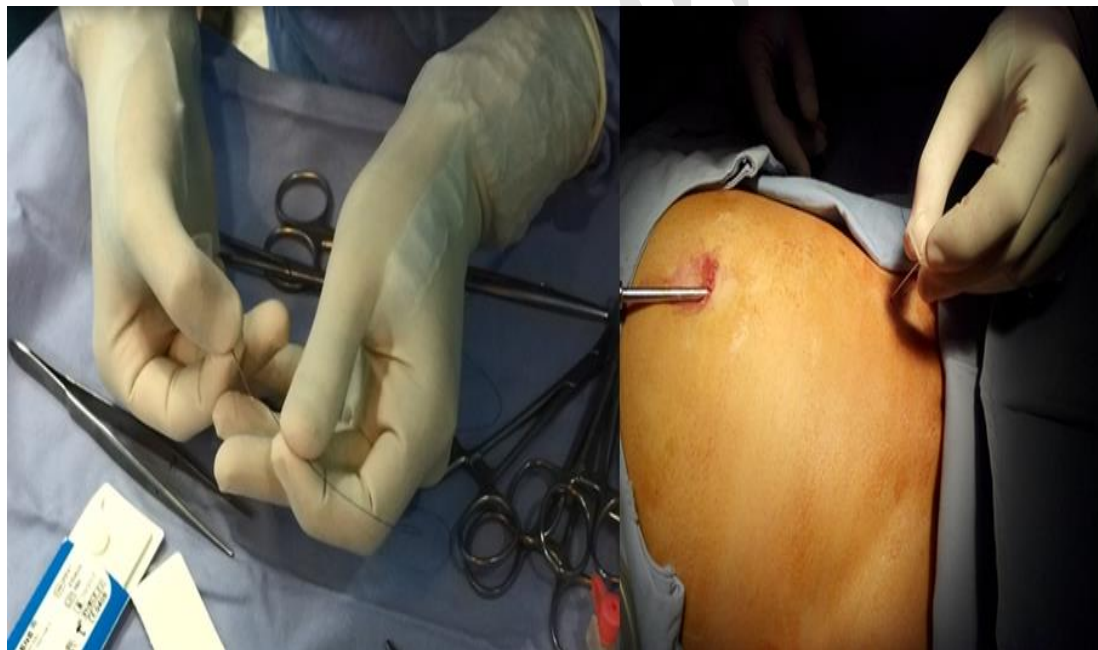Next, the thread loop was pulled out of the abdomen with the thread end caught by the loop. In that way the thread was placed around the inguinal ring under the peritoneum and both ends exit the skin through the same puncture point (**Figure.4**).

The knot was tied to close the internal ring and was placed under the skin (**Figure.5**). The umbilical wound was closed with absorbable stitches and covered with pressure dressing to prevent hematoma formation. The skin puncture point in the inguinal region was left without any dressing (**Figure.5**).

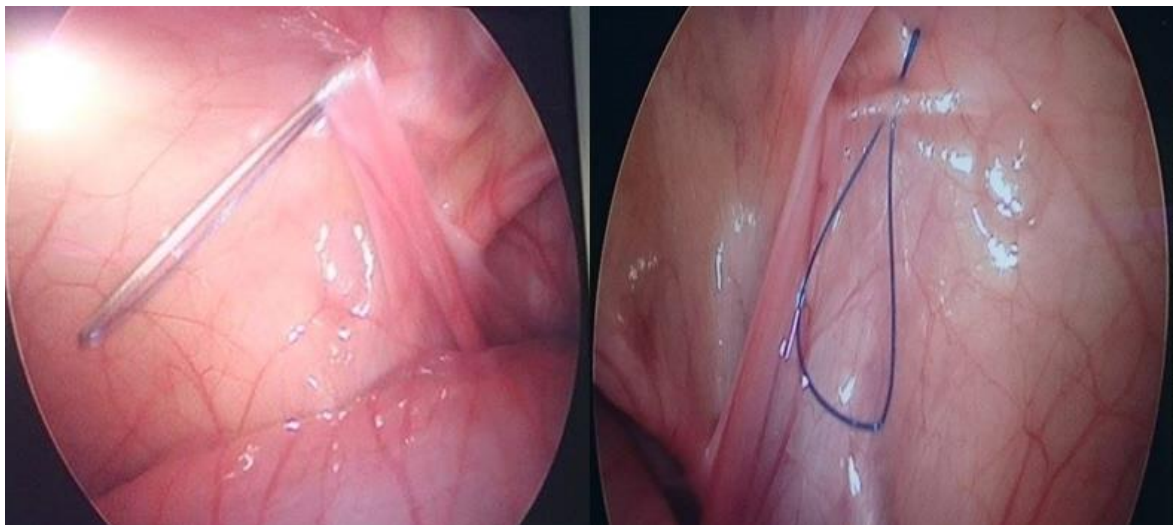
We also took 21 patients of the same age and same gender having an inguinal hernia and were operated by conventional route performed by the same surgeon in our department. Patient demographics, clinical data, operating techniques, operating time, intraoperative findings, postoperative course, and recurrence were collected and analysed.



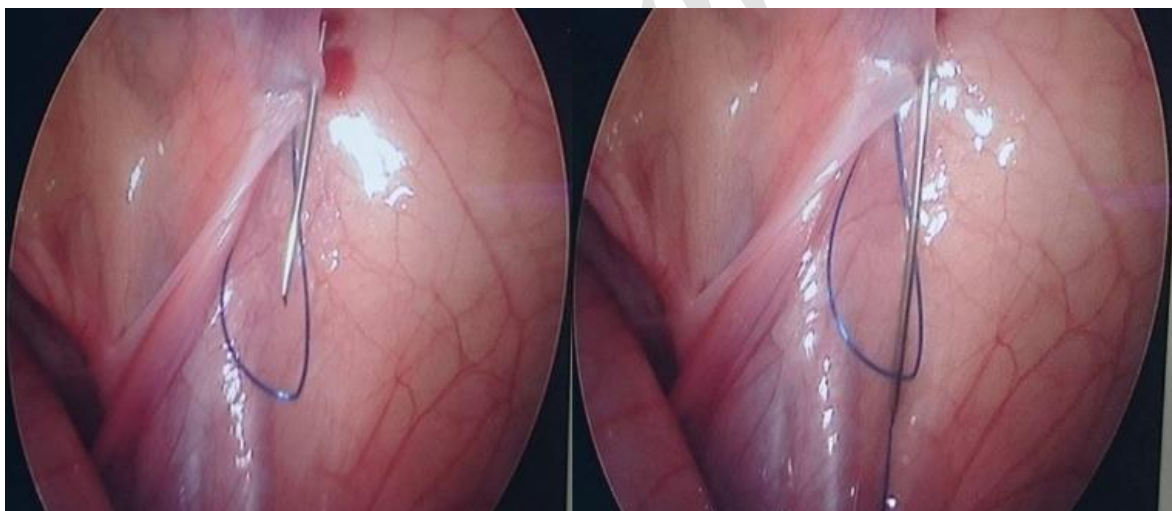**Fig.1:** Laparoscopic view of a left inguinal hernia in a 4-year-old girl.



**Fig.2:** We used a pink bronule CH24. Introduction Prolene (3-0) thread through tip bronule. Then the skin punctured above the right inguinal ring. Different steps of the LAPEC procedure.

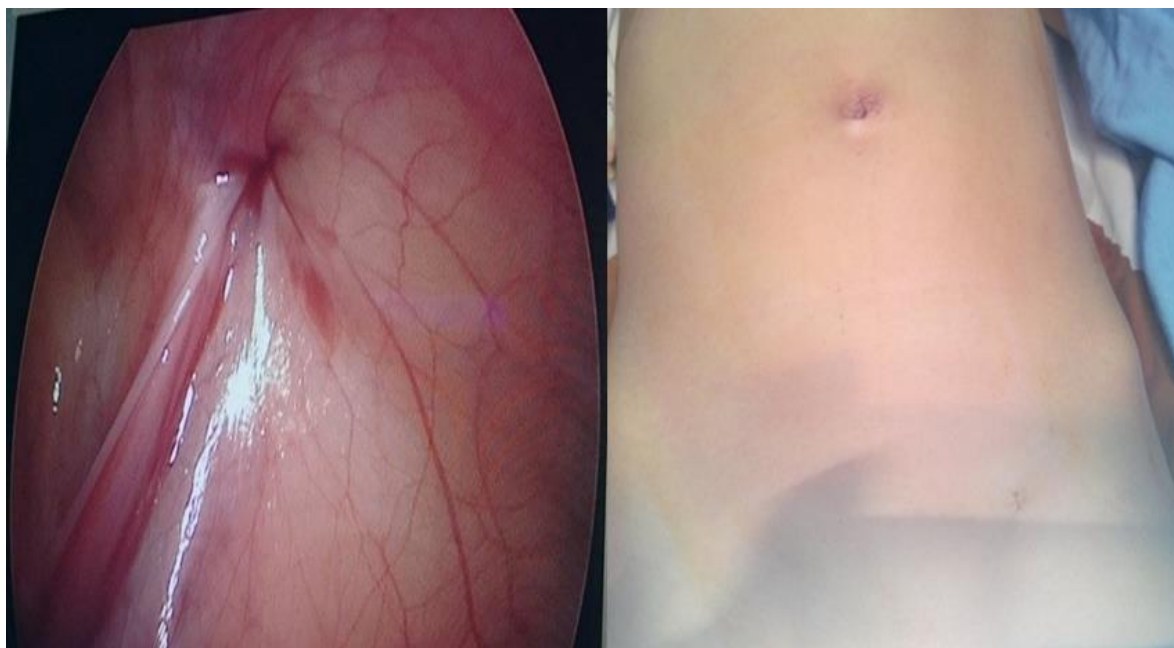

**Fig.3:** The injection needle passed through external half of the inguinal ring. B: Note the thread loop inside the abdominal cavity.



**Fig.4:** The needle inserted through the previous puncture point of the skin. B: The thread end pushed into the loop.





**Fig.5:** The knot tied. The internal inguinal ring closed, and the final postoperative appearance.

### 3- RESULTS

In our 21 patients, 16 (77%) were females, and 5 (23%) were males. The age of our patients was between 12 months and 180 months. The average of ages was 52.7 months. The side of the hernia was left for 12 patients (57%), right for 7 patients (33%), and bilateral for 2 patients (10%). Our operative time was between 15 min and 50 min. The average of the operative time was 26 min. Two of our patients had bilateral hernia the first one was operated in 50 min (30 min for the right and 20 min for the left) and the second one was operated in 26 min (17 min for the right and 9 min for the left). In the 21 patients of the same age, same sex and same weight who were operated for inguinal hernia with conventional herniorrhaphy by the same surgeon; the operative time was between 15 and 50 min. The average of the operative time was 25 min. Two patients had bilateral hernia the first one was operated in 40 min and the second one

in 50 min. The difference regarding the operative time between LAPEC and conventional was not statistically significant  $p=0.19$  (student test). Two of our patients presented a recurrence of hernia in the left side.

### 4- DISCUSSION

With the intent to make scarless surgery, laparoscopy has constantly evolved (4). Laparoscopic single-site surgery has rapidly progressed from laboratory to clinical use since 2007 (5). The techniques of minimal-access surgery for pediatric inguinal hernia have been numerous, and they continue to evolve, with a trend toward increasing use of extracorporeal knotting and decreasing use of working ports and endoscopic instruments (6). Single-port endoscopic-assisted percutaneous extraperitoneal closure with variable devices has been the ultimate attainment in minimal access surgery for pediatric inguinal hernia (7, 8).

Potential advantages of the purely laparoscopic approach include improved cosmetic outcome, decreased post-

operative pain, improved or equivalent operative times, and ease of evaluation of the contralateral groin with repair of a hernia if found. In addition, the ability to inspect the intestine for ischemia in incarcerated hernias and operate via new tissue planes for repair of recurrences from open surgery are possible with laparoscopy (9). In children diagnosed with a unilateral inguinal hernia, the risk of finding a contralateral patent processus vaginalis (PPV) has been reported as 30 to 40% (10). Laparoscopic inspection of the contralateral internal ring has been proven an effective technique to avoid unnecessary open exploration in patients with elevated risk of contralateral patent processus unidentified on clinical exam (9). In our study for all patients with unilateral hernia the contralateral groin was evaluated. For two patients the evaluation objective a contralateral patent processus vaginalis (CPPV) and they were not operated and after 12 months they are still asymptomatic. So it's is not systematic to operate all CPPV discovered in laparoscopic exploration still it is clinically asymptomatic. For girls, beauty is of more importance. With only one umbilical wound and another puncture point, LAPEC cosmetic outcomes were outstanding. All of the parents were satisfied with the scarless results in postoperative follow-up (11).

In a more recent randomized trial comparing 62 male patients the laparoscopic repair was also found to have a shorter operative time when compared with the open approach; however, this was not statistically significant (13, 14). Based on the best available evidence, it appears that there is not a significant difference between the laparoscopic and open approaches (15). Our operative time was near the average of operative time in other series of literatures; and it is getting better with more practice. In comparison with the conventional method there was no great

difference in operative time. Another advantage of laparoscopy may be in the management of incarcerated hernias, especially in infants. From a technical point of view, the laparoscopic approach is easier but technically more demanding for the surgeon because he or she has to be able to work in a very small space because of the bowel distension (16). The laparoscopic approach to incarcerated inguinal hernia appears safer. The surgical risk is reduced. The hospital stay is shortened. The child can be discharged home as early as any normal child with a regular inguinal hernia would (17). The laparoscopic approach to incarcerated inguinal hernia appears more logical and is technically safer, more economical, and more convenient to the parents (18).

According to the literature, patient age did not seem to be a limit to the use of this technique. Yury Kozlov et al. performed laparoscopic repair for inguinal hernia in 180 of 260 patients up to 3 months of age (4). The patients in the study of Felix Schier were 48 girls and 81 boys of age 3 weeks to 13 years (19). Liu et al. patients' age was ranging 10 months to 11 years (20). Shalaby et al. work was in 874 patients with age range 6–108 months (21). Suolin et al. performed in 207 children with inguinal hernia, with the age ranging from 2 months to 12 years (22, 23). In our study we did not notice difficulty for young patients. The age is not a restriction for this technique.

Recurrence is probably the most important consideration that leads surgeons to delay adopting the laparoscopic approach. Recurrence rates have been subjectively criticized as being higher for the laparoscopic than the open approach. It results in parents' and patients' disappointment and raises concerns about potential lawsuits if the open repair is associated with lower rates (24). The data on recurrence are somewhat difficult to translate to the entire population owing to

the variety of repairs which are being performed. However, the reported literature suggests that there is not a significant difference in recurrence rates between the laparoscopic and open repairs. A retrospective report of 884 patients found a recurrence rate of 3% (19). Another review of 275 laparoscopic repairs identified four recurrences (1.5%) over a 2- year follow-up; 26 smaller series with variable follow-up have reported 0%–3% recurrence rates (25, 26). Regarding prospective data, recurrence was seen in 0.8% of 125 patients undergoing laparoscopic repair compared with 2.4% of 125 patients undergoing open repair (13). The only reported meta-analysis identified three randomized trials and four observational studies to taking 1,543 laparoscopic repair and 657 open repairs for comparison. The meta-analysis concluded that based on those reports, the recurrence rate is not different between laparoscopic and open herniorrhaphy (26).

## 5- CONCLUSION

Despite a relatively high recurrence rate, LAPEC may be a practical alternative to conventional open herniorrhaphy. Comparative studies must be conducted to test advantages and disadvantages of this procedure in comparison with standard open herniorrhaphy and conventional laparoscopic repair techniques in a more extensive trial.

**6- CONFLICT OF INTEREST:** None.

## 7- REFERENCES

1. Lao OB, Fitzgibbons RJ, Cusick RA. Pediatric inguinal hernias, hydroceles, and undescended testicles. *Surgical Clinics of North America*, 2012; 92(3), 487-504.
2. Xi HW, Duan WQ, Cui QQ, You ZH, Zhao Z, Zhang P. Transumbilical Single-Site Laparoscopic Inguinal Hernia Inversion and Ligation in Girls. *Journal of Laparoendoscopic & Advanced Surgical Techniques*, 2015; 25(6): 522-25.
3. Uchida H, Kawashima H, Goto C, Sato K, Yoshida M, Takazawa S, et al. Inguinal hernia repair in children using single-incision laparoscopic-assisted percutaneous extraperitoneal closure. *Journal of pediatric surgery*, 2010; 45(12): 2386-89.
4. Kozlov Y, Novozhilov V. Technology of Single-Incision Laparoscopic Surgery in Treatment of Inguinal Hernia in Small Babies. *Journal of Laparoendoscopic and Advanced Surgical Techniques*, 2015; 25(6): 526-30.
5. Tran, H. Safety and efficacy of laparoendoscopic single-site surgery for abdominal wall hernias. *JLS: Journal of the Society of Laparoendoscopic Surgeons*, 2012; 16(2): 242.
6. Bharathi RS, Arora M, Baskaran V. Minimal access surgery of pediatric inguinal hernias: a review. *Surgical endoscopy*, 2008; 22(8): 1751-62.
7. Harrison MR, Lee H, Albanese CT, Farmer DL. Subcutaneous endoscopically assisted ligation (SEAL) of the internal ring for repair of inguinal hernias in children: a novel technique. *Journal of pediatric surgery*, 2005; 40(7): 1177-80.
8. Chang YT, Wang JY, Lee JY, Chiou CS, Hsieh JS. One-trocar laparoscopic transperitoneal closure of inguinal hernia in children. *World journal of surgery*, 2008; 32(11): 2459-63.
9. McClain L, Streck C, Leshner A, Cina R, Hebra A. Laparoscopic needle-assisted inguinal hernia repair in 495 children. *Surgical endoscopy*, 2015; 29(4): 781-86.
10. Ashcraft KW, Holcomb GW, Murphy JP, Ostlie DJ. *Ashcraft's pediatric surgery*. Saunders/Elsevier 2010. ISBN: 9781455743339
11. Li S, Liu L, Li M. Single-port laparoscopic percutaneous extraperitoneal closure using an innovative apparatus for pediatric inguinal hernia. *Journal of Laparoendoscopic and Advanced Surgical Techniques*, 2014; 24(3): 188-93.
12. Tamaddon H, Phillips JD, Nakayama DK. Laparoscopic evaluation of the contralateral groin in pediatric inguinal hernia patients: a comparison of 70-and 120-

degree endoscopes. *Journal of Laparoendoscopic and Advanced Surgical Techniques*, 2005; 15(6): 653-60.

13. Shalaby R, Ibrahim R, Shahin M, Yehya A, Abdalrazek M, Alsayaad I, et al. Laparoscopic hernia repair versus open herniotomy in children: A controlled randomized study. *Minim Invasive Surg*. 2012; 2012: 484135.

14. Celebi S, Uysal AI, Inal FY, Yildiz A. A single-blinded, randomized comparison of laparoscopic versus open bilateral hernia repair in boys. *Journal of Laparoendoscopic and Advanced Surgical Techniques*, 2014; 24(2): 117-21.

15. Ponsky T, NalugoM and Daniel J. Pediatric Laparoscopic Inguinal Hernia Repair: A Review of the Current Evidence. *J. of Laparoendoscopic and Advanced Surgical Techniques* 2014; 10:1089.

16. Esposito C, St. Peter SD, Escolino M, Juang D, Settini A, Holcomb III GW. Laparoscopic versus open inguinal hernia repair in pediatric patients: a systematic review. *Journal of Laparoendoscopic and Advanced Surgical Techniques*, 2014; 24(11): 811-18.

17. Kaya M, Hückstedt T, Schier F. Laparoscopic approach to incarcerated inguinal hernia in children. *Journal of pediatric surgery*, 2006; 41(3): 567-69.

18. Holcomb GW, Miller KA, Chaignaud BE, Shew SB, Ostlie DJ. The parental perspective regarding the contralateral inguinal region in a child with a known unilateral inguinal hernia. *Journal of pediatric surgery*, 2004; 39(3): 480-82.

19. Schier F. Laparoscopic surgery of inguinal hernias in children—initial experience. *Journal of pediatric surgery*, 2000; 35(9): 1331-35.

20. Liu W, Wu R, Du G. Single-port laparoscopic extraperitoneal repair of pediatric inguinal hernias and hydroceles by using modified Kirschner pin: a novel technique. *Hernia*, 2014; 18(3): 345-49.

21. Shalaby R, Ismail M, Samaha A, Yehya A, Ibrahim R, Gouda S, et al. Laparoscopic inguinal hernia repair; experience with 874 children. *Journal of pediatric surgery*, 2014; 49(3): 460-64.

22. Li S, Li M, Wong KK, Liu L, Tam PK. Laparoscopically assisted simple suturing obliteration (LASSO) of the internal ring using an epidural needle: A handy single-port laparoscopic herniorrhaphy in children. *Journal of pediatric surgery*, 2014; 49(12): 1818-20.

23. Takehara H, Yakabe S, Kameoka K. Laparoscopic percutaneous extraperitoneal closure for inguinal hernia in children: clinical outcome of 972 repairs done in 3 pediatric surgical institutions. *Journal of pediatric surgery*, 2006; 41(12): 1999-2003.

24. Yang C, Zhang H, Pu J, Mei H, Zheng L, Tong Q. Laparoscopic vs open herniorrhaphy in the management of pediatric inguinal hernia: a systemic review and meta-analysis. *Journal of pediatric surgery*, 2011; 46(9), 1824-34.

25. Parelkar SV, Oak S, Gupta R, Sanghvi B, Shimoga PH, Kaltari D, Bachani M. Laparoscopic inguinal hernia repair in the pediatric age group experience with 437 children. *Journal of pediatric surgery*, 2010; 45(4): 789-92.

26. Yang C, Zhang H, Pu J, Mei H, Zheng L, Tong Q. Laparoscopic vs open herniorrhaphy in the management of pediatric inguinal hernia: a systemic review and meta-analysis. *Journal of pediatric surgery*, 2011; 46(9): 1824-34.