

Ultrasound- guided Hydrostatic (Hydrocolonic) Treatment of Meconium Ileus: A Preliminary Report

Seyed Ali Alamdaran¹, Ahmad Mohamadipour², Marjan Joodi², Reza Shojaeean², Gholamreza Khademi³, Seyed Ali Jafari³, Alireza Atae³, Yasmin Davoudi¹, Halimeh Sadat Arabi Mogadam¹, *Reza Nazarzadeh²

¹Department of Radiology, Faculty of Medicine, Mashhad University of Medical Sciences, Mashhad, Iran.

²Department of Pediatrics, Faculty of Medicine, Mashhad University of Medical Sciences, Mashhad, Iran.

³Department of Pediatric Surgery, Faculty of Medicine, Mashhad University of Medical Sciences, Mashhad, Iran.

Abstract

Background

Meconium ileus (MI) is one type intestinal obstruction due to inspissated meconium at the level of the terminal ileum. The purpose of this study is to present the non-ionizing ultrasound-guided approach for the treatment of meconium ileus.

Materials and Methods

This study was performed, prospectively, at Dr. Sheikh and Akbar children's Hospitals, Mashhad University of Medical Science (Mashhad city, Iran) from March 2017 to March 2018. The 21 newborn patients with suspicious meconium ileus were referred to Radiology department for contrast enema and ultrasound examination. The hydro colonic ultrasound-guided treatment was considered for four cases with simple form of meconium ileus. Ultimately, plain abdominal radiography was taken to documentation of entrance of solution to dilated proximal loop and evaluation of probable complications.

Results

In ultrasound exam, air bubbles are floating in fluids on proximal dilated loops, and no air is seen in bowel loops contain inspissated meconium. Ultrasound showed a collapsed microcolon in addition to inspissated meconium as a hypoechoic beaded intraluminal material in comparison to adjacent bowel mucosa. During ultrasound-guided enema, overt distention of unused colon and ileum was seen with coating and detachment of meconium plaques from bowel wall and floating and movement of the plaques toward the dilated proximal loops. The successful treatment in our study was occurred in two-third of cases.

Conclusion

Ultrasound-guided hydrostatic (hydro colonic) treatment can be a non-ionizing nonsurgical procedure for successful treatment of newborns with uncomplicated meconium ileus.

Key Words: Meconium ileus, Neonate, Treatment, Ultrasound-guided.

*Please cite this article as: Alamdaran SA, Mohamadipour A, Joodi M, Shojaeean R, Khademi Gh, Jafari SA, et al. Ultrasound- guided Hydrostatic (Hydrocolonic) Treatment of Meconium Ileus: A Preliminary Report. Int J Pediatr 2018; 6(8): 8111-18. DOI:

Reza Nazarzadeh (MD), Department of Surgery, Akbar Hospital, Faculty of Medicine, Mashhad University of Medical Sciences, Mashhad, Iran; Fax: +985138440886

Email: NazarzadehR @mums.ac.ir

1- INTRODUCTION

Meconium ileus (MI) is one type intestinal obstruction due to inspissated meconium at the level of the terminal ileum. In most cases, it results from cystic fibrosis (CF). The main presenting symptom is the failure to pass meconium after birth (1, 2). Meconium ileus is either simple (50%) or complicated (50%) (3, 4). In complicated MI, the condition is associated with other gastrointestinal pathologies, such as bowel atresia, necrosis, and perforation, cystic meconium peritonitis, and pseudocyst formation. Complicated MI is treated surgically (1, 3, 4). In the simple form, thickened inspissated meconium obstructs the ileum (3). In the past, these neonates were treated surgically (4). In 1969, Noblett reported a nonsurgical treatment of MI for the first time. In his treatment, he introduced hyperosmolar Gastrografin to the colon via enema (3, 5). Nowadays, this technique has become the initial nonsurgical medication for diagnosis and treatment of uncomplicated MI (1, 3). Gastrografin enema allows liquefaction and evacuation of the meconium with success rates ranging from 40% to 83% (1, 3, 4, 6).

In cases of failure of enema, complications, or complex MI, a surgical procedure is required (1). Although, both non-operative and operative treatments are effective in this small-bowel obstruction, a successful non-operative treatment was associated with a more favorable outcome and a much lower mortality rate (1, 3). Until now, however, Gastrografin solution is usually infused into the rectum and colon under fluoroscopic guidance, which is accompanied by considerable ionizing radiation. This risk has provoked our search on order to reach for a new and safer non-operative method for the disease management. The purpose of this study was to present the non-ionizing ultrasound-guided approach for treatment of the meconium ileus.

2- MATERIALS AND METHODS

2-1. Method

This study was performed, prospectively, at Dr. Sheikh and Akbar Children children's Hospitals, Mashhad University of Medical Science (Mashhad city, Iran) from March 2017 to March 2017. The 21 newborn patients (aged 3 to 8 days) with non-passage of meconium were referred to radiology department who showed suspicious findings on plain abdominal X-ray and suggestive a low type intestinal obstruction. They were referred for contrast enema and ultrasound examination. Four newborn with ultrasound findings of uncomplicated meconium ileus were selected. Newborns with other mechanical obstruction in other parts of the intestine (intestinal atresia, Hirschsprung's disease), and 3 cases with complicated meconium ileus were excluded from the study. The ethics committee of Mashhad faculty of Medical Sciences approved this study, also this study registered in Thai Clinical Trials Registry (TCTR20171125001). All parents gave informed written consent,

2-2. Procedure technique

We first performed a detailed target abdominal sonography with focusing on terminal ileum and colon for confirming or rule out of meconium ileus by an expert pediatric radiologist. If ultrasound sign of uncomplicated meconium ileus are found, hydro-colonic ultrasound-guided treatment was considered and enrolled in the study. The number and size of loops containing meconium were carefully evaluated in the right abdominal area between ascending colon and proximal dilated loop. Then, we instilled 30 to 80 ml of hypertonic solution via a no.14 rectal tube trans-rectally to fill the rectum and colon in semi-supine position under ultrasound guidance. The hypertonic solution we used was a warm mixture of one part of Gastrografin (Meglumine diatrizoate) (1,500 mosm/L),

and two parts of normal saline with an estimated total osmolarity of 500 mosm/L. Gastrografin was selected due to its hyperosmolarity and radio-opacity. In order to prevent leakage, anus closure was done by buttock compression with hands. Solution instillation was slowly done by hand compression of syringe piston. At the time of instillation, the ultrasonic observation was performed using 12 MHZ transducer, and sonographic findings were recorded. The entrance of hyperosmolar solution to colon and ileum and flotation of meconium plaques was evaluated. The relief of obstruction and all of the probable complications such as perforation were recorded. Patients underwent one or two attempts in each session, and for the patients with sign of success, three sessions were done, maximumly.

The distances between sessions were 12 or 24 hours. In case of failure or complication, the surgical procedure was performed. Ultimately, plain abdominal radiography was taken to evaluate the entrance of solution to dilated proximal loop before the obstruction site and any probable perforation. To avoid any probable hypovolemia, the neonates were maintained on an adequate intravenous fluid infusion throughout the procedure and afterward. After successful hydro colonic treatment, infants were transferred to surgical NICU and were under close look for any sign of defecation or complications (bowel perforation, hypovolemia, and enterocolitis) and start oral feeding combined oral laxative Polytilenglicol (1mg/kg solution, BID). The orogastric tube was removed, and the patient was referred to the ward, only after defecation was started and obstruction was resolved, and the patient could tolerate breast feeding. After their discharge, we referred all patients to the pediatric gastroenterologist for more evaluation and further follow up for cystic fibrosis.

3- RESULTS

Twenty-one consecutive patients (aged 3 to 8 days) with non-passage of meconium and abnormal findings on plain abdominal X-ray suspicious to a low type intestinal obstruction probably due to meconium ileus were referred to Radiology Department. The final diagnosis was bowel atresia (10 cases), complicated meconium ileus (3 cases), Hirschsprung's disease (2 cases), small left colon syndrome (2 cases), and simple meconium ileus (4 cases). In all patients, clinical findings were abdominal distention, bilious vomiting, and failure to pass meconium. **Table.1** shows demography characteristic, sonographic and radiologic findings of four patients with meconium ileus. The abdominal plain X-ray demonstrated tubular distention of small bowel loops. The "soap bubble" sign was observed on every 4 cases of meconium ileus. This sign is never seen in five patients with another disease. In ultrasound exam, air bubbles are floating on fluids in proximal dilated loops, and no air is seen in bowel loops contain inspissated meconium (**Figure.1**).

Abdominal ultrasound showed a collapsed microcolon in addition to inspissated meconium as a hypoechoic beaded intraluminal material in comparison to adjacent bowel mucosa. The number of loops containing meconium in the right lower quadrant and the lower abdominal area between ascending colon and proximal dilated loop were estimated as few or numerous. Three newborns with meconium ileus (3 female) with 3-8 days age were enrolled in the study. Before the start of enema, microcolon was seen in all three cases of meconium ileus with mean diameter of 5 mm. During ultrasound-guided enema, it was increased to 9-10 mm. Overt distention of unused colon and ileum was seen with coating and detachment of meconium plaques from bowel wall and floating and movement of the plaques toward the dilated proximal

loops (**Figure.2**). Post-procedure plain abdominal X-ray (contrast study) demonstrated an unused colon (microcolon), and filling defects of inspissated meconium pellets within the terminal ileum and cecum with the arrival of contrast agent to proximal dilated loop without any sign of perforation (**Figure.3**). In one patient, Gastrografin enema was unsuccessful; this patient underwent laparotomy, Jejunostomy, resection of

dilated gangrenous part of the bowel and intraluminal irrigation. The two patients successfully responded to the clearing of meconium using an ultrasound-guided solution enema. The passage of meconium occurred during the first 12 to 24 hours after the procedure and the patient tolerated feeding after 24-48 hours. No complications occurred during and after treatment.

Table-1: The demographic characteristic, sonographic and radiologic findings of four patients with meconium ileus.

Gender	Age (day)	Numbers of dilated loops in X-ray	Radiographic Soap bubble	Meconium filled loops in ultrasound	Sonographic floating gas bubble	Diameter inspissated meconium loops (mm)	The diameter of micro-colon (mm)	The diameter of dilated loop (mm)	Number of sessions	Outcome
Female	8	Multiple	Few	Few	Few	6	5	22	1	Success
Female	2	Few	Few	Multiple	Multiple	6	5.5	35	2	Un-success
Female	4	Few	Few	Multiple	Multiple		5		3	Success
Male	3	Few	Multiple	Multiple	Multiple	6	4.5	27	-	Not done

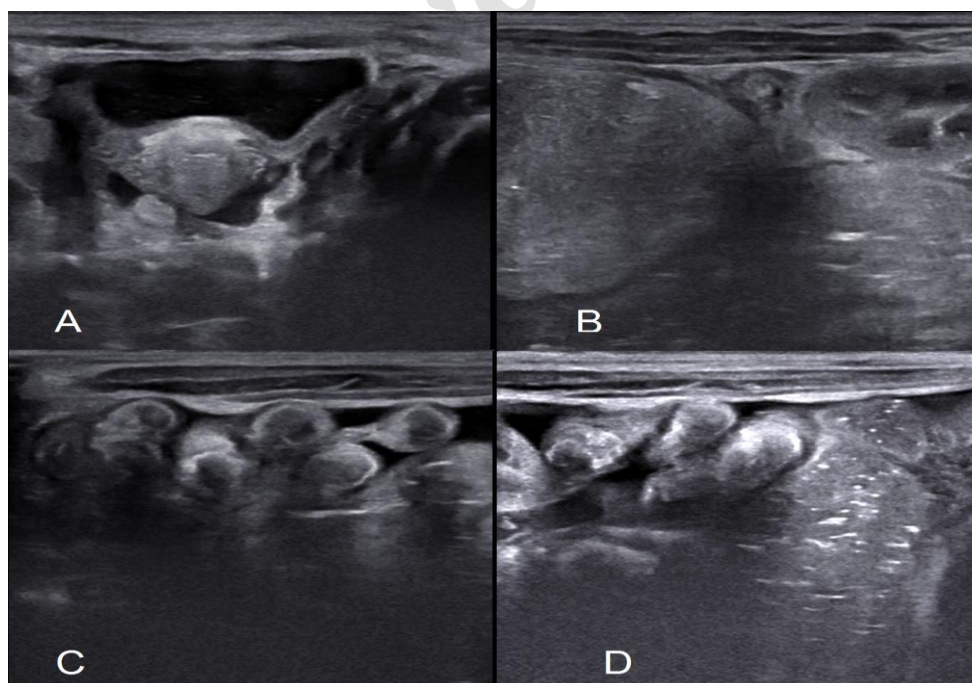


Fig.1 (A-D): The abdominal ultrasonography findings of meconium ileus; A) dilated proximal loops with floating flakes of air in meconium fluid on proximal dilated loops as the reason of soap bubble sign. B) The descending colon in front of the left kidney and posterior to dilated proximal loops. C and d) the bowel loops contain inspissated meconium as hypoechoic tubular or beaded intraluminal material in comparison with its bowel wall.

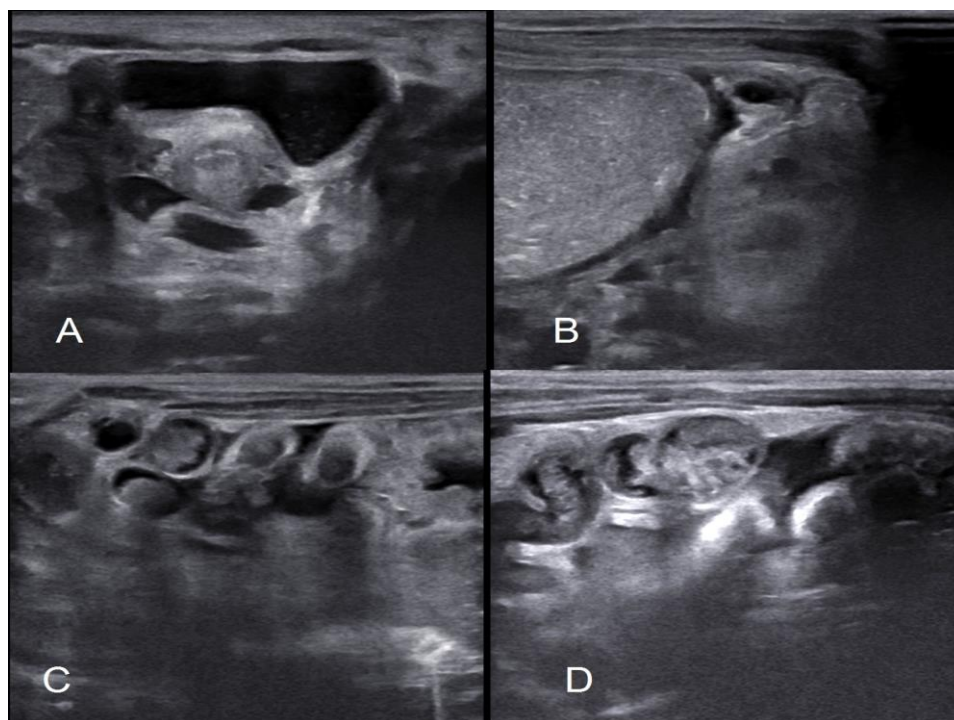


Fig.2 (A-D): The ultrasonographic findings during hydrostatic treatment of meconium ileus; A) Dilatation of descending colon with the arrival of the solution to it. B and C). Coating and detachment of meconium plaques from bowel wall and floating of them. D) The arrival of solution to around of liquated meconium in distended proximal bowel loop.

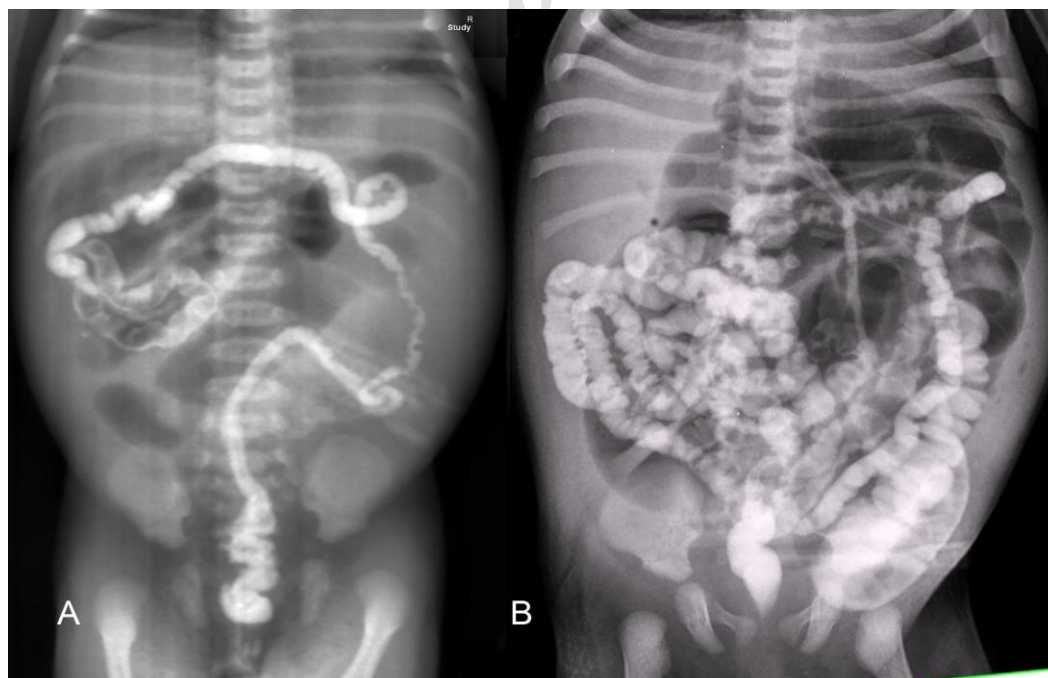


Fig3: Post procedure plain abdominal X-ray (contrast study) demonstrated an unused colon (microcolon) and filling defects of inspissated meconium pellets within the terminal ileum and cecum with the arrival of contrast agent to proximal dilated loop without any sign of perforation. A) Patient with few involved loops. B) Another patient with an elongated loop of small bowel.

4- DISCUSSION

Plain abdominal X-ray is the first radiologic step in the evaluation of newborns with suspected intestinal obstruction to rule out obstruction and /or differentiate between high and low bowel obstruction. After that, a contrast enema is performed in all newborns with suspected low intestinal obstruction. This contrast study would demonstrate signs of Hirschsprung's disease, unused colon (microcolon) due to ileal atresia or meconium ileus and filling defect due to intraluminal inspissated meconium pellets within the terminal ileum or left colon (4). Meconium obstruction may be relieved medically by contrast enema, but Hirschsprung's disease, malrotation and ileal atresia diseases require surgical intervention (7). There were no studies those determinate sensitivities/specificities for the imaging diagnosis of ileal atresias, meconium plug, and meconium ileus in the literature (8).

However, differentiation of malrotation, Hirschsprung's disease and ileal atresia from inspissated meconium with ultrasound is easy. In Hirschsprung's patients, the colon does not have a collapsed small size (microcolon pattern), and echogenic gas bubbles are seen intraluminally in the rectum. Malrotation and midgut volvulus are seen as the inversion of the mesenteric vessels and whirlpool sign (10). In patients with meconium ileus, dilated proximal loops lead to a bowel loop which is filled with meconium and leads to a collapsing microcolon. Meconium plaques are seen as a beaded fixed intraluminal material with hypoechoic echogenicity compared to adjacent bowel mucosa. This tubular and beaded hypoechoic meconium is not seen in patients with bowel atresia. However, there are only two different descriptions for meconium ileus in the literature, as multiple bowel loops, filled with very echogenic thick meconium (7) and an

echogenic abdominal mass (11). These papers are fairly old, especially second paper and with one case. Existing meconium in meconial ileus is extremely viscid and inspissated (4). There are several options for decreasing meconium viscosity and its liquefaction. The many authors consider enema reductions with saline, surfactant, N-acetyl cysteine, Polysorbate 80 and Gastrografin, etc. (1, 4). Burke et al. studied the efficacy of these solutions to relieve intraluminal meconium and probably intestinal mucosa damage. According to their research, Surfactant and Gastrografin enema were most efficient for relieving obstruction and reducing viscosity. The delay in effectiveness was a limitation of N-acetyl cysteine. Although traditionally there had been some concern that Gastrografin may cause a colonic inflammation and occasionally necrosis, all of the above agents including Gastrografin were equally safe for the intestinal mucosa (3). However, infusion of a hyperosmolar solution into the lumen of the bowel results in a massive osmotic fluid influx into the lumen developing uncontrolled distension of the bowel and dehydration which demands meticulous clinical consideration (3).

Based on what most of the studies were recommended (1, 3, 4, 5), we used a mixture of 2 parts of 0.9% Sodium Chloride and 1 part of Gastrografin. Gastrografin was chosen based on its hyperosmolality and radiopacity. In addition, as we took a post-procedural abdominal X-ray to ensure that our technique was appropriate and better detection of probable perforation, we needed to a radio-opaque agent too. Gastrografin concentration in available researches was between 20 to 50% (1, 4). Traditionally, decreasing meconium viscosity and liquefaction by infusion of hyperosmolar solution into the lumen of the bowel is introduced as the cause of

elimination of obstruction. However, during ultrasound-guided treatment, distention of microcolon and ileum around the meconium plaque and detachment of inspissated pellets from bowel wall and floating and movement of meconium pieces to distended proximal loops is encountered. Then, we think that mechanical displacement of plaques is the most cause of elimination of obstruction. Therefore, the selected media should have effects of lubricative and liquefactive of meconium plaques and motivator of peristalsis and radiopacity. After the successful procedure, we prescribed administration of 5 mL of a 5% N-acetyl cysteine every 6 hours through a nasogastric tube for better evacuation of remaining meconium and liquefaction of upper gastrointestinal secretions (3, 5). We also recommended using oral laxative Polyetilenglicol (1mg/kg solution, BID) because of its osmotic laxative effect and peristalsis motivation.

Our experience in this technique was completely similar to ultrasound-guided hydrostatic reduction of Intussusception (12). There are some advantages for ultrasound-guided hydrostatic reduction of intussusceptions compared with the fluoroscopic-guided pneumatic reduction of intussusceptions. Direct visualization of fluid flow and its effect on detachment and intraluminal floating of meconium with a nonionizing technique are the most important ones. Microcolon extensibility by fluid pressure and meconium pellet envelopment and movement is easily seen by ultrasound. Ultimately, plain abdominal radiography was taken to document the entrance of solution to dilated proximal loop before the obstruction site and evaluation of probable perforation. In spite of 15% perforation rate in some articles (4), we did not encounter any complications. The success rates of the hypertonic contrast enema in different studies were between 40% - 83% (4, 6),

and in our study it was two-third of cases. As an interesting point, although no existence of air-fluid level, and a soap bubble appearance on plain abdominal roentgenograms (Neuhauser's sign) are explained as a result of mixture of meconium with swallowed air (4), but in ultrasound exam, air bobbles are floating in fluids in the proximal dilated loops and there is no air in the loops containing inspissated meconium. Then, inspissated meconium in obstructed loops is not the cause of soap bubble sign. In these patients, function impairment of gastrointestinal enzymes results to formation viscid liquid in proximal dilated loops and inspissated meconium in obstructed loops. This viscid liquid in the proximal dilated loops is the reason for soap bubble sign and non-formation of air-fluid levels in the plain abdominal X-ray. However, the "soap bubble" sign was observed in every four cases of meconium ileus and wasn't seen in any other disease.

In patients with simple MI, conservative treatment with the ultrasound-guided hydro colonic Gastrografin enema is an effective initial treatment. The better visualization of solution flow and meconium detachment in ultrasound-guided technique leads to the better confidence of existence of progress or stop in solution flow, the exact location of solution flow and detection success or probable complications. That probably leads to perform more procedure and better results. This is a preliminary report with few cases that imply on changing method of treatment patients with meconium ileus. Further studies with more cases should be done for ultrasonic differentiation of simple from complicated cases, identification of criteria for prediction respond to hydrostatic treatment, assessment of appropriate technique, necessity usage of sedation, determinate of the type of safe wetting agents or

solutions, better evaluation of its effectiveness and probably complications.

5- CONCLUSION

Abdominal ultrasound and ultrasound-guided hydrostatic (hydro colonic) treatment can be a non-ionizing nonsurgical procedure for successful diagnosis and treatment of newborns with uncomplicated meconium ileus.

6- CONFLICT OF INTEREST: None.

7- ACKNOWLEDGMENTS

The authors would like to appreciate pediatric surgeons and PICU intensivists of Dr. Sheikh and Akbar Hospital of Mashhad University of Medical Sciences for their advocated helps.

8- REFERENCES

1. Karimi A1, Gorter RR, Sleeboom C, Kneepkens CM, Heij HA. Issues in the management of simple and complex meconium ileus. *Pediatr Surg Int.* 2011 Sep; 27(9): 963–68.
2. Rescorla FJ, Grosfeld JL. Contemporary management of meconium ileus. *World J Surg.* 1993; 17(3):318-25.
3. Burke MS, Ragi JM, Karamanoukian HL, Kotter M, Brisseau GF, Borowitz DS, et al. New strategies in non-operative management of meconium ileus. *J Pediatr Surg.* 2002; 37(5):760-4.
4. Rescorla FJ, Grosfeld JL, West KJ, Vane DW. Changing patterns of treatment and survival in neonates with meconium ileus. *Arch Surg.* 1989; 124 (7):837-40.
5. Neal MR, Seibert JJ, Vanderzalm T, Wagner CW. Neonatal ultrasonography to distinguish between meconium ileus and ileal atresia. *J Ultrasound Med.* 1997; 16(4):263-6; quiz 267-8.
6. Noblett HR. Treatment of uncomplicated meconium ileus by Gastrografin enema: a preliminary report. *Journal of pediatric surgery.* 1969; 4(2):190-7.
7. Murshed R, Spitz L, Kiely E, Drake D. Eur J. Meconium ileus: a ten-year review of thirty-six patients. *Pediatr Surg.* 1997; 7(5):275-7.
8. Alamdaran S.A, Zandi B, Sadeghipor S, Esfandiari H. Ultrasound-Guided Hydrostatic Reduction of Childhood Intussusceptions Using Water Enema. *Iran J Med Sci.* 2006; 31(4):224-27.
9. Carroll AG, Kavanagh RG, Ni Leidhin C, Cullinan NM, Lavelle LP, Malone DE. Comparative Effectiveness of Imaging Modalities for the Diagnosis of Intestinal Obstruction in Neonates and Infants: A Critically Appraised Topic. *Acad Radiol.* 2016; 23(5):559-68.
10. Alamdaran SA, Hashemi J, Layegh P, Taghawi M. The Diagnostic Value of Ultrasonography in Pediatric Intestinal Malrotation. *International Journal of Science and Research (IJSR).* 2015 Aug; Vol 4 (8). 350-54.
11. Barki Y, Bar-Ziv J. Meconium ileus: ultrasonic diagnosis of intraluminal inspissated meconium. *J Clin Ultrasound.* 1985; 13(7):509-12.
12. Alamdaran S.A, Zandi B, Sadeghipor S, Esfandiari H. Ultrasound-Guided Hydrostatic Reduction of Childhood Intussusceptions Using Water Enema. *Iran J Med Sci.* 2006; 31(4): 224-7.