

CblC Type Methylmalonic Aciduria with a Novel Homozygous Mutation: A Case Report

Joghee Sunil¹, Kumar Pradeep², *Mariam Suja¹, Buddhavarapu Siddartha¹

¹Division of Neonatology, Department of Pediatrics, Sri Ramakrishna Hospital, Coimbatore, Tamil Nadu, India.

²GeneOmm Medical Centre, Coimbatore, Tamil Nadu, India.

Abstract

Background

Combined Methylmalonic Aciduria (MMA), and homocystinuria CblC type is the most common inborn error of cobalamin metabolism with 77 mutations identified till date in the MMACHC gene. The disease has early and late presentations with varied clinical features.

Case report

A pair of preterm monochorionic twins was born to non-consanguineous parents with history of 2 previous infant deaths with suspected MMA. The twins became symptomatic in second week with severe neutropenia, thrombocytopenia, progressive encephalopathy and eczema without anemia, metabolic acidosis or hyperammonemia. Investigation revealed elevated plasma Complement 3 (C3) acyl carnitine and very high MMA levels in urine. Genetic testing revealed a novel large deletion mutation in chromosome 1 which comprised of the whole MMACHC gene confirming the diagnosis of CblC type of MMA. The mutation was homozygous despite parents being unrelated and was identified in both parents later. Both twins responded transiently to treatment with hydroxycobalamin.

Conclusion

Large deletion in the MMACHC gene which was identified in a homozygous state in our twins is previously unreported. The phenotypic features are described.

Key Words: Cobalamin metabolism, India, MMACHC gene, Methylmalonic academia.

*Please cite this article as: Sunil J, Pradeep K, Suja M, Siddartha B. CblC Type Methylmalonic Aciduria with a Novel Homozygous Mutation: A Case Report. Int J Pediatr 2018; 6(9): 8275-80. DOI: **10.22038/ijp.2018.31956.2845**

***Corresponding Author:**

Dr. Suja Mariam, Consultant, Division of Neonatology, Sri Ramakrishna Hospital, Coimbatore, Tamil Nadu, India.

Email: suja_mariam@yahoo.co.in

Received date: Mar.15, 2018; Accepted date: Apr. 22, 2018

1- INTRODUCTION

Combined Methylmalonic aciduria (MMA), and homocystinuria is a heterogenous disorder caused by mutations in CblC, CblD or rarely in lysosomal cobalamin exporter (CblF type). The CblC type involving autosomal recessive mutations in MMCHC gene in chromosome 1p34.1 is the most common inborn error of cobalamin metabolism. More than 77 mutations have been described in MMACHC gene in homozygous or compound heterozygous state (1, 2). Here we report a pair of twins born to non-consanguineous parents presenting with MMA and diagnosed to have cblC type MMA involving a novel homozygous mutation in MMACHC gene. We describe the phenotypic features and response to B12 therapy in these patients.

2- CASE REPORT

The affected monozygotic diamniotic twin female infants were born at 34 weeks of gestation (spontaneous conception to non-consanguineous parents) by emergency section in view of fetal growth restriction in one twin. The parents had two previous neonatal losses. Their first boy who was well at birth developed thrombocytopenia, leucopenia and erythroderma and died on day 32 of life. Their second child a term female baby presented with failure to thrive and bicytopenia. Her initial workup showed more than 100-fold rise in urine MMA. However, there were no elevated plasma or urine homocysteine levels. This baby died at 3 months of age. Preconceptional mutational analysis was done on both parents who were found to be carriers of a likely pathogenic variant in the GLDC gene. In view of previous neonatal losses, the current pregnancy was under close surveillance. Chorionic Villous Sampling done in this pregnancy did not detect the same GLDC gene and pregnancy was continued. Both babies were asymptomatic

at birth. The first and second twin weighed 2,074 grams and 1,692 grams, respectively. They reached full enteral feeds (breast milk) on day 3 and day 7, respectively. A routine newborn metabolic screening (Tandem Mass Spectrometry for acyl carnitine and amino acid profile) was done on both babies on day 3. The infants became symptomatic in early second week of life with hypothermia, lethargy and hypotonia. The second twin developed diffuse eczema with desquamation involving extremities, perioral and perianal area. There was no metabolic acidosis or hyperammonemia in either of the twins. Neither of them had seizures. The TMS report showed elevated Propionylcarnitine (C3), elevated C3/ acetylcarnitine (C2), and C3/C16 ratios and a normal amino acid profile. Further evaluation showed severe neutropenia and thrombocytopenia (**Table.1**). There was no anemia. Plasma active Vitamin B12 levels and biotinidase were normal. Urine organic acids by gas chromatography-mass spectrometry (GCMS) of both twins done on day 12 showed highly elevated levels of MMA (**Table.1**) in both twins.

A diagnosis of inherited cobalamin synthesis defect was entertained (in view of bicytopenia, no metabolic acidosis and methylmalonic aciduria). Blood was sent for genetic analysis. Treatment was commenced with Intravenous (IV) antibiotics, high doses of cyanocobalamin (Optinuron; 1000 mcg B12/3ml; Lupin pharma) 1,000 mcg intramuscular (IM) daily initially. This was increased to 3,000 mcg IM three times a day. Oral folate, biotin and carnitine supplementation was also given. As there was no response, cyanocobalamin was changed to hydroxycobalamin (Trineurosol H; Wockhardt Pharma). There was significant clinical and hematological improvement after initiation of hydroxycobalamin (**Figure.1 and 2**). They were restarted on breast milk (as special formula was not

available in India at that time). Genetic evaluation using Next Generation Sequencing was done encompassing 81 genes associated with thrombocytopenia and Vitamin B12 deficiency (Strand Life Sciences Private Limited, Bengaluru, India). The test showed a homozygous large deletion involving the whole MMACHC gene in both the twins in

chromosome 1. Deletion started at 5' end of coding sequence at position 31 and extending to 3' end of coding sequence at position 30 resulting in the loss of the entire gene, which is a novel mutation and not reported previously in literature. The findings were confirmed by independent method such as quantitative PCR.

Table-I: Laboratory Investigations

Parameters	Twin 1	Twin2
Hemoglobin (g/dl) ^a	18.4	18.4
Total WBC (per mm ³) ^a	5480	3060
Absolute Neutrophil count (per cu.mm) ^a	1300	210
Platelet count (per mm ³) ^a	24,000	3,08,000
Ammonia (mmol/l) ^a	54	95
Plasma Bicarbonate (mEq/L) ^a	25	20
Plasma lactate (mmol/L) ^a	3.9	2.9
Serum total B12 (pg/ml) ^b	1002	944
Serum active b12 (pmol/L) ^c	--	>256
Serum folate levels (ng/ml) ^d	34.5	15.9
Serum Biotinidase levels (nmol/ml/min) ^e	8.2	7.0
C3 carnitine (μM) ^f	17.26	19.82
C3/C2 ratio ^g	0.42	0.38
Urine MMA ^h	1261	558.2
Plasma methionine levels (μmol/L) ⁱ	13.3	13.6
<p>a- Done on day 12 of life when babies became symptomatic, b- Normal range: 183-887 pg/ml; done here after first dose of i.m. Vitamin B12, c- Normal range: 25.1-165 pmol/L; done here after first dose of i.m. Vitamin b12, d- Normal: 3.1-20.5 ng/ml, e- Normal: 5.5-17.1 nmol/ml/min, f- Normal: 0.4-4.0 μM, g- Normal: 0.1-0.3, h- Cutoff:5.34 %, Normal: 10-60.</p>		

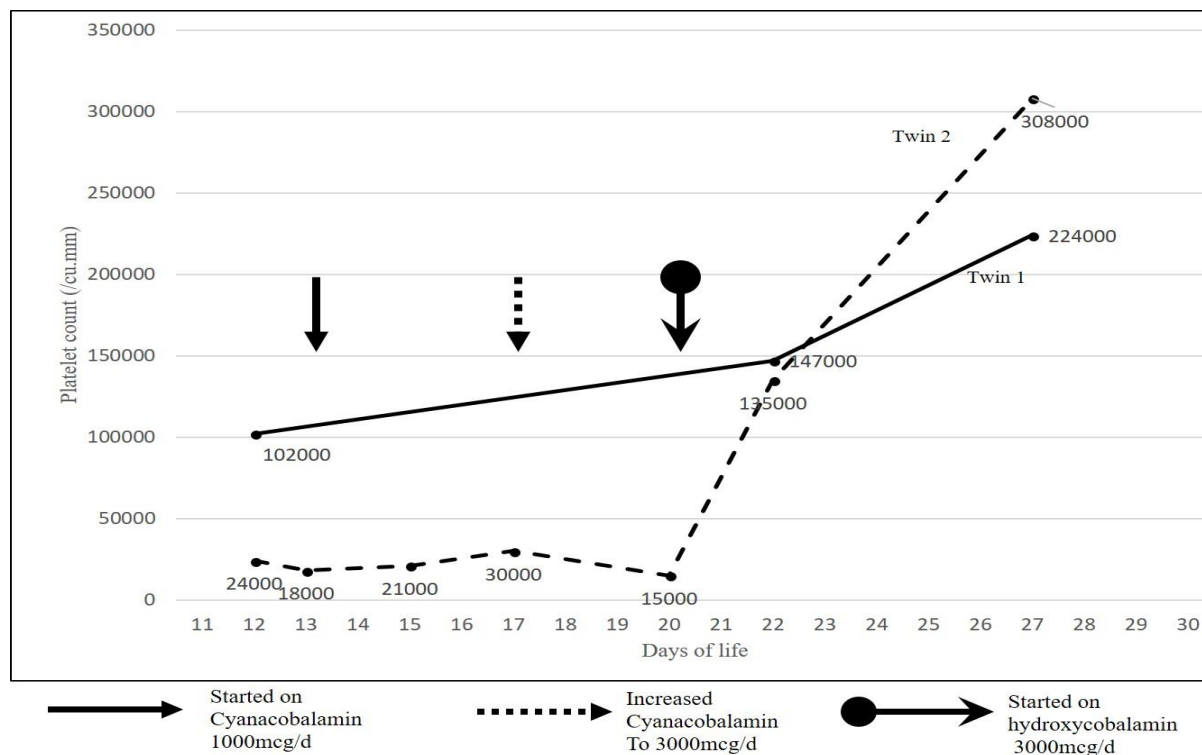


Fig.1: Trend in Platelet counts of the twins in response to B12 therapy.

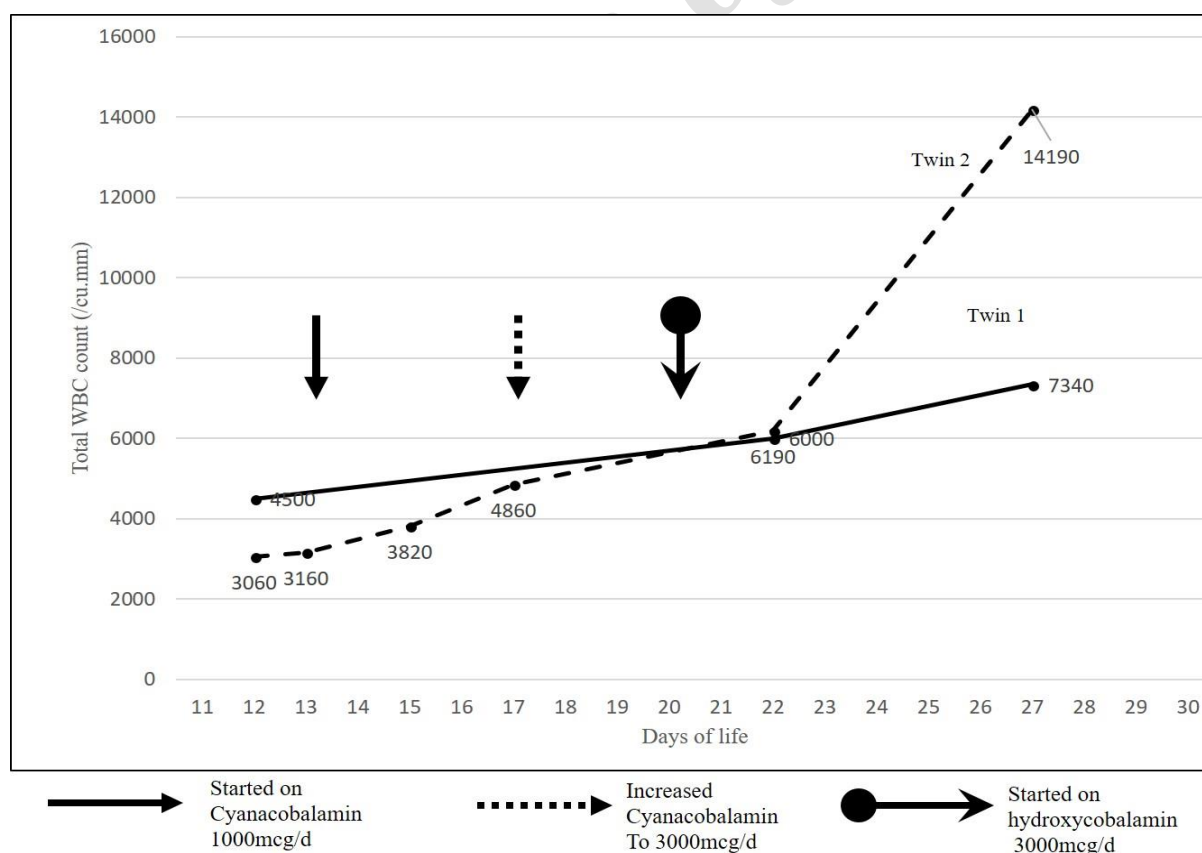


Fig.2: Trend in total Leucocyte count of the twins in response to B12 therapy.

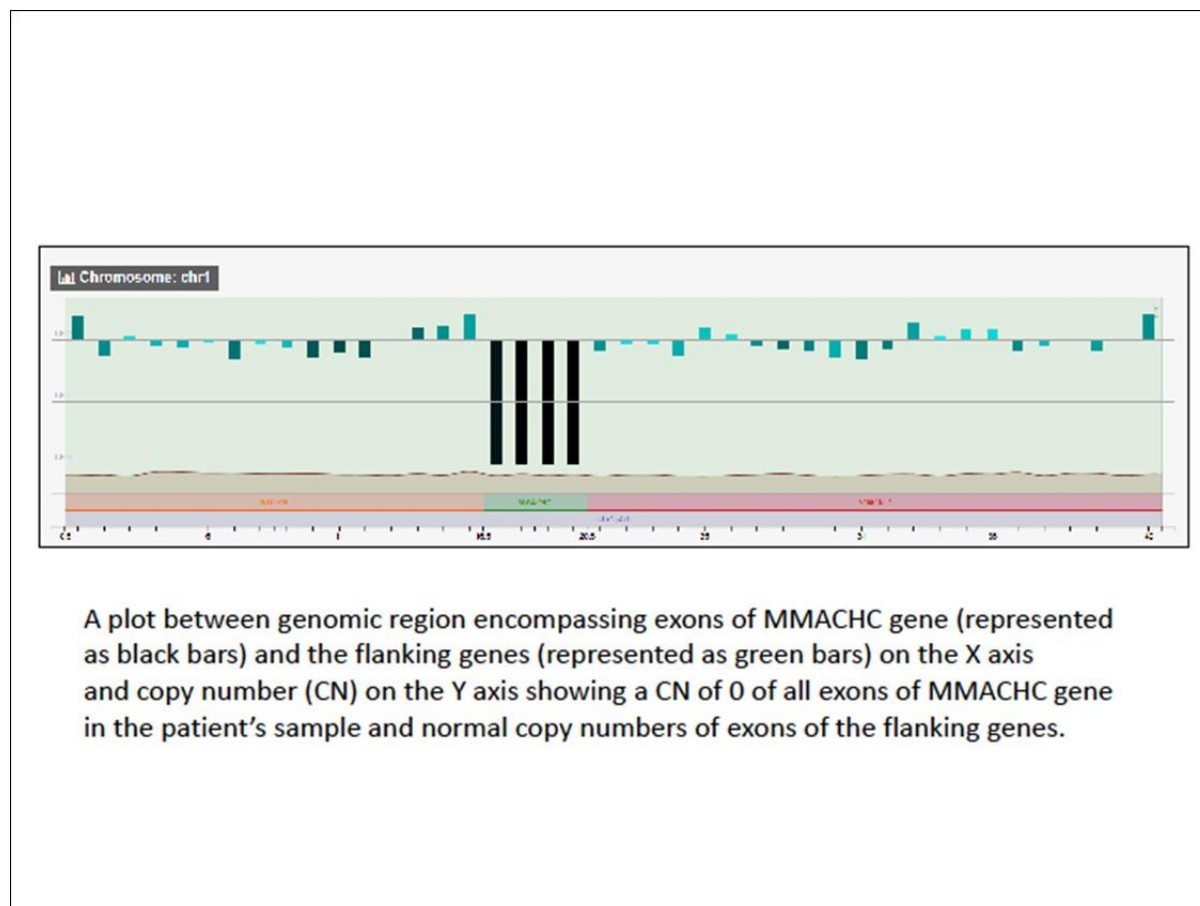


Fig.3: Representative figure showing the region of deletion in chromosome 1.

3- DISCUSSION

MMA cblC type (OMIM 277400), is the most common inborn error of intracellular cobalamin metabolism, with about 250 known cases with mutations in the MMACHC gene. The defect causes decreased levels of coenzymes adenosylcobalamin and methylcobalamin, which results in decreased activity of the respective enzymes Methylmalonyl-CoA mutase (MCM), and methionine synthase. Most subjects affected by this disorder present during early infancy with feeding difficulties, neurological dysfunction (Hypotonia, seizures, developmental delay), ophthalmological and hematological abnormalities. About 25% of those patients die within 1 year (3). Survival is associated with neurological

impairment with extrapyramidal signs, dementia, delirium or psychosis. Late onset disease is associated with less severe hematological abnormalities, largely involving the red cell series and has better survival with mild to moderate disability (3). Lerner-Ellis identified 42 different mutations in 204 patients with MMACHC gene (4, 5). Different combinations of mutations including c.331C>T, c.394C>T, c.365A>T, c.452A>G, c.609G>A, c.658_660delAAG, c.482G>A, c.394C>T, c.80A>G, c.482G>A, nonsense mutations (c.315C > G and c.615C > A), deletions (c.99delA and c.277-3_c.303del30), duplications (c.271dupA, c.248dupT and c.626dupT), and insertion (c.445_446insA), have been detected (5).

A literature search revealed that such large deletion mutations in Chromosome 1 involving the entire MMACHC gene identified in these twins has not been reported in earlier studies. The twins were homozygous for this mutation despite the parents being nonconsanguineous. Patients with cblC disease specifically respond to parenteral hydroxycobalamin rather than cyanocobalamin with a considerable improvement in biochemical parameters, hematological abnormalities and improvement in neurologic manifestations (1, 6) as it happened in our twins. A recent study showed that mutant MMACHC proteins have increased binding affinity to hydroxycobalamin when compared to cyanocobalamin (7). Also, in cell lines from cblC patients, hydroxycobalamin decreases the levels of intracellular reactive oxygen species. Protein restriction is not necessary to reduce Methylmalonic acid levels in patients with CblC type MMA receiving appropriate B12 doses. Furthermore, protein restriction poses the risk of limiting the daily intake of methionine and may accentuate hypomethioninemia in patients with cblC (8, 9).

4- CONCLUSION

Inborn errors of cobalamin metabolism should be suspected in any neonate with encephalopathy and hematological changes, particularly in the absence of metabolic acidosis and hyperammonemia. Prenatal genetic studies should include screening for mutations causing rarer variants of inborn errors of metabolism also. Hydroxycobalamin is more efficacious than cyanocobalamin for inborn error of cobalamin metabolism.

5- CONFLICT OF INTEREST: None.

6- REFERENCES

1. Carrillo-Carrasco N, Chandler RJ, Venditti CP. Combined methylmalonic acidemia and homocystinuria, cblC type. I. Clinical presentations, diagnosis and management. *Journal of Inherited Metabolic Disease*. 2012;35(1):91-102.
2. Zong Y, Liu N, Zhao Z, Kong X. Prenatal diagnosis using genetic sequencing and identification of a novel mutation in MMACHC. *BMC Medical Genetics*. 2015;16:48.
3. Rosenblatt DS, Aspler AL, Shevell MI, Pletcher BA, Fenton WA, Seashore MR. Clinical heterogeneity and prognosis in combined methylmalonic aciduria and homocystinuria (cblC). *J Inherit Metab Dis*. 1997;20(4):528-38.
4. Lerner-Ellis JP, Anastasio N, Liu J, Coelho D, Suormala T, Stucki M, et al. Spectrum of mutations in MMACHC, allelic expression, and evidence for genotype-phenotype correlations. *Human mutation*. 2009;30(7):1072-81.
5. Morel CF, Lerner-Ellis JP, Rosenblatt DS. Combined methylmalonic aciduria and homocystinuria (cblC): Phenotype-genotype correlations and ethnic-specific observations. *Molecular genetics and metabolism*. 2006;88(4):315-21.
6. Andersson HC SE. Biochemical and clinical response to hydroxocobalamin versus cyanocobalamin treatment in patients with methylmalonic acidemia and homocystinuria (cblC). *The Journal of Pediatrics*. 1998;132(1):121-4.
7. Froese DS, Zhang J, Healy S, Gravel RA. Mechanism of vitamin B12-responsiveness in cblC methylmalonic aciduria with homocystinuria. *Molecular genetics and metabolism*. 2009;98(4):338-43.
8. Bartholomew DW, Batshaw ML, Allen RH, Roe CR, Rosenblatt D, Valle DL, et al. Therapeutic approaches to cobalamin-C methylmalonic acidemia and homocystinuria. *J Pediatr*. 1988;112(1):32-9.
9. Baumgartner MR, Horster F, Dionisi-Vici C, Haliloglu G, Karall D, Chapman KA, et al. Proposed guidelines for the diagnosis and management of methylmalonic and propionic acidemia. *Orphanet J Rare Dis*. 2014;9:130.
1. Carrillo-Carrasco N, Chandler RJ, Venditti CP. Combined methylmalonic acidemia and homocystinuria, cblC type. I.