

## Prepubertal Diagnosis of Klinefelter Syndrome: A Rare Case Report

\*Pradyumna Pan<sup>1</sup>

<sup>1</sup>Pediatric Surgery Unit, Ashish Hospital and Research Centre, Jabalpur Madhya Pradesh, India 482001.

### Abstract

Klinefelter syndrome is characterised by advancing testicular function deterioration causing aspermatogenesis and androgen deficiency. Klinefelter patients characteristically have complete male sex differentiation, and genital anomalies are infrequently associated.

Penoscrotal malformations at birth are very rare in this syndrome. Nonetheless, it is important to know the association, as one of the causes of abnormal genitalia at birth. Understanding of the indications of karyotyping can help early detection of these cases. We report a boy who had Klinefelter syndrome with penoscrotal transposition (PST), hypospadias and inguinal hernia.

**Key Words:** Child, Genitals, Malformations, Klinefelter syndrome.

\*Please cite this article as: Pan P. Prepubertal Diagnosis of Klinefelter Syndrome: A Rare Case Report. Int J Pediatr 2018; 6(10): 8381-84. DOI: **10.22038/ijp.2018.32430.2857**

---

### \*Corresponding Author:

Pradyumna Pan, Qualifications: M.S (Surgery), M.Ch (Pediatric Surgery), Ashish Hospital and Research Centre, Jabalpur Madhya Pradesh, India 482001.

Email: [dr\\_pan@rediffmail.com](mailto:dr_pan@rediffmail.com)

Received date: Apr.20, 2018; Accepted date: May. 22, 2018

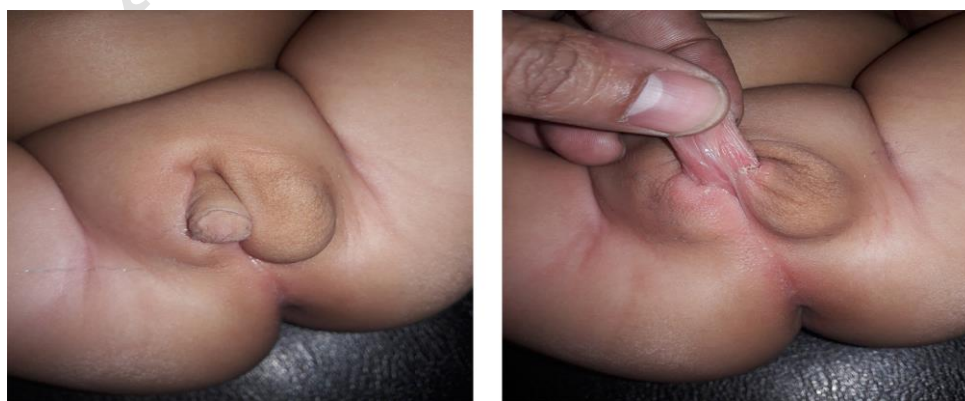## 1- INTRODUCTION

Klinefelter syndrome (KS) is the most common 1: 500–1000 sex chromosomal disorder in males, characterized by at least one extra X chromosome to a normal male karyotype (47 XXY). It affects male physical and cognitive development with varying signs and symptoms among affected individuals. Infants and children may present with small phallus, cryptorchidism, developmental and language delay, learning disabilities, or behavioral problems. The older child or adolescent may be noticed during an endocrine evaluation for delayed or incomplete pubertal development with eunuchoid body physique, gynecomastia, and small testes. Adults are picked up during investigation for infertility or breast malignancy. Androgen replacement therapy should begin at puberty, sufficient to maintain age appropriate serum concentrations of testosterone, estradiol, follicle stimulating hormone, and luteinizing hormone. Klinefelter syndrome is usually underdiagnosed in more than 50% of men and that 90% of those identified are diagnosed only post-puberty (1).

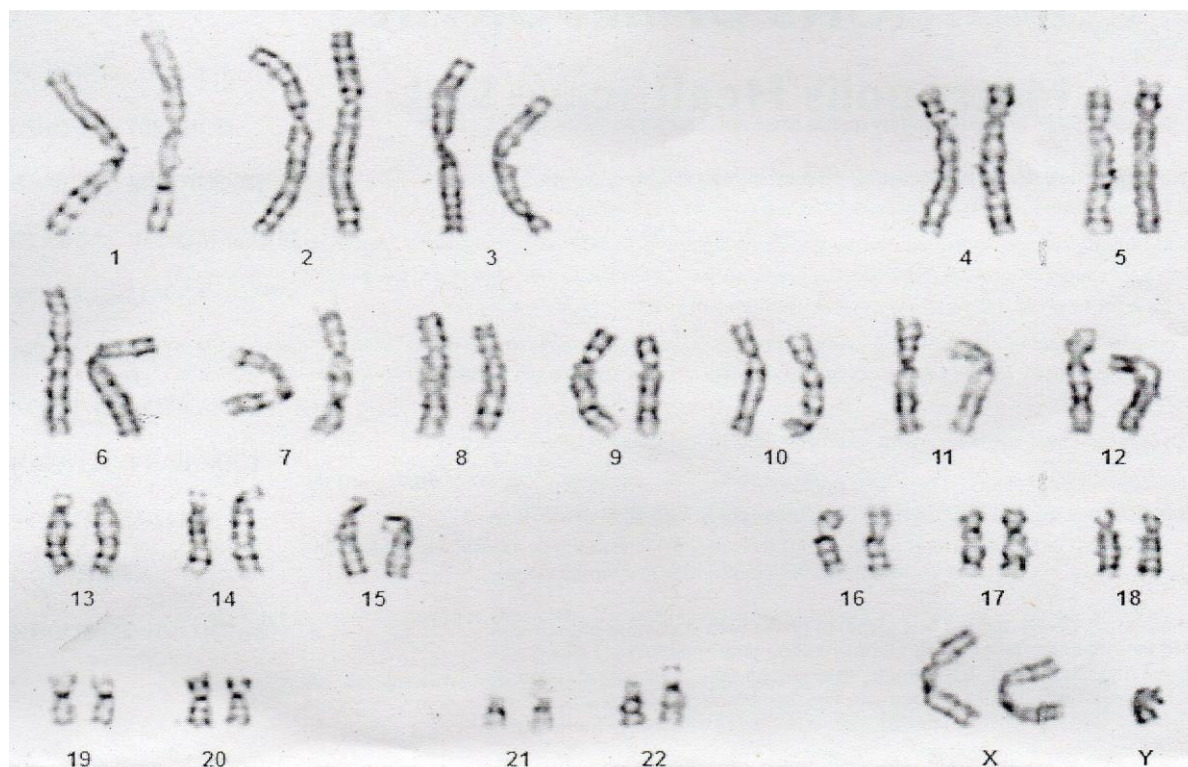
## 2- CASE REPORTS

A 22-month-old boy was referred to our pediatric urology unit (Ashish Hospital and Research Centre, Jabalpur, India) for evaluation and management of associated

hypospadias, chordee, and Penoscrotal transposition (PST). He was born in non-consanguineous family, to a primigravida mother of 33 years old, from an uncomplicated spontaneous vaginal delivery at term. She had no history of drug exposure, smoking, and alcohol intake during pregnancy. Also, there was no history of diabetes mellitus or hypertension. The child was 2,700 gr at birth and had an unremarkable postnatal course. On physical examination, he had penoscrotal hypospadias, severe ventral chordee and PST. He had a left side reducible inguinal hernia and the testes were normal in size, consistency and localized in the scrotum (**Figure.1**). Karyotype was sought and revealed 47 XXY (**Figure.2**). Serum luteinizing hormone, follicle- stimulating hormone, and testosterone levels was 7.1 and 2.3IU/l and 9ng/dl, respectively. Abdominal and pelvic ultrasound was normal and no Mullerian structures were identified. At 30 months, the boy underwent staged reconstructive surgery. In the first stage inguinal hernia was done, penile chordee and scrotal transposition were corrected. Subsequently urethroplasty was done after six months. The postoperative course was uneventful. The patient had good urinary stream and the cosmetic appearance of the genitalia during the immediate follow-up was satisfactory.



**Fig.1:** Clinical photo showing penoscrotal hypospadias, severe chordee, scrotal transposition and (L) Inguinal hernia.



**Fig.2:** Karyotype showing 47 XXY chromosomes.

### 3- DISCUSSION

Klinefelter et al. (2) in 1942 described a group of symptoms observed in some men with the extra X chromosome. The clinical features of Klinefelter syndrome are abnormalities of the external genitalia, tall height and gynecomastia. Other reported abnormalities associated are neurocognitive impairment mainly related to language processing disability, and varying degrees of social, behavioral, and learning difficulties (3), osteoporosis, cryptorchidism, psychiatric disturbances. Cryptorchidism is more frequent in patients with Klinefelter syndrome (4). High prevalence of Klinefelter syndrome in cryptorchid boy supports the indication of karyotype analysis. At puberty, the testes fail to increase in size and become firm due to a progressive loss of germ cells and seminiferous tubule hyalinization and fibrosis (5, 6). Concomitant penoscrotal anomalies with Klinefelter syndrome is rare (7). There are few reported cases and

they vary from penile chordee, hypospadias, and penoscrotal transposition. Klinefelter syndrome usually occurs randomly. An older mother and the maternal administration of estrogen or anti-androgen may have a slightly increased risk of a child with KS (7); in our reported case, maternal and family history was negative. The incidence of complete PST is low and may be associated with other renal anomalies, like renal agenesis. Androgen deficiency causes underdevelopment of speech, language, reading function and early pre-pubertal management with androgen can significantly improve their neurodevelopmental outcome (7) due to the presence of androgen receptors in temporal and pre-frontal cortex. While no cure is known, a number of treatments may help. Physical therapy, speech and language therapy, counselling, and adjustments of teaching methods may be useful. The age for testosterone replacement in these patients is

controversial (8), yet clear clinical and biochemical signs of hypo androgen are an undisputed indication for initiation of androgen therapy (9). Between 95% and 99% of XXY men are infertile because they do not produce enough sperms to fertilize an egg naturally. But, sperms are noted in more than 50% of men with KS (10, 11). Advances in assistive reproductive technology have provided an opportunity for some men with KS to conceive (6).

#### 4- CONCLUSION

Early detection of the disorder is highly desirable because it may permit early identification of speech and educational problems and also may ensure prospective monitoring of gonadal function development with the hope to compensating for possible gonadal insufficiency.

**5- CONFLICT OF INTEREST:** None.

#### 6- REFERENCES

1. Bojesen A, Juul S, Gravholt CH. Prenatal and postnatal prevalence of Klinefelter syndrome: A national registry study. *J Clin Endocrinol Metab.* 2003; 88: 622–6.
2. Klinefelter HF, Reifenstein EC, Albright F. Syndrome characterized by gynecomastia, aspermatogenesis without a leydigism, and increased excretion of follicle-stimulating hormone. *J clin Endocr* 1942; 2: 615-27.
3. Bonomi M, Rochira V, Pasquali D, Balercia G, Jannini EA, Ferlin A. Klinefelter syndrome: genetics, clinical phenotype and hypogonadism. *J Endocrinol Invest* 2017; 40: 123-34.
4. Gottlieb S, Rey RA, Malozowski S. Klinefelter syndrome and cryptorchidism. *The Journal of the American Medical Association.* 2009; 301:1436–37.
5. Das C, Sahana PK, Sengupta N, Roy M, Dasgupta R. Unusual presentation of Klinefelter syndrome. *Indian J Endocrinol Metab.* 2013 Dec; 17(Suppl 3): S683–S684.
6. Rohayem J, Nieschlag E, Zitzmann M, Kliesch S. Testicular function during puberty and young adulthood in patients with Klinefelter's syndrome with and without spermatozoa in seminal fluid. *Andrology* 2016; 4: 1178-86.
7. Hodhod A, Umurangwa F, Sherbiny M. Prepubertal diagnosis of Klinefelter syndrome due to penoscrotal malformations: Case report and review of literature. *Can Urol Assoc J.* 2015; 9(5-6): E333–E336.
8. Host C, Skakkebaek A, Groth KA, Bojesen A. The role of hypogonadism in Klinefelter Syndrome. *Asian J Androl.* 2014 Mar-Apr; 16(2): 185–91.
9. Pacenza N, Pasqualini T, Gottlieb S, Knoblovits P, Costanzo P R, Usher JS, et al. Clinical Presentation of Klinefelter's Syndrome: Differences According to Age. *International Journal of Endocrinology* Volume 2012: 1-6. Article ID 324835, 6 pages.
10. Franik S, Hoeijmakers Y, D'Hauwers K, Braat DDM, Nelen WLM, Smeets D et al. Klinefelter syndrome and fertility: sperm preservation should not be offered to children with Klinefelter syndrome. *Human Reproduction* 2016; 31(9): 1952–59.
11. Aksglaede L, Juul A. Testicular function and fertility in men with Klinefelter Syndrome: a review. *Eur J Endocrinol* 2013; 168: 67-76.