



## Retroperitoneal Hemorrhage in a Neonate: A Rare Presentation of Hemophilia B

Haroon Anila<sup>1</sup>, \*Shakeel Ahmed<sup>1</sup>, Syed Rehan Ali<sup>1</sup>

<sup>1</sup>Department of Pediatrics, Memon Medical Institute Hospital, Karachi –74800, Pakistan.

<sup>2</sup>Department of Pediatrics, Bahria University of Medical and Dental College, Karachi –74800, Pakistan.

<sup>3</sup>Department of Pediatrics, Indus Hospital, Karachi –74800, Pakistan.

### Abstract

Hemophilia is one of the most common inherited coagulation disorder; with almost half of the cases presents in the neonatal period with bleeding episodes specially post circumcision, although family history is present in about two third cases. Retroperitoneal hemorrhage is a very rare presentation of hemophilia and to the best of our knowledge has not described yet, as initial presentation of hemophilia B in the neonatal period. We are presenting retroperitoneal hemorrhage as initial presentation of hemophilia B, in the presence of family history which has not been disclosed till the baby become symptomatic.

**Key Words:** Hemophilia, Neonate, Retroperitoneal Hemorrhage.

\*Please cite this article as: Anila H, Shakeel A, and Syed Rehan A. Retroperitoneal Hemorrhage in a Neonate: A Rare Presentation of Hemophilia B. Int J Pediatr 2019; 7(3): 9081-84. DOI: **10.22038/ijp.2018.34415.3029**

### \*Corresponding Author:

Dr. Ahmed Shakeel, Bahria University Medical and Dental College, Karachi –74800, Pakistan, 0092-21-34864795.

Email: shakeel.ahmed@aku.edu

Received date: Jun.17, 2018; Accepted date: Oct. 22, 2018

## 1- INTRODUCTION

Hemophilia is a coagulation disorder caused by deficiency of factor VIII (hemophilia A) or factor IX (Hemophilia B) with prevalence in the general population of approximately 1:5000 and up to 1:50,000 respectively (1). Hemophilia A and B are X linked recessive disorders; however 30% of cases occurs as spontaneous mutation (2). Hemophilia A and B are found in populations throughout the world and do not appear to have any ethnic or racial predisposition (2). Two thirds of patients with hemophilia have a positive family history of hemophilia, and yet the diagnosis of hemophilia is frequently not suspected until the first bleeding symptoms occurs.

The severity of hemophilia is classified on the basis of factor VIII and IX levels as mild (>5% to <40%), moderate (1-5%) or severe (<1%) (3, 4). We are reporting a case of hemophilia B in neonate who presented with severe pallor and retroperitoneal hemorrhage; a very rare presentation. To the best of our knowledge hemophilia B with initial presentation of retroperitoneal hemorrhage in neonatal period has not described yet in the literature.

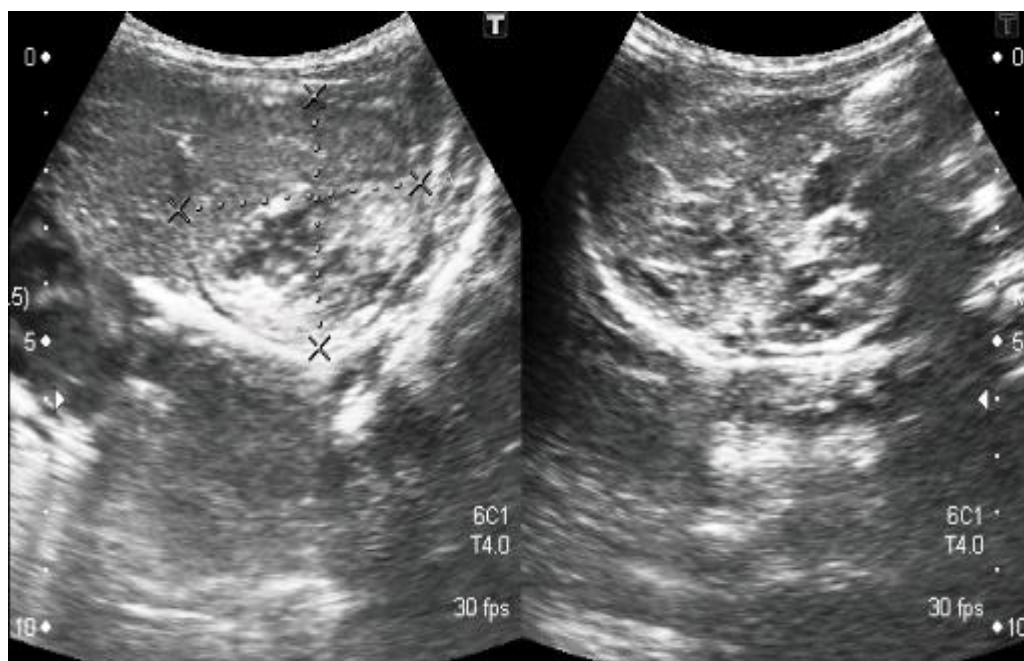
## 2- CASE REPORTS

Written informed consent was obtained from the parents of the baby. A 4 days old baby boy presented with severe pallor noticed for one day. He was born at full term, with birth weight of 3,200 gr by elective cesarean section at local hospital to a young multigravida mother. APGAR score was normal and antenatal history was uneventful. His parents have non-consanguineous marriage, and there is history of one male sibling death at three hours of life. There was no significant bleeding during umbilical cord clamping

and vitamin K was administered at birth. He was remained well and vitally stable for first three days of life. On fourth day of life parents noticed that the baby found to be severely pale. On examination, he was vitally stable with no evidence of hypovolemic shock. Systemic examination revealed mild abdominal distension and discoloration, rest of the examination was unremarkable. He was shifted to neonatal intensive care unit (NICU) for close monitoring and detailed investigations to find out the cause of severe pallor.

On inquiring regarding the family history mother mentioned that her sister's four year son has been diagnosed as hemophilia. Investigations showed severe anemia with hemoglobin of 5.8 mg/dl (14-22 mg/dl day 1-3), and there was no evidence of hemolysis, white cell and platelet count was within normal range, he had raised indirect bilirubin of 14 mg/dl (1-1.2 mg/dl). Coagulation profile showed normal prothrombin time (PT) 12.6 seconds (N 9-14sec), but activated partial thromboplastin time (APTT) was prolonged 67.5 seconds (25-35 sec).

Specific factor assay revealed normal Factor VIII level, 110% (100-150%), while factor IX was significantly low 0.6% (100-150%). Ultrasound brain has no evidence of intracranial bleed, Ultrasound abdomen (**Figure.1**) revealed a large retroperitoneal hemorrhage. Baby was twice transfused with packed red cell because of low hemoglobin. Initially FFP was transfused 6 hourly, repeat factor IX was improved 54% so transfusion of FFP was spaced out on every other day; repeat ultrasound after one week showed resolution of retroperitoneal hematoma. Baby was discharged after ten days in stable condition, with instruction of transfusion of FFP twice a week and follow up in hematology clinic.



**Fig.1:** Ultrasound of Abdomen showed a large retroperitoneal hematoma.

### 3- DISCUSSION

Hemophilia are the most common clotting disorders globally. These disorders are transmitted through X-linked recessive pattern. Majority (approx.80-85%) of cases are hemophilia A due to F VIII deficiency, while 15±20% are of Hemophilia B due to F IX deficiency. Hemophilia is classified as mild (5% to 40%), moderate (1-5%), as and severe (less than 1%) (4). Majority of the cases presents with hemorrhage in the neonatal period or early infancy. Roughly two-third of newly diagnosed infants have a family history of hemophilia. The majority of newborn with hemophilia are still diagnosed following a bleeding episode due to variety of reasons: one third have no family history, in others despite the presence of family history parents may not understand the risk of having an affected infant as in our case. In recent years compared to the past the diagnosis of severe hemophilia has been made at an earlier age. Pollman et al. in a ten year single study diagnosed 38% of patients in the first month of life all of whom presented with bleeding event (5). The

types of bleeding episodes in 349 newborns reported Kulkarni and Lusher in 66 publications showed the most common site of bleeding was cranium (27%), followed by cephalohematoma (13%), puncture side bleed (16%), circumcision (30%), umbilical stump (6%), and less than 5% of the bleed were from gastrointestinal tract /oral cavity, parenchymal organ, ecchymosis (6). After an extensive literature review, retroperitoneal hemorrhage in neonate as initial presentation has been reported in just one case of hemophilia A (7).

Neither F VIII nor F IX cross the placenta and, thus, a diagnosis of hemophilia can usually be made from a blood sample obtained at birth (8). Despite the availability of prenatal diagnosis, the majority of the newborns with hemophilia are still being diagnosed following a bleeding episode More recently, Pollman et al. (1999), in a 10-year single center study, diagnosed 38% (14 out of 37) of patients with hemophilia in the first month of life, all of whom had presented with bleeding events (5). In neonates,

intracranial hemorrhage may be the initial hemorrhage (cephalohematoma and Subgaleal hemorrhage) a life-threatening complication can occur regardless of the severity of hemophilia (9). Prenatal diagnosis of hemophilia via chorionic villus sampling is the most widely used method, but amniotic fluid, fetal blood, and pre-implantation genetic diagnostics can also be used in selected cases (10).

#### 4- CONCLUSION

Retroperitoneal hemorrhage a rare presentation of hemophilia, although there is possibility of number of cases which has not been reported in the literature. In the presence of family history as in our case which the parents has not revealed till the baby becomes symptomatic, counseling by hematologist regarding the antenatal diagnosis, the disease and its treatment, parental options and management of future pregnancies can manage the condition appropriately. It is important to established early and prompt diagnosis to reduce the morbidity and possible mortality with hemophilia.

#### 5- FUNDING

The authors received no financial support for the research, authorship, and/or publication of this article.

#### 6- CONFLICT OF INTEREST

The authors declared no conflicts of interest with respect to the research, authorship, and/or publication of this article.

#### 7- REFERENCES

1. Soucie JM, Evatt B, Jackson D. Occurrence of hemophilia in the United States. The Hemophilia Surveillance System Project Investigators. *Am J Hematol.* 1998; 59:288-94.

2. Peyvandi F, Duga S, Akhavan S, Mannucci PM. Rare coagulation deficiencies. *Hemophilia.* 2002; 8(3):308-21.

3. Blanchette VS, Key NS, L Jung LR, Manco-Johnson MJ, van den Berg HM, Srivastava A. Definitions in hemophilia: communication from the SSC of the ISTH. *J Thromb Haemost.* 2014; 12:1935-39.

4. White GC 2nd, Rosendaal F, Aledort LM, Lusher JM, Rothschild C, Ingerslev J. Definitions in hemophilia. Recommendation of the scientific subcommittee on factor VIII and factor IX of the scientific and standardization committee of the International Society on Thrombosis and Haemostasis. *Thromb Haemost.* 2001; 85:560.

5. Pollmann H, Richter H, Ringkamp H, Jurgens H. When are children diagnosed as having severe haemophilia and when do they start to bleed? A 10-year single-center PUP study. *Eur J Pediatr.* 1999; 158(suppl 3):S166-S170.

6. Kulkarni R, Lusher JM. Intracranial and extracranial hemorrhages in newborns with hemophilia: a review of the literature. *J Pediatr Hematol Oncol.* 1999; 21:289-95.

7. Grizelj R, Vukovic J, Bilic E, Stern-Padovan R. Massive retroperitoneal haemorrhage in a neonate with severe hemophilia A. *Hemophilia.* 2011; 17:547-8.

8. Carcao MD. The diagnosis and management of congenital hemophilia. *Semin Thromb Hemost.* 2012; 38:727-734.

9. Richards M, Lavigne Lissalde G, Combescure C, Batorova A, Dolan G, Fischer K, et al. Neonatal bleeding in haemophilia: a European cohort study. *Br J Haematol.* 2012; 156: 374-82.

10. Esther Kisseih, Neeraja Yerrapotu, Deepak Yadav. A Case of Hemophilia A Presenting in a Neonate and a Review of the Literature *Glob Pediatr Health.* 2017; 4: 1-3.