



Mccune-Albright Syndrome: A Case Report Associated with Pamidronate Therapy and Literature Review

Rahim Vakili^{1,2}, *Somayyeh Hashemian³, Reza Jafarzadeh Esfehiani⁴, Azadeh Zare Feizabadi¹

¹Department of Pediatric Endocrinology and Metabolism, Imam Reza Hospital, Faculty of Medicine, Mashhad University of Medical Sciences, Mashhad, Iran.

²Medical Genetic Research Center, Mashhad University of Medical Sciences, Mashhad, Iran.

³Department of Pediatric Endocrinology and Metabolism, Akbar Hospital, Faculty of Medicine, Mashhad University of Medical Sciences, Mashhad, Iran.

⁴Department of Medical Genetics, Faculty of Medicine, Mashhad University of Medical Sciences, Mashhad, Iran.

Abstract

McCune-Albright Syndrome (MAS) is a rare sporadic disease characterized by bone fibrous dysplasia, Café au lait spots and a variable association of hyperfunction endocrine disorders. There is not any certain treatment available for this syndrome, and both physical and emotional disability in these patients is still a major concern for physicians. In present report we have described a 10- year-old girl, presented with precocious puberty, multiple Café au lait macules and fibrous dysplasia, successfully treated with pamidronate in a four-year follow-up period.

Key Words: Children, Iran, Fibrous dysplasia, McCune-Albright syndrome, Precocious puberty.

*Please cite this article as: Vakili R, Hashemian S, Jafarzadeh Esfehiani R, Zare Feizabadi A. Mccune-Albright Syndrome: A Case Report Associated with Pamidronate Therapy and Literature Review. Int J Pediatr 2019; 7(5): 9453-59. DOI: **10.22038/ijp.2019.36513.3181**

*Corresponding Author:

Somayyeh Hashemian (M.D), Department of Pediatric Endocrinology and Metabolism, Akbar Hospital, Faculty of Medicine, Mashhad University of Medical Sciences, Mashhad, Iran.

Email: hashemians951@mums.ac.ir

Received date: Jul.23, 2018; Accepted date: Feb.22, 2019

1- INTRODUCTION

McCune-Albright syndrome is defined as a multiple genetic disorder involving skin, bone and endocrine system (1-3). The prevalence of McCune–Albright syndrome has been estimated to range from 1/100,000 to 1/1,000,000 in general population (2, 4). This syndrome is mostly characterized by bone fibrous dysplasia, Café-au-lait spots and variable association of hyperfunction endocrine disorders (5, 6). Fibrous dysplasia (FD), which can involve the craniofacial, axial, and appendicular skeleton, may range from an isolated, asymptomatic monostotic (single bone) lesion to a severe disabling polyostotic form of the disease of the entire skeleton (7, 8).

Café-au-lait skin spots are defined as hyperpigmented macules with irregular and wavy borders mostly seen on the buttocks, neck, back and trunk (9). The origin of MAS is sporadic activation of GNAS genes that mainly affect codon 201 as a missense mutation and cause a mosaic disease (10-12). GNAS gene complex mutation involves independent activation of protein alpha subunit of G protein (Gs), and the signaling cascade mediated by protein kinase A (13).

MAS is also associated with several forms of endocrine dysfunction including hyperthyroidism, pituitary adenomas (excessive secretion of growth hormone, hyperprolactinemia), adrenal primary hyperplasia (Cushing syndrome), ovarian cysts and hypophosphatemia (14). Here, we will discuss a case of McCune–Albright syndrome which has received Pamidronat for 4 years (1 mg/kg for 3 days, every three months).

2- CASE REPORT

A 10- year-old girl was first presented at the age of 6 year-old (in 2012) to pediatric endocrinology clinic in Imam Reza hospital, Mashhad University of

Medical Sciences, Mashhad, Iran, because of precocious puberty with stage 3 of sexual maturity rating and one episode of vaginal bleeding. Physical examination revealed 120 cm height and weighting 28 kg. Also, Café-au-lait skin spots at the right side of the face were prominent (**Figure.1**). Abdominopelvic ultrasound study revealed several ovarian cysts. Radiologic evidence of several lytic lesions in the skull, metacarpus and phalanxes of both hands, right femoral met diaphysis and deformity of humeral head were present, which suggested fibrous dysplasia (**Figures 2-5**).

A brain MRI was performed for a better evaluation and differentiating fibrous dysplasia from other entities. On *T1*-weighted and *T2*-weighted scans of MRI, there was heterogeneous signal, usually low, as well as increased thickness of Carvalium at left frontal area and base of the skull in anterior cranial fossa (**Figures 6, 7**). Other laboratorial tests including thyroid, adrenal, renal and pituitary tests did not show any remarkable results. The patient was diagnosed as McCune–Albright syndrome and a treatment regimen of gonadotropin-releasing hormone (Gn-RH) agonist was started. After 6 months, decrease in signs of early puberty and no vaginal bleeding was achieved. However, the patient began to experience right sided claudication.

Due to multiple fibrous dysplasia symptoms and severe bone pain, pamidronate was prescribed (1 mg/kg every three month). Three months later, after first injection, the bone pain was decreased and claudication improved. The treatment was continued every three months. After 2 years the dose of pamidronate was decreased to 0.5 mg/kg. At the age of 10 years-old, the height and weight were reported as 142 cm and 47 kg. The bone age was similar to 12 years. Also, there was no sign of ovarian cysts on ultrasound study.



Fig.1: CT Angiogram showing giant aneurysm.

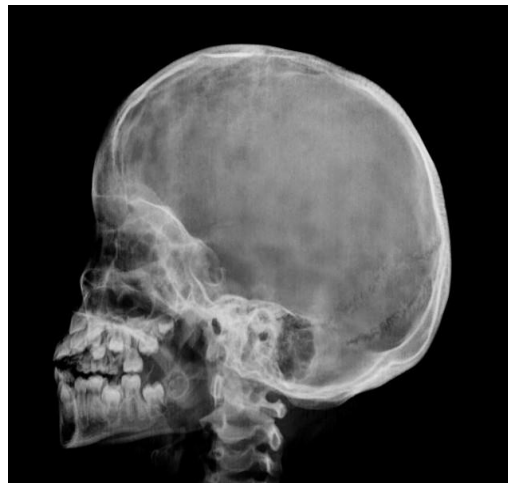

Fig.2: Lytic lesion on skull and mandibular bone esion in expansion in skull radiograph.

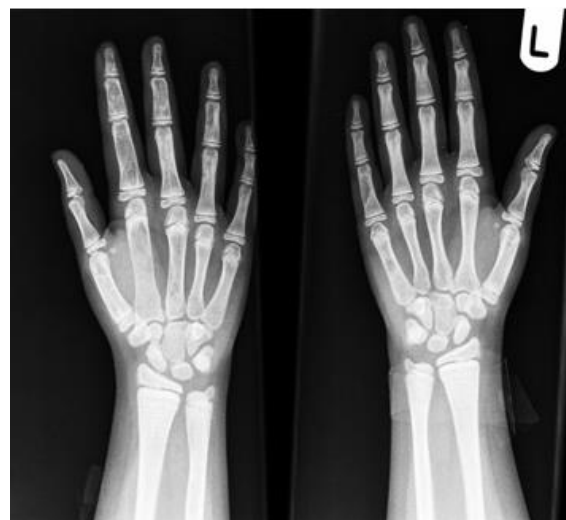


Fig.3: Hand radiograph shows lytic metacarpus and phalanxes.

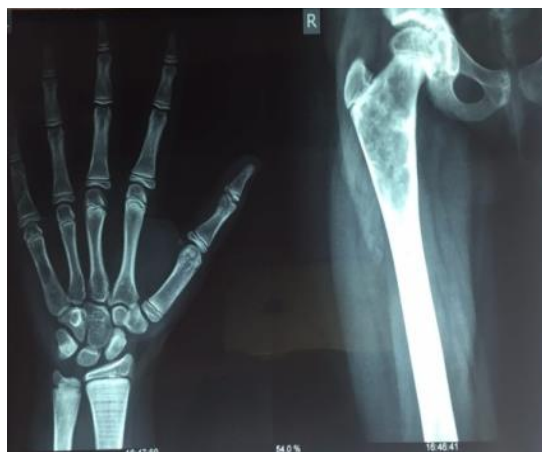

Fig.4: Cystic expansion in met diaphysis of Right femoral head and metacarpus and phalanges of left hand.

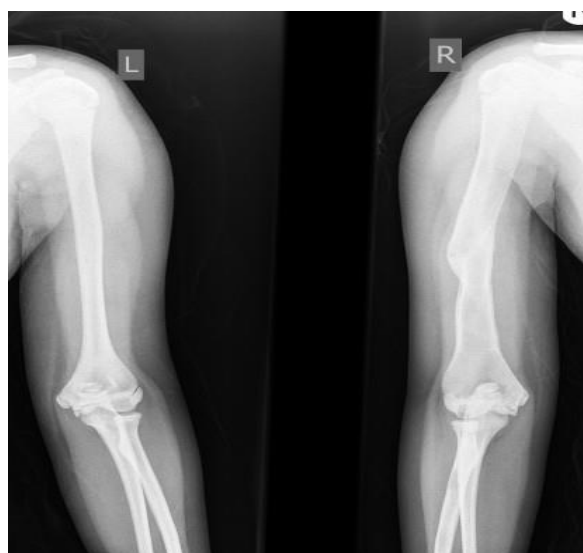


Fig.5: Deformity in body of humerus due to old fracture is shown.

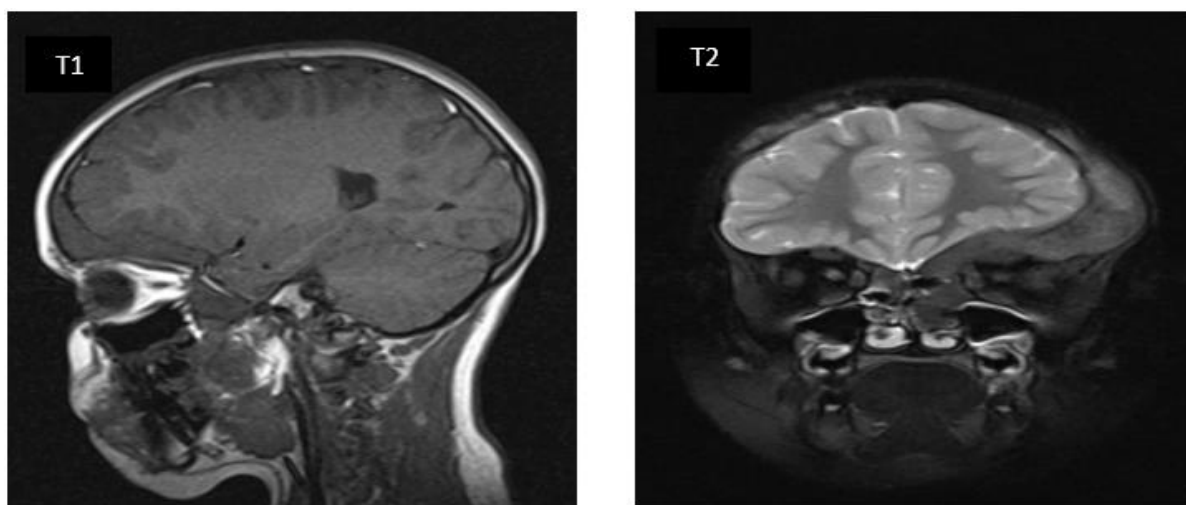


Fig.6: Heterogeneous signal in T1 and T2 weighted images shows increased thickness of calvarium.

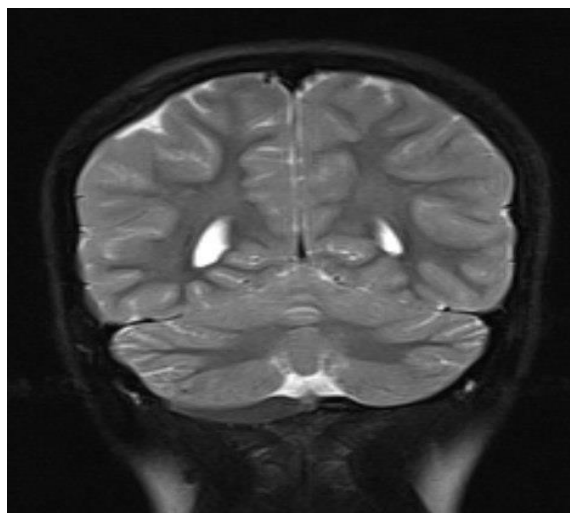


Fig.7: Involvement of base of the skull is demonstrated.

3- DISCUSSION

In McCune–Albright syndrome, skin pigmentation, bone deformities and endocrine disorders develop from an activating mutation in GS gene (15). This genetic syndrome is a result of post-zygotic somatic mutation in the gene *GNAS 1* on the chromosome 20q13-13.29, coding the alpha subunit of stimulatory G protein (Gas) (16). Current case was a 10-year-old girl with precocious puberty and vaginal bleeding at 5.5 years of age. The Café au lait skin spots with irregular border on face, several ovarian cysts and fibrous dysplasia at metacarpus, femoral met diaphysis and humerus were the findings toward McCune–Albright syndrome diagnosis. Similarly, in 2008, Xavier et al. reported the precocious puberty in their review of two cases diagnosed as McCune–Albright syndrome (9). Also, a similar study by Siadati and Shafiq in 2010 reported precocious puberty, facial asymmetry, mandibular enlargement, elevation in serum alkaline phosphatase level, short stature, limping and limb deformity; however, in our patient we have not evaluated alkaline phosphatase level (17). In this patient, fibrous dysplasia was seen at metacarpus, femoral met diaphysis and shaft of the humerus. Correspondingly, Liang et al.

reported the same feature for FD in 2006 (18). Akintoye et al. in 2003 reported several dental anomalies related to fibrous dysplasia (19). FD can affect 75% of the skeleton. Bone lesions have slow, progressive and asymmetric growth, resulting in asymmetry. The etiology of this feature is not well known, but some studies have shown an interruption of bone maturation in developmental phase (20). Studies have suggested a genetic mutation that occurs during the embryonic phase which is considered as the molecular mechanism responsible for disease development. This mutation happens on the *GNAS* gene encoding the guanine nucleotide-binding protein (Gs protein), responsible for binding receptors to the adenylyl cyclase enzyme. Hence, the mutation results in an activation of Gs protein with an excessive production of recurrent Adenosine monophosphate (AMP), leading to hyperfunction of the target tissue cells (9). The radiographic aspect of fibrous dysplasia differs and appears in different shapes depending on the stage of disease progression. Other findings suggest an increased incidence of cancer in adulthood in FD patients (21). For this patient, we used Pamidronate Injection for treatment; no bone pain was reported, but FD was present in limbs. Ultrasonography showed no ovarian cyst.

Correspondingly, Chapurlat in 2006 and Plotkin et al. in 2003, used Bisphosphonates to relieve bone pain and improve lytic lesions (22, 23). Totally, treatment with bisphosphonates appears to be well tolerated among children and adolescents, even in long term use (24). Use of bisphosphonate may reduce the comorbidities. Long term (>5 years) treatment with bisphosphonate is associated with severe suppression of bone turnover and results in atypical fracture of long bones (25). Zacharin and O'Sullivan prescribed bisphosphonates (Pamidronate 1 mg/kg/day for 3 days every 6 months for 2 years), and reported marked reduction in bone pain, fracture rate and increased mobility and bone mineral density (26). Leins et al. used intravenous pamidronate (60 mg/day for 3 days every 6 months), and followed their patients for 18 to 48 months. They have reported decrease in bone pain and markers of bone turnover, improvement in radiographic appearance of lesions and increase in bone mineral density of affected areas (27), which is similar to our findings. Consistent with current study, Benhamou et al. reported pamidronate as the most commonly used drug for bone pain treatment, especially as the first line (28). Another study suggested the beneficial and safe outcome of long term bisphosphonate therapy in majority of patients with polyostotic fibrous dysplasia; although response to therapy was limited by the higher skeletal disease burden in McCune-Albright syndrome patients (29).

4- CONCLUSION

Despite the mentioned treatment approaches, there is still no certain treatment for this syndrome. Because of the variety of lesions, there must be specific treatment for each patient; however, an accurate differential diagnosis is essential to determine the appropriate and optimal approach for each case. Based on our experience, bisphosphonate therapy can be a good choice in these patients.

5- CONFLICT OF INTEREST: None.

6- REFERENCES

1. Heller AJ, DiNardo LJ, Massey D. Fibrous dysplasia, chondrosarcoma, and McCune-Albright syndrome. *American journal of otolaryngology*. 2001;22(4):297-301.
2. Dumitrescu CE, Collins MT. McCune-Albright syndrome. *Orphanet journal of rare diseases*. 2008;3(1):12.
3. Zhou J, Sun L-h, Cui B, Song H-d, Li X-y, Ning G, et al. Genetic diagnosis of multiple affected tissues in a patient with McCune-Albright syndrome. *Endocrine*. 2007;31(2):212-7.
4. Chapurlat RD, Orcel P. Fibrous dysplasia of bone and McCune-Albright syndrome. *Best practice & research Clinical rheumatology*. 2008;22(1):55-69.
5. Albright F, Butler AM, Hampton AO, Smith P. Syndrome characterized by osteitis fibrosa disseminata, areas of pigmentation and endocrine dysfunction, with precocious puberty in females: report of five cases. *New England Journal of Medicine*. 1937; 216(17):727-46.
6. Collins MT, Singer FR, Eugster E. McCune-Albright syndrome and the extraskelatal manifestations of fibrous dysplasia. *Orphanet journal of rare diseases*. 2012;7(1):S4.
7. Raus I, Coroiu RE. McCune Albright syndrome - association of fibrous dysplasia, café-au-lait skin spots and hyperthyroidism - case report. *Clujul Med*. 2016; 89(4):559-564.
8. Medow JE, Agrawal BM, Resnick DK. Polyostotic fibrous dysplasia of the cervical spine: case report and review of the literature. *The Spine Journal*. 2007;7(6):712-5.
9. Xavier SP, Ribeiro MC, Sicchieri LG, Brentegani LG, Lacerda SA. Clinical, microscopic and imaging findings associated to McCune-Albright syndrome: report of two cases. *Brazilian dental journal*. 2008;19(2):165-70.
10. Agopiantz M, Journeau P, Lebon-Labich B, Sorlin A, Cuny T, Weryha G, Leheup B. McCune-Albright syndrome, natural history and multidisciplinary

management in a series of 14 pediatric cases. *Ann Endocrinol (Paris)*. 2016;77(1):7-13

11. Weinstein LS. Gs α Mutations in Fibrous Dysplasia and McCune-Albright Syndrome. *Journal of Bone and Mineral Research*. 2006;21(S2):P120-P4.

12. Collins MT, Sarlis NJ, Merino MJ, Monroe J, Crawford SE, Krakoff JA, et al. Thyroid carcinoma in the McCune-Albright syndrome: contributory role of activating Gs α mutations. *The Journal of Clinical Endocrinology and Metabolism*. 2003; 88(9): 4413-17.

13. Weinstein L.S., Yu S., Warner D.R., Liu J. Endocrine manifestations of stimulatory G protein alpha-subunit mutations and the role of genomic imprinting *Endocr Rev* 2001; 22: 675-705.

14. Rubio NI, Nader Sh, Brosnan PG. McCune Albright syndrome: case report and review of literature. *Int J Endocrinol Metab* 2006;4(3):167-75.

15. Mobini M, Vakili R, Vakili S. McCune-Albright Syndrome: A case report and literature Review. *International Journal of Pediatrics*. 2014;2(2.2):153-6.

16. Kumar N, Kheruka SC, Singh RKR, Ravina M, Dutta D, Gambhir S. Hypothyroidism in mcccune-albright syndrome and role of bone scan in management of fibrous dysplasia: An unusual case scenario with review of literature. *Indian Journal of Nuclear Medicine*. 2017;32(1):25.

17. Siadati S, Shafigh E. McCune-Albright syndrome: a case report. *Arch Iran Med*. 2010;13(3):245-7.

18. Liang L, Meng Z, Zeng Q, Li W. McCune-Albright syndrome: a difficult and complicated case study. *Zhongguo dang dai er ke za zhi= Chinese journal of contemporary pediatrics*. 2006;8(4):311.

19. Akintoye SO, Lee JS, Feimster T, Booher S, Brahim J, Kingman A, et al. Dental characteristics of fibrous dysplasia and McCune-Albright syndrome. *Oral Surgery, Oral Medicine, Oral Pathology, Oral Radiology, and Endodontology*. 2003;96(3):275-82.

20. Weinstein LS, Chen M, Liu J. Gs α mutations and imprinting defects in human

disease. *Annals of the New York Academy of Sciences*. 2002;968(1):173-97.

21. Ruggieri P, Sim FH, Bond JR, Krishnan Unni K. Malignancies in fibrous dysplasia. *Cancer*. 1994;73(5):1411-24.

22. Chapurlat RD. Medical therapy in adults with fibrous dysplasia of bone. *Journal of Bone and Mineral Research*. 2006;21(S2):P114-P9.

23. Plotkin H, Rauch F, Zeitlin L, Munns C, Travers R, Glorieux FH. Effect of pamidronate treatment in children with polyostotic fibrous dysplasia of bone. *The Journal of Clinical Endocrinology & Metabolism*. 2003;88(10):4569-75.

24. Classen CF, Mix M, Kyank U, Hauenstein C, Haffner D. Pamidronic acid and cabergoline as effective long-term therapy in a 12-year-old girl with extended facial polyostotic fibrous dysplasia, prolactinoma and acromegaly in McCune-Albright syndrome: a case report. *Journal of medical case reports*. 2012;6(1):32.

25. Bhadada SK, Bhansali A, Das S, Singh R, Sen R, Agarwal A, et al. Fibrous dysplasia & McCune-Albright syndrome: An experience from a tertiary care centre in north India. *Indian Journal of Medical Research*. 2011;133(5):504.

26. Zacharin M, O'sullivan M. Intravenous pamidronate treatment of polyostotic fibrous dysplasia associated with the McCune Albright syndrome. *The Journal of pediatrics*. 2000;137(3):403-9.

27. Liens D, Delmas PD, Meunier P. Long-term effects of intravenous pamidronate in fibrous dysplasia of bone. *The Lancet*. 1994;343(8903):953-4.

28. Benhamou J, Gensburger D, Messiaen C, Chapurlat R. Prognostic Factors From an Epidemiologic Evaluation of Fibrous Dysplasia of Bone in a Modern Cohort: The FRANCEDYS Study. *Journal of Bone and Mineral Research*. 2016;31(12):2167-72.

29. Majoor BC, Appelman-Dijkstra NM, Fiocco M, van de Sande MA, Dijkstra P, Hamdy NA. Outcome of Long-Term Bisphosphonate Therapy in McCune-Albright Syndrome and Polyostotic Fibrous Dysplasia. *J Bone Miner Res*. 2017;32(2):264-276.