

Idiopathic Chylothorax in a Term Neonate and Successful Treatment with Octreotide and Medium Chain Triglyceride - Enriched Formula: A Case Report

*Kamran Dehghan¹

¹Assistant Professor of Neonatology, Urmia University of Medical Sciences, Urmia, Iran.

Abstract

Background

Chylothorax is defined as abnormal accumulation of lymphatic fluid in the pleural space secondary to leakage from thoracic duct or one of its main tributaries. Congenital idiopathic chylothorax is the most common form of pleural effusion in neonates. Conservative therapy is the mainstay of treatment. An alternative therapy is Octreotide, which is a long-acting somatostatin analog that can reduce lymphatic fluid production. It has been used for the treatment of chylothorax in children, but it is used as a new strategy for the treatment of chylothorax in neonates.

Case Report

We herein report a case of idiopathic unilateral chylothorax in a 3-day-old Iranian male neonate who was treated successfully with conservative therapy, octreotide and regimen therapy with medium-chain triglyceride (MCT)-enriched formula.

Conclusion

Chylothorax may be suspected in patients with pleural effusions. Pleural fluid triglyceride measurement remains the recommended diagnostic method in chylothorax

Key Words: Chylothorax, Neonate, Octreotide.

*Please cite this article as: Dehghan K. Idiopathic Chylothorax in a Term Neonate and Successful Treatment with Octreotide and Medium Chain Triglyceride -Enriched Formula: A Case Report. Int J Pediatr 2019; 7(6): 9535-40. DOI: [10.22038/ijp.2019.38710.3310](https://doi.org/10.22038/ijp.2019.38710.3310)

*Corresponding Author:

Kamran Dehghan (M.D), Assistant Professor of Neonatology, Urmia University of Medical Sciences, Urmia, Iran.

Email: k.dehghannn1@gmail.com

Received date: Jan.11, 2019; Accepted date: Mar.22, 2019

1- INTRODUCTION

Chylothorax is defined as abnormal accumulation of lymphatic fluid in the pleural space secondary to leakage from thoracic duct or one of its main tributaries. It is a relatively rare condition in newborns. In newborns, chylothorax may occur as a complication of surgery, birth trauma or pulmonary lymphatic abnormalities. Regardless of the underlying mechanism, chylothorax causes respiratory, nutritional, and immunological complications (1, 2). Congenital idiopathic chylothorax is the most common form of pleural effusion in neonates (3).

Conservative therapy is the mainstay of treatment and includes chest drainage, restriction of gastric feeding to medium chain triglycerides and administration of parenteral nutrition. An alternative therapy is Octreotide which is a long-acting somatostatin analog. Octreotide has been used in the treatment of postoperative or spontaneous chylothorax in infants and older children (4, 5). It has also been used for the treatment of congenital chylothorax in term neonates (6, 7). However, the experience of octreotide use in premature babies with congenital chylothorax is limited (5, 8). We herein present a case of idiopathic unilateral chylothorax who was

treated successfully with conservative therapy, octreotide and regimen therapy.

2- CASE REPORT

A male neonate was delivered at 39 weeks of gestation by normal vaginal delivery. Mother was 22-year-old, with one abortion at previous pregnancy. His birth weight was 3,700 gr. He has respiratory distress since birth and was intubated and mechanically ventilated. Surfactant was given and he was maintained on mechanical ventilation for 3 days. A chest X- ray revealed opacity of right lung with heart and mediastinum shifted to the left (**Figure.1**). He was referred to Shahid Motahari hospital of Urmia, Iran, and admitted to neonatal intensive care unit. Ultra sound of the chest revealed moderate to severe pleural effusion in the right pleural space and collapse of the right lung. Echocardiography was normal but confirmed pleural effusion in the right pleural space. On day 11, thoracostomy tube was placed on the right pleural space (**Figure.2**), and a clear appearing fluid was drained. The fluid was sterile and the results of fluid analysis are summarized in **Table.1**.

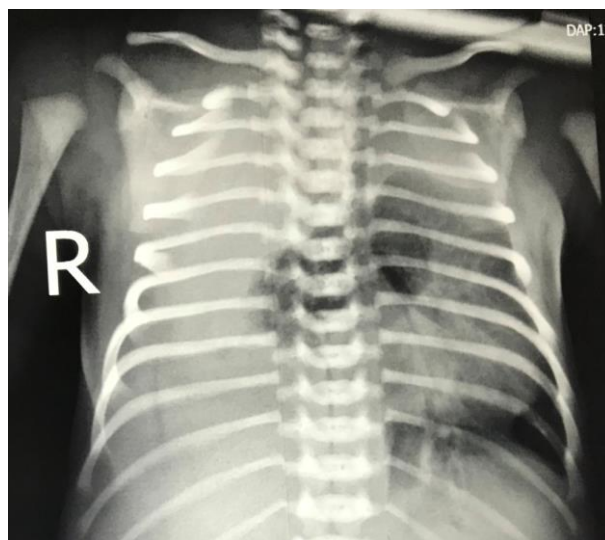


Fig.1: Chest X- ray showing massive right sided pleural effusion, and shift of heart to the left.

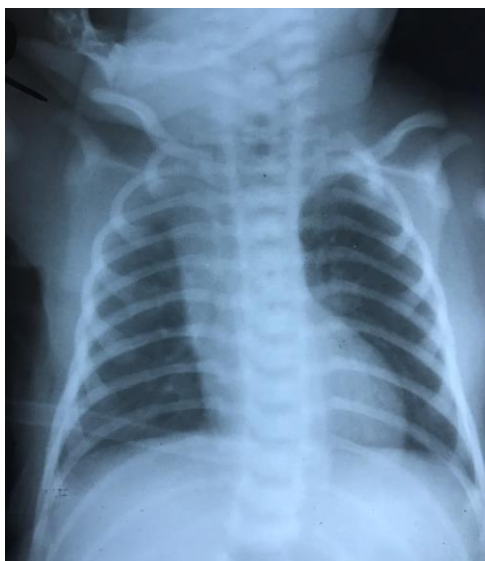

Fig.2: Chest X-ray showing thoracostomy tube and resolution of pleural effusion.

Table-1: Cell analysis and biochemistry of the first pleural tap

Parameter	Unit
Total cells	3540/mm ³
WBC	1500/mm ³
Lymphocyte	90%
Segmented	10%
RBC	2040/mm ³
Lactate Dehydrogenase	265 IU/L
Glucose	94 mg/dl
Protein	2.5 gr/dl
Triglyceride	56 mg/dl
Cholesterol	31 mg/dl

WBC: White blood cell; RBC: Red blood cell.

On day 14 thoracostomy tube was removed because the amount of pleural effusion gradually decreased and resolved and follow up chest X-ray revealed no pleural effusion. On day 15 feeding was started with breast milk. The next day feeding was discontinued because of

deterioration of respiratory status. A follow up chest X- ray revealed reaccumulation of fluid in right pleural space. Thoracostomy tube was reinserted. The fluid was milky-yellow and turbid. The results of fluid analysis are summarized in **Table.2**.

Table-2: Cell analysis and biochemistry of the second pleural tap

Parameter	Unit
Total cells	18000/mm ³
White blood cell	14000/mm ³
Lymphocyte	98%
segmented	2%
Red blood cell	4000/mm ³
Lactate Dehydrogenase	730 IU/L
Glucose	116 mg/dl
Protein	317 gr/dl
Triglyceride	1451 mg/dl
Cholesterol	35 mg/dl

Feeding was discontinued and total parenteral nutrition was started. Intravenous infusion of octreotide, 2 µg/kg/hour was started and gradually increased to 3.5 µg/kg/hour. After 2 weeks of NPO, on day 30 feeding started with Formula Monogen (made by Nutritia Company, Netherlands), which is low in long chain triglycerides (LCT), and high in medium chain triglycerides (MCT). Formula was continued and octreotide was tapered and discontinued after 7 days. There was no drainage from thoracostomy tube, so it was removed. The infant continued to do well, without recurrence of pleural effusion and was discharged home on day 38. The child was followed and ordinary formula started on day 46 and monogen tapered gradually after one month. He was good at 3 months of age.

3- DISCUSSION

Chylothorax or chylous pleural effusion refers to presence of Chyle (lymphatic fluid) in the pleural space. Chyle is a milky fluid characterized by T-lymphocyte predominance (90%), high triglyceride levels (>110 mg/dl), protein content equal to that of plasma and total cell count more than 1000 cells/mm³ (9). In neonates, chylothorax occurs in situations such as cardiothoracic surgery, birth trauma, and great vessel thrombosis, causing damage to the thoracic duct (2). It also occurs in dysmorphic syndromes, such as Turner or Noonan syndrome. However, in many situations, the etiology of the chylothorax is uncertain and is believed to be caused by abnormality of thoracic or pulmonary lymphatic system (1). This is termed idiopathic congenital chylothorax (1). Iatrogenic trauma of thoracic duct, most commonly caused by thoracic or heart surgery or even minimally invasive procedures to the chest or neck such as insertion of central catheters are the main causes of thoracic duct disruption and resultant chylothorax in neonatal population. In very rare situations blunt

trauma to the neck or chest during delivery or neonatal procedures causes disruption of thoracic duct. Chylothorax is certainly suspected when milky fluid is aspirated from pleural space. Although chylothorax traditionally is diagnosed by aspiration of milky-yellow fluid aspiration of pleural space, in some situations such as before starting feeding in newborns it may be non-milky and clear (9). In our case, at first the pleural fluid was clear, but after initiation of feeding it became milky-yellow and its analysis confirmed typical characteristics of chyle. The strategy of treating chylothorax is the same regardless of the etiology of chylothorax. The first step is aspiration of the pleural fluid for initial drainage and diagnostic purpose. However, continuous drainage of the chyle with a chest tube is indicated if the effusion causes respiratory distress or the accumulation of effusion recurs (4).

Nutritional support in the management of chylothorax is aimed at providing adequate caloric intake while minimizing the chyle flow in the thoracic duct while waiting for spontaneous healing of the leakage site. This is usually achieved by feeding with a formula high in medium chain triglycerides (MCT), which bypasses the intestinal lymphatic system and is absorbed directly to the portal vein. Then, a trial of feeding with MCT-enriched formula can be given with close monitoring of re-accumulation of pleural effusion, either by chest tube drainage or ultrasound (10). In our case, chest tube was removed three days after insertion, because drainage was stopped and we did not think that it was chylothorax because of its clear appearance. When the chylothorax re-accumulated after initiating feeding and the patient had significant respiratory distress, we put the thoracostomy tube in again. This time the fluid had a milky-yellow appearance. So, we decided to discontinue feeding and start octreotide. The experience with

somatostatin and octreotide in the management of pediatric chylothorax is still quite limited. Only a small number of case reports exist, and no consensus has been reached as to the optimal route of administration, dose and efficacy, duration of therapy or strategy for discontinuation of therapy (4, 5, 11). Somatostatin is a polypeptide secreted from the paraventricular nucleus of the hypothalamus. It has an inhibitory effect on the secretion of growth hormone, glucagon, and insulin. Octreotide, a synthetic somatostatin analog, is more potent in inhibiting endocrine system and has a much longer half-life. In gastrointestinal tract, somatostatin and octreotide act on somatostatin receptors to reduce intestinal blood flow by vasoconstriction of the splanchnic vessels, decrease gastrointestinal motility and inhibit gastric, pancreatic, and biliary secretions, thus reducing intestinal fat absorption and lymphatic flow in the thoracic duct. Octreotide has been used in the treatment of postoperative or spontaneous chylothorax in infants and older children (4, 5, 10). It has also been used for the treatment of congenital chylothorax in term neonates (6, 7). Use of somatostatin was first reported in 1990 in an adult and in 2003 in a neonate (5, 6).

Based on Das and Shah's experience, they recommend intravenous infusion of octreotide 3 µg/kg per hour as a safe and effective treatment for traumatic chylothorax in a newborn (12). The duration of therapy is determined by the reduction in volume of pleural drainage, where improvement was defined as drainage of <10 ml/kg per day and failure as drainage >10 ml/kg per day after 4 weeks of medical treatment. Octreotide was usually weaned over a period of two to four days, while the patient was monitored for re-accumulation of the effusion (5). Octreotide is generally considered to be safe, with only occasional

side effects. The side effects of octreotide are mainly related to its vasoconstrictive and antisecretory actions. The reported adverse reactions include cramps, flatulence, nausea, diarrhea, necrotizing enterocolitis, hyperglycemia, transient hypothyroidism, and liver dysfunction (10). No aforementioned side effects of octreotide were observed in our patient. It seems that prospective registry of chylothorax patients and subsequent multicentered randomized controlled trials are needed to assess the safety, efficacy and optimal dose of octreotide in the treatment of chylothorax in neonates (10). Although octreotide, a somatostatin analogue, is widely used as a therapeutic option in neonates with congenital and acquired chylothorax, its therapeutic role has not been clarified yet and merits further investigation (13).

4- CONCLUSION

Chylothorax may be suspected in patients with pleural effusions. Pleural fluid triglyceride measurement remains the recommended diagnostic method in chylothorax. Values more than 110 mg/dl demonstrate the diagnosis. Milky or yellow appearance of pleural fluid with lymphocyte predominance confirms the diagnosis. Chest or neck trauma may cause chylothorax, although it may be idiopathic. Standard management of neonatal chylothorax usually entails prolonged hospitalization and frequently requires surgical intervention. Administration of octreotide in our case led to a more rapid resolution of pleural drainage, no recurrence, and early hospital discharge. Octreotide immediately diminished chyle production, without observed adverse effects.

5- CONFLICT OF INTEREST: None.

6- REFERENCES

1. Dubin PJ, King IN, Gallagher PG. Congenital chylothorax. *Curr Opin Pediatr* 2000; 12: 505e9.
2. Wasmuth-Pietzuch A, Hansmann M, Bartmann P, Heep A. Congenital chylothorax: lymphopenia and high risk of neonatal infections. *Acta Paediatr* 2004; 93: 220e4.
3. Abdelakarim I, Dammas AS. Congenital neonatal chylothorax with hydrops fetalis treated with octreotide. *Sudanese J Pediatrics*, 2013; 1(13):43-8.
4. Soto-Martinez M, Massie J. Chylothorax: diagnosis and management in children. *Paediatr Respir Rev* 2009; 10: 199e207.
5. Roehr CC, Jung A, Proquitté H, Blankenstein O, Hammer H, Lakhoo K, R. Somatostatin or octreotide as treatment options for chylothorax in young children: a systematic review. *Intensive Care Med* 2006; 32: 650e7.
6. Bulbul A, Okan F, Nuhoglu A. Idiopathic congenital chylothorax presented with severe hydrops and treated with octreotide in term newborn. *J Matern Fetal Neonatal Med* 2009; 22:1197e200.
7. Young S, Dagleish S, Eccleston A, Akierman A, McMillan D. Severe congenital chylothorax treated with octreotide. *J Perinatol* 2004; 24: 200e2.
8. Altuncu E, Akman I, Kiyani G, et al. Report of three cases: congenital chylothorax and treatment modalities. *Turk J Pediatr* 2007; 49: 418e21.
9. Skouras V, Kalomenidis L. Chylothorax: diagnostic approach, Wolters Kluwer Health, Lippincott Williams & Wilkins, 2010; 16: 387-93.
10. Foo NH, Hwang YS, Lin CC, Tsai WH. Congenital chylothorax in a late preterm infant and successful treatment with octreotide. *J Pediatrics and Neonatology*, 2011; 52: 297-301.
11. Beghetti M, La Scala G, Belli D, Bugmann P, Kalangos A, LeCoultré C. Etiology and management of pediatric chylothorax. *J Pediatr* 2000; 136:653e8.
12. Das A, Shah PS. Octreotide for treatment of chylothorax in neonates. *Cochrane database system rev* 2010; Issue 9. Art. No.
13. Bellini C, Cabano R, De Angelis LC, Bellini T, Calevo MG, Gandullia P, Ramenghi LA. Octreotide for congenital and acquired chylothorax in newborns: A systematic review. *J Paediatr Child Health*. 2018; 54(8):840-47.