



A Rare Case Report of Duplicate Vents in a Broiler Breeder Hen (Case Report)

Madadi MS¹, Karimi H² & Azari M³

¹Department of Clinical Sciences, Faculty of Veterinary Medicine, University of Tabriz, Tabriz, Iran.

²Department of Basic Sciences, Faculty of Veterinary Medicine, University of Tabriz, Tabriz, Iran.

³Department of Clinical Sciences, Faculty of Veterinary Medicine, University of Shiraz, Shiraz, Iran.

Poultry Science Journal 2014, 2 (2): 195-199

Article history:

Received: July 18, 2014

Revised: September 1, 2014

Accepted: September 14, 2014

Corresponding author:

Hamid Karimi, DVM, DVSc.
Karimi@tabrizu.ac.ir

Keywords:

Case report

Vent duplicate

Broiler breeder

Congenital malformation

Abstract

Malformations which occur during the development of the avian body organs can lead to structural and functional abnormalities. Most defects are recognized at hatching, but some go undetected until somewhat later. The cause of the majority of animal congenital malformations is unknown. A significant proportion of congenital malformations of unknown cause are likely to have an important genetic component. Malformations of the gastrointestinal and urogenital systems have been observed. This report describes a rare case of duplicate vents in a broiler breeder 33 week-old hen. A normal calcified egg was present in the left oviduct and right oviduct was atrophied. Both cloaca were anatomically normal, and each of them had a complete structure of coprodeum, urodeum and proctodeum. Double vents' anomalies in breeder hens were only reported by Crew and Roberts in 1928 - 1929 and have not been reported after this time yet.

Please cite this article as: Madadi MS, Karimi H & Azari M. 2014. A rare case report of duplicate vents in a broiler breeder hen (Case Report). *Poult. Sci. J. 2 (2): 195-199.*

© 2014 PSJ. All Rights Reserved

Introduction

Congenital malformations which occur during the development of the avian body organs can lead to structural and functional abnormalities. These malformations occur during the pre-hatching period as well as during the post hatching period. Most defects are recognized at hatching, but some go undetected until somewhat later. The causes of congenital malformations can be divided into three categories: unknown, genetic and environmental. The cause of the majority of animal congenital malformations is unknown. A significant proportion of congenital malformations of unknown cause are likely to have an important genetic component. Malformations of the gastrointestinal as well as the urogenital systems have been observed.

A few abnormalities in the urogenital system have been described like: right kidney aplasia and hypoplasia, aplasia of the right kidney and ureter (Grewal *et al.*, 1976), persistent right oviduct (Morgan and Kohlmeier, 1957). Furthermore, embryonic and day-old chickens conjoined duplications were recorded (Pourlis, 2011). Ghazi and Dadras (1994) observed a day-old broiler chicken with duplication of ileum, caecum, rectum and cloaca. To our knowledge, double vents anomaly in breeder hens has only been reported by Crew and Roberts in 1928 - 1929 (Pourlis, 2011). This paper reports double vent anomaly in a broiler breeder hen.

In the present report, a double vent anomaly was observed in a broiler breeder hen of Cobb 500 strain.

Materials and Methods

33000 broiler breeders (Cobb 500 strain) were reared in a local farm during March 2012 - February 2013. An unusual hen with duplicate vents was noticed at 33 weeks of age. Clinical and post mortems examination were performed on the bird.

Results and Discussion

The hen with duplicate vents is shown in Figure 1. Clinical examination revealed no signs of any diseases or disorders in the bird, and it was alive and laying eggs normally. Observation of two vents was the principle cause of notice.

Routine post mortem examination showed that the beak, tongue, esophagus, crop, gizzard, proventriculus and small intestines were all in the normal anatomical position. One functional ovary and oviduct approximately 25 cm in length opening into the left cloaca were present in the left side of the abdominal cavity. A normal egg with calcified shell was observed in the left oviduct (Figure 2). The end part of the left oviduct was opening into the left cloacae, and it seems more that only the left vent was capable of accommodating oviposition. There was an atrophy of the right gonad and the right oviduct.

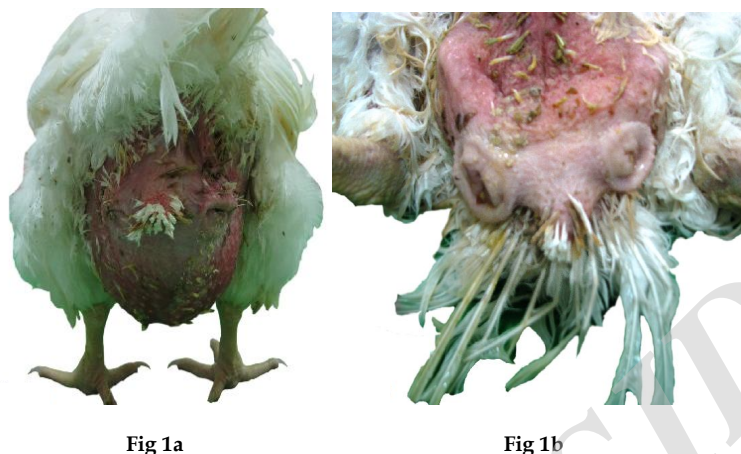


Fig 1a

Fig 1b

Figure 1. External view of double vents, before (a) and after (b) bird euthanasiation.

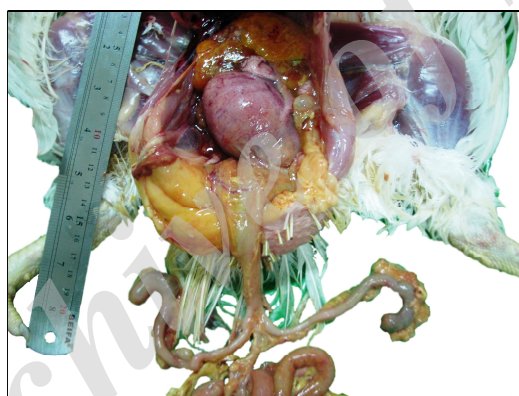

Figure 2. Calcified shell egg present in the left oviduct

Two normal ureters were present. The left ureter was opening in the dorsal wall of the left vent urodeum and the right ureter was opening to the right vent, respectively.

The end part of the digestive tract was duplicated and forming two cloacae. Both cloaca were anatomically normal, and each of them had a complete structure of coprodeum, urodeum and proctodeum. A normal structure of separating folds (uroproctodeal and coprourodeal folds) was observed in the every cloaca.

The two vents, both of which excreting fecal material, were of a normal size, symmetrically placed inferior to the tail, and were normal in the anatomical structure. The vents had two lateral commissure and two dorsal and ventral lips. A

median raphe was observed between the two vents. The length of the right and left vents were 2.4 and 2.1 cm, respectively. The distance between the internal commissure of the two vent lips was 3.0 cm (Table 1).

Table 1. Anatomical characteristics of two vents

	Region	Length
1	Right vent length	2.4 cm
2	Left vent length	2.1 cm
3	Distance between two internal commissures of two vents	3.0 cm
4	Distance of right commissure from median raphe	1.4 cm
5	Distance of left commissure from median raphe	1.6 cm

The caudal portion of the bird embryonic hindgut is called cloaca (Sadler, 1990). Cloacal membrane is divided into two membranes by urorectal septum, anterior urogenital membrane and posterior anal membrane. In the birds, cloaca is not divided and remains as an undeveloped condition and serves as a common terminus for the urinary, digestive and genital system (Noden and Lahunta, 1985; Sadler, 1990).

Some of the embryonic organ duplications arise after gastrulation period when specific organ-forming regions called fields (limb field, heart field, eye field, etc.) are becoming organized (Noden and Lahunta, 1985).

It is possible to hypothesize that vent and cloaca duplication in the present bird has been probably induced by two reasons: first, similar to mammals, forming of the urorectal septum and separation of the two parts of the cloaca. This hypothesis is poorly approved, because in this case, each of the left and right ureter entered the left and right vent, separately. Another reason is that in the developing process, the cloaca field as the heart field, mesenchymal tissue produces one or two septum. These two septum generated one or two cloaca completely with an unknown reason.

Ghazi and Dadras (1994) reported duplication of the limb, ileum, caeca, rectum and cloaca in a day-old broiler chick. They believed that no single specific reason for these abnormalities can be assigned. However, in this case and the present bird, a single teratogenic factor might have caused them by impairing the gene function on relevant chromosomes.

Acknowledgments

The authors would like to thank Babapour and Khaseban Broiler Breeder Company for funding this case report project.

References

Ghazi SR & Dadras H. 1994. Duplication of limbs, ileum, caeca, rectum and cloaca in a day-old broiler chick. *Journal of Anatomy*, 185: 453.

- Grewal GS, Singh B & Sahota PS, 1976. Congenital anomalies of domestic fowl: seven cases. *Avian Disease*, 20: 581-586.
- Noden DM & Lahunta AD. 1985. *The Embryology of Domestic Animals: Developmental Mechanisms and Malformations*. 1st Ed. Williams and Wilkins. Baltimore. 376 Pages.
- Pourlis AF. 2011. Developmental malformations in avian species. Manifestations of unknown or genetic etiology - A Review. *Asian Journal of Animal and Veterinary Advances*, 6: 401-415.
- Sadler T. 1990. *Langman's Medical Embryology*. 6th Ed. Williams and Wilkins. Baltimore. 411 Pages.
- Morgan W & Kohlmeyer W. 1957. Hens with bilateral oviducts. *Nature*, 180: 98.

Archive of SID

Archive of SID



گزارش موردی نادر از مخرج کلواکی دوگانه در یک مرغ مادر گوشتی

Madadi MS¹, Karimi H² & Azari M³

¹گروه علوم بالینی، دانشکده دامپزشکی، دانشگاه تبریز، تبریز، ایران.
²گروه علوم پایه، دانشکده دامپزشکی، دانشگاه تبریز، تبریز، ایران.
³گروه علوم بالینی، دانشکده دامپزشکی، دانشگاه شیراز، شیراز، ایران.

Poultry Science Journal 2014, 2 (2): 195-199

چکیده

اختلال در طی مراحل رشد و تمایز اندام‌های مختلف بدن پرندگان می‌تواند منجر به ایجاد اندام‌های غیرطبیعی از نظر ساختاری و عملکردی شود. مشخص شده است که بیشتر ضایعات ایجاد شده در اندام‌ها در هنگام هچ شدن تخم اتفاق افتاده با این وجود ممکن است یک‌سری اختلالات نیز بعد از مرحله هچری اتفاق افتد. عامل بیشتر اختلالات مادرزادی اندام‌های بدن هنوز شناخته نشده است. هر چند مشخص شده است که بیشتر اختلالات مادرزادی با عامل نامشخص، همراه با ضایعه یا اختلال ژنتیکی می‌باشند. اختلالات مادرزادی زیادی در دستگاه گوارش و ادراری تناسلی مشاهده شده است. این گزارش یک اختلال بسیار نادر مربوط به مخرج کلواکی (ونت) دوگانه در یک مرغ مادر گوشتی ۳۳ هفته را توصیف می‌کند. در این مرغ مورد مطالعه، در حین کالبدگشایی یک تخم مرغ کامل و سالم با پوسته آهکی در لوله تخم‌بر چپ مشاهده گردید و لوله تخم‌بر راست نیز تحلیل رفته بود. مرغ دارای دو کلواک با ساختاری کاملاً طبیعی از نظر ساختاری بود و نواحی کوپرودیوم، یورویدیوم و پروکتودیوم در هر دو کلواک قابل تشخیص بودند. اختلال مخرج کلواکی (ونت) دوگانه در مرغ‌های مادر فقط یک بار در سال ۱۹۲۸-۱۹۲۹ توسط کریو و روبرت گزارش شده است و بعد از آن زمان تا حال هیچ گزارشی در این مورد مشاهده نشده است.

تاریخچه مقاله:

دریافت: ۱۸ جولای، ۲۰۱۴
ویرایش: ۱ سپتامبر ۲۰۱۴
پذیرش: ۱۴ سپتامبر، ۲۰۱۴

نویسنده مسئول:

Hamid Karimi, DVM, DVSc.
Karimi@tabrizu.ac.ir

کلمات کلیدی:

گزارش موردی
مخرج کلواک دوگانه
مرغ مادر گوشتی
اختلالات مادرزادی

Please cite this article as: Madadi MS, Karimi H & Azari M. 2014. A rare case report of duplicate vents in a broiler breeder hen (Case Report). *Poult. Sci. J.* 2 (2): 195-199.

© 2014 PSJ. All Rights Reserved