



## Iodixanol as a Gastrointestinal Contrast Media in the New Zealand White Rabbit

Mehrdad Yadegari<sup>1\*</sup>, Seyedeh Zeinab Peighambarzadeh<sup>2</sup>

<sup>1</sup> Medical Plants Research Center, Shahrekord Branch, Islamic Azad University, Shahrekord, Iran.

<sup>2</sup> Veterinary Department, Faculty of Agriculture, Shoushtar branch, Islamic Azad University. Khuzestan, Iran.

### ABSTRACT

Determination of normal gastric emptying time and small intestinal transit time are useful in detecting gastrointestinal motility disorders and partial obstructions of the pylorus or small intestine. This study was conducted to evaluate iodixanol as a contrast agent in the gastrointestinal tract in New Zealand White rabbit. Twelve clinically healthy adult rabbits were prepared and kept for two weeks prior to study. Blood tests were performed 10 days prior to the study. After eighteen hour fasting, plain lateral and ventrodorsal radiographs were obtained. One thousand mg iodine per kilogram body weight of iodixanol was administered orally to the rabbits. Lateral and ventrodorsal radiographs were taken at zero, 10, 20 and 30 minutes after administration of contrast media and then in 30 minutes intervals until eight hours after swallowing, and then at nine, 10, 12 and 24 hours. Blood tests were performed 5 days after the study. Contrast medium was noted in the small intestine immediately after administration in two of the twelve (16.66%) rabbits. Early gastric emptying time was started at  $8.17 \pm 5.45$  minutes. Delay gastric emptying time was started at  $317.50 \pm 36.93$  minutes. Early small intestine transit time was started at  $59.00 \pm 15.54$  minutes. Delay small intestine transit time was started at  $476.00 \pm 37.14$  minutes. Because of coprophagia there was some evidence of contrast media in stomach in twenty fourth hour radiographs. It is concluded that this iodixanol gave a diagnostic opacification of upper gastrointestinal tract in rabbit.

**Key words:** Iodixanol, Gastrointestinal, Contrast, Rabbit

### INTRODUCTION

Rabbits are small mammals in the family *Leporidae* of the order *Lagomorpha*. Rabbit is a mammal which is kept as a pet in Iran and therefore the numbers of referred cases to the clinics have been increased. Radiography is a noninvasive medical test that helps physicians diagnose and treat medical conditions. Radiography is used for diagnosis of abdominal disorders in animals as well as rabbit. Plain radiographs show little or no detail of the outlines of internal organs, and the gastrointestinal tract is visible only if marked by gas or radiopaque foreign bodies (Kealy et al., 2011). Gastrointestinal contrast study is divided into two type: upper gastrointestinal study (UGI study), barium swallow, that is a radiographic contrast study evaluating the esophagus, stomach and small intestine and lower gastrointestinal study (LGI study) commonly refer to as a barium enema, a radiographic contrast study evaluating rectum, colon and cecum

(Lavin, 2002). Because barium is not absorbed into the blood, allergic reactions are extremely rare. Some patients are given other forms of orally ingested contrast, usually containing iodine. These alternative contrast materials may be used if the patient has recently undergone surgery on the GI tract, or has allergies to other contrast materials. Upper gastrointestinal study can provide both morphologic and functional information, through evaluation of emptying and transit times (Smith et al., 2001). Upper gastrointestinal study may be done with positive, negative or a combination of positive and negative agents. Iodixanol is a contrast agent, sold under the trade name Visipaque. Visipaque is commonly used as a contrast agent during coronary angiography. It is the only iso-osmolar contrast agent, with an osmolality of 290 mOsm/kg H<sub>2</sub>O, the same as blood. The aim of this study was to describe the normal radiographic anatomy of the gastrointestinal tract of the rabbit and the transient time through the gastrointestinal tract in this animal.

## MATERIALS AND MTHODS

Twelve clinically healthy adult rabbits, with no evidence of digestive system disorder, seven male and five female, weighting between 1100 -1300 grams, were prepared from animal selling center and kept for two weeks prior to study. Blood tests were performed 10 days prior to the study and no abnormality in hematological and biochemical factors was detected. Before administration of contrast media the rabbits were fasted for 18 hours, and 20 mg per kilogram body weight dimethicone was given orally 2 hours before starting the procedure. Plain lateral (L) and ventrodorsal (VD) radiographs were taken prior to contrast study with focus-film distance (FFD) of 100 cm and Kilovolt peak (kVP) of 45-47, Milliampere per seconds (mAs) of 2.0, using a portable Sedcal X- Ray machine. The radiographs were developed in a 120 second automatic processor. One thousand mg iodine per kilogram body weight of iodixanol was administered orally. Lateral and VD radiographs were taken at zero, 10, 20 and 30 minutes after administration of contrast media and then Lateral and VD radiographs were taken every 30 minutes until eight hours after swallowing, and then at nine, 10, 12 and 24 hours. All animals were kept for one week after experiment to note any abnormality in animals. Blood tests were performed 5 days after the study. The early gastric emptying time (EGET) was defined as the time after administration of contrast media to its appearance in the duodenum. The delay gastric emptying time (DGET) was defined as the time from administration of contrast media until the final emptying of contrast media from stomach. The early small intestinal transit time (ESITT) was defined as the time after administration of contrast media to its appearance in the cecum. The delay small intestinal transit time (DSITT) was defined as the time from administration of contrast media until the final emptying of contrast media from small intestine.

## RESULTS

There were no abnormal clinical signs after one week of experiments. There were no abnormal blood biochemical and hematological changes. No reflux of iodixanol was noted. No evidence of contrast medium aspiration was observed. Dosage of One thousand mg iodine per kilogram body weight of iodixanol gave a good opacification of upper gastrointestinal tract in rabbit. The stomach lies in the cranial part of abdomen. Stomach was seen approximately at the level of ninth to thirteenth ribs in L views (Fig. 1). The stomach is somewhat J shaped in VD views (Fig. 2). The cardia, fundus, and body are lie left of the midline and the pyloric antrum and pyloric canal lie to the right side (Fig. 2). No evidence of gastric over distension was observed. Contrast medium was noted in the small intestine immediately after administration in two of the twelve (16.66%) rabbits. In L and VD views early gastric emptying time (EGET) was started at  $8.17 \pm 5.45$  minutes (Table 1). In L and VD views delay gastric emptying time

(DGET) was started at  $317.50 \pm 36.93$  minutes (Table 1). In all rabbits after DGET, the gastric mucosal surface had a smooth, uniform texture and with well-defined margin. In L and VD views early small intestinal transit time (ESITT) was started at  $59.00 \pm 15.54$  minutes (Table 1). In L and VD views delay small intestinal transit time (DSITT) was started at  $476.00 \pm 37.14$  minutes (Table 1). There was some contrast media in stomach in twenty forth hour radiographs.

## DISCOSSION

Radiography is used to diagnose abnormalities like other species in rabbit. Plain radiographs show little or no detail of the outlines of internal organs, and the gastrointestinal tract is visible only if marked by gas or radiopaque foreign bodies. Gastrointestinal tract can be investigated by mean of contrast radiography (Meyer, 2008), fluoroscopy (Wrey et al., 2006), ultrasonography (Boysen et al., 2003, Shorvon et al., 1987), nuclear medicine (Balogh et al. 1999, Heyman 1998), computed tomography (Kim et al., 2004, Megibow et al., 1982) and magnetic resonance imaging (Kuriashkin et al. 2000) in animals and human. The contrast media always allowed a good functional evaluation of the gastrointestinal tract (Bello et al., 2006). Contrsat media are used to identify any abnormalities such as tumors, ulcers, hernias, pouches, strictures, and swallowing difficulties (Long et al., 2010) and verified the absence of stenosis or other morphologic alterations of enterotomized bowel. Gastric emptying time was complete 270 to 300 minutes after swallowing of the iodixanol. Small intestine had a much coiled appearance. Individual parts of the small intestine were not distinguishable.

The dosage of iodixanol used in this study allowed good visualization of all parts of the rabbit gastro intestinal tract. One thousand mg iodine per kilogram body weight of iodixanol is adequate for appropriate distension of the stomach and subsequent visualization of the gastrointestinal tract. There were no such complications during procedures and no illnesses were seen up to two weeks afterward in this study.

## REFERENCES

- Balogh, L., Andócs, G., Thuróczy, J., Németh, T., Láng, J., Bodó, K. and. Jánoki, G. A (1999). Veterinary nuclear medicine. Scintigraphical examinations – A review. *Acta Veterinaria Brno*, 68: 231–239.
- Di Bello, A., Valastro, C., Staffieri, F., and Crovace, A (2006). Contrast Radiography of the gastrointestinal tract in sea turtles. *Veterinary Radiology & Ultrasound*, 47(4): 351–354.
- Heyman, S (1998). Gastric Emptying in Children. *Journal of Nuclear Medicine*, 39: 865-869.
- Kealy, J.K., McAllister, H., and Graham, J.P (2011). *Diagnostic Radiology and Ultrasonography of the Dog and Cat*. 5<sup>th</sup> edition, WB Saunders, Philadelphia, pp: 80-97.
- Kim, S.H., Han, J.K., Lee, K.H., Yoon, C.J., Kim, Y.I., Lee, H.S., and Chol, B.I (2004). Experimentally Induced Small-Bowel Tumor in Rabbits: US-guided Percutaneous 18-gauge Core Biopsy. *Journal of Radiology*, 231:150–155.
- Kuriashkin, I.V., and Losonsky, J.M (2000). Contrast enhancement in magnetic resonance imaging using intravenous paramagnetic contrast media: a review. *Veterinary Radiology & Ultrasound*. 41(1):4-7.

Lavin, L.M (2002). Radiography in Veterinary Technology. 3th edition, WB Saunders, Philadelphia, pp: 265-290.

Long, C.T., Page, R.B., Howard, A.M., McKeon, P., and Felt, S.A (2010). Comparison of Gastrografin to barium sulfate as a gastrointestinal contrast agent in red-eared slider turtles. *Veterinary Radiology & Ultrasound*. 51(1): 42-47.

Megibow, A.J., Balthazar, E.J., Naidich, D.P., and Bosniak, M.A (1983). Computed Tomography of Gastrointestinal Lymphoma. *American Journal of Roentgenology*. 141(3): 541-547.

Meyer, J (1998). Gastrografin as a gastrointestinal contrast agent in the Greek tortoise. *Journal of Zoo and Wildlife Medicine*. 29(2): 183-189.

Shorvon, P. J., Lees, W.R., Frost, R. A., and Cotton, P. B (1987). Upper gastrointestinal endoscopic ultrasonography in gastroenterology. *British Journal of Radiology*. 60(713): 429-438.

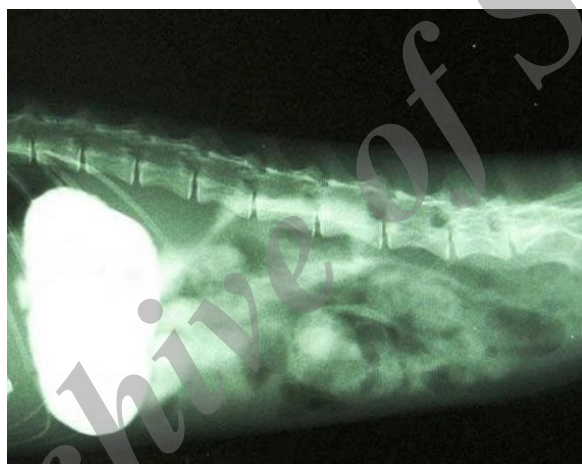
Smith, D., Dobson, H., and Spence, E (2001). Gastrointestinal studies in the green iguana: Technique and Reference values. *Veterinary Radiology & Ultrasound*. 42(6): 515-520.

Wray, J.D., and Blunden, A.S (2006). Progressive dysphagia in a dog caused by a scirrhous, poorly differentiated periesophageal carcinoma. *Journal of Small Animal Practice*. 47(1):27-30.

Archive of SID

Table 1: Gastrointestinal Transit Times after administration of contrast media

| Phase | Mean<br>min. | SD<br>min. | Minimum<br>min. | Maximum<br>min. |
|-------|--------------|------------|-----------------|-----------------|
| EGET  | 8.17         | 5.45       | 0.00            | 15.00           |
| DGET  | 317.50       | 36.93      | 240.00          | 390.00          |
| ESITT | 59.00        | 15.54      | 30.00           | 90.00           |
| DSITT | 476.00       | 37.14      | 420.00          | 540.00          |

**Figure 1:** Lateral view radiograph after iodixanol swallow**Figure 2:** Ventrodorsal view radiograph after iodixanol swallow