



# The Frequency and Tissue Distribution of *Ornithobacterium rhinotracheale* in different Organs of Turkeys

## ARTICLE INFO

**Article Type**  
Original Research

### Authors

Maryam Karimi-Dehkordi, *PhD*<sup>1</sup>  
Hamid Hashemi, *DVM*<sup>2</sup>  
Maziar Haj Salehi, *DVM*<sup>2</sup>  
Majid Gholami-Ahangaran, *PhD*<sup>1\*</sup>  
Asiye Ahmadi-Dastgerdi, *PhD*<sup>3</sup>

### How to cite this article

Karimi-Dehkordi M., Hashemi H., Haj Salehi M., Gholami-Ahangaran M., Ahmadi-Dastgerdi A. The Frequency and Tissue Distribution of *Ornithobacterium rhinotracheale* in different Organs of Turkeys. Infection Epidemiology and Microbiology. 2021;7(1): 45-51

<sup>1</sup>Department of clinical Sciences, Faculty of Veterinary Medicine, Shahrekord Branch, Islamic Azad University, Shahrekord, Iran

<sup>2</sup> Faculty of Veterinary Medicine, Shahrekord Branch, Islamic Azad University, Shahrekord, Iran

<sup>3</sup>Department of Food Science and Technology, Ardestan Branch, Islamic Azad University, Ardestan, Iran

### \* Correspondence

Address: Department of clinical Sciences, Faculty of Veterinary Medicine, Shahrekord Branch, Islamic Azad University, Shahrekord, Iran.  
Mgholami6@gmail.com

### Article History

Received: November 05 ,2020  
Accepted: December 25 ,2020  
Published: January 23 ,2021

## ABSTRACT

**Background:** This study was designed to investigate the frequency and tissue distribution of *Ornithobacterium rhinotracheale* (ORT) in turkeys with respiratory syndrome in Isfahan province.

**Materials & Methods:** Totally, samples were taken from the trachea, lung, air sac, infraorbital sinus, hock joint, blood of heart, brain, liver, spleen, intestine, and kidney of 30 turkey flocks. After DNA extraction, a 787 bp fragment of 16S rRNA gene of ORT was amplified.

**Findings:** The PCR results revealed that 53% of turkeys were infected by ORT. The results showed that although ORT was mainly found in the respiratory tract, it could be systemic and infect some other organs, including the joints, brain, liver, spleen, and blood of heart, but could not infect the intestines and kidneys.

**Conclusion:** Due to the lack of a clear pattern in tissue distribution of ORT among clinical samples, it seems that other factors play a role in ORT tissue distribution, such as dose, route, type of infection, and probably prevalent serotype.

**Keywords:** *Ornithobacterium rhinotracheale* (ORT), Tissue distribution, Isfahan, Turkey, Respiratory syndrome.

## CITATION LINKS

- [1] Vandamme P, Segers P, Vancanneyt M, van Hove K, Mutters R, Hommez J, et al. *Ornithobacterium rhinotracheale* gen. nov., sp. nov., isolated from the avian respiratory tract. *Int J Syst Bacteriol...* [2] Tahseen A. *Ornithobacterium rhinotracheale* developing into a serious infection. *World Poult Misset...* [3] Kurska O, Tomczyk G, Sawicka-Durkalec A, Giza A, Słomiany-Szwarc M. Bacterial communities of the upper respiratory tract of turkeys. *Sci Rep...* [4] Van Empel P, Hafez H. *Ornithobacterium rhinotracheale*: A review. *Avian Pathol...* [5] van Empel P, Vrijenhoek M, Goovaerts D, van den Bosch H. Immunohistochemical and serological investigation of experimental *Ornithobacterium rhinotracheale* infection in chickens. *Avian Pathol...* [6] Chin RP, Droual R. *Ornithobacterium rhinotracheale* infection. In: Calnek BW, editor. *Diseases of poultry*. 10th ed. Iowa State University Press, Ames, IA... [7] van Veen L, van Empel CP, Fabria T. *Ornithobacterium rhinotracheale*, a primary pathogen in broilers. *Avian Dis...* [8] Suzuki K, Petrucci M, Trenchi G, Giozza G, Rodríguez G, Trenchi H. Flock-level seroprevalence against *Ornithobacterium rhinotracheale* among broilers in Uruguay. *Int J Poult Sci...* [9] Allymeh M. Seroprevalence of *Ornithobacterium rhinotracheale* infection in broiler and broiler breeder chickens in West Azerbaijan Province, Iran. *J Vet Med A Physiol Pathol Clin Med...* [10] Asadpour Y, Bozorgmehrfard MH, Pourbakhsh SA, Banani M, Charkhkar S. Isolation and identification of *Ornithobacterium rhinotracheale* in broiler breeder flocks of Guilan province, north of Iran. *Pak J Biol Sci...* [11] Ghanbarpour R, Salehi M. Sero-prevalence and identification of *Ornithobacterium rhinotracheale* in broiler flocks in south-eastern Iran. *Trop Anim Health Prod...* [12] Doosti A, Sharifzadeh A, Ghasemi H, Vaez J. Molecular identification of *Ornithobacterium rhinotracheale* in turkeys in Isfahan province of Iran. *Afr J Biotechnol...* [13] Ozbey G, Ongor H, Turgut-Balik D, Celik V, Kilic A, Muz A. Investigations on *Ornithobacterium rhinotracheale* in broiler flocks in Elazig province located in the East of Turkey. *Vet Med...* [14] Roepke DC, Back A, Shaw DP, Nagaraja KV, Sprenger SJ, Halvorson DA. Isolation and identification of *Ornithobacterium rhinotracheale* from commercial turkey flocks in the upper Midwest. *Avian Dis...* [15] Asadi J, Gholami-Ahangaran M, Momtaz H. Molecular detection of *Ornithobacterium rhinotracheale* in quails of Isfahan province. *Iran Clinical Pathol...* [16] Shabani A, Gholami-Ahangaran M, Momtaz H. Molecular detection of *Ornithobacterium rhinotracheale* and Newcastle disease virus in ostriches of Isfahan province. *Vet Clin Pathol...* [17] Kilic A, Timurkaan N, Ertas H, Yilmaz F. Pathological examination and bacterial reisolation by culture and PCR of experimental *Ornithobacterium rhinotracheale* infection in broiler chickens. *Revue Méd Vét.* 2009... [18] Thachil A, Velayudhan B, Shaw D, Halvorson D, Nagaraja K. Pathogenesis of *Ornithobacterium rhinotracheale* in egg-laying hens with coexisting infectious bronchitis virus and *Escherichia coli* infections. *J Appl Poult Res...* [19] Zbikowski A, Szeleszczuk P, Biniek M. Tissue tropism of *Ornithobacterium rhinotracheale* in chickens determined by culture and nucleic acid detection...

## Introduction

*Ornithobacterium rhinotracheale* (ORT) is a Gram-negative, immobile, pleomorphic bacterium isolated from turkeys and chickens with respiratory problems. ORT could reduce growth and egg production and increase mortality in poultry farms. This bacterium was first named *Ornithobacterium rhinotracheale* by Vandamme et al. (1994) [1]. Due to the difficulty of ORT isolation and detection, this bacterium was not rightly described until 1994. Initially, it was called Pasteurella-like, Kingella-like, or polymorphic Gram-negative rod bacterium (PGNR), as well as TAXON 28 [2], until it was named ORT by Vandamme et al. (1994) [3]. In the genus *Ornithobacterium*, the species that causes respiratory symptoms in chickens and turkeys and joint infection in turkeys was called *rhinotracheale*.

The best ORT growth could be obtained on blood agar medium containing 5-10 % sheep blood and incubation for at least 48 hours under micro-aerobic conditions (5 to 10 % carbon dioxide) at 37 °C. Under these conditions, ORT produces small, round convex, gray to white-gray colonies [4-5] without hemolysis [6].

Due to the slow growth rate of this bacterium, ORT colonies may be hidden or covered by other bacteria, making it difficult to differentiate the bacterium from other infectious agents. To stop secondary infections, samples should be cultured on sheep blood agar containing gentamicin and polymyxin [5, 7] because about 90 % of ORT strains are resistant to these two antibiotics [4].

Infections caused by ORT cause mild respiratory symptoms in turkeys and other birds. Clinical signs include sinusitis, purulent pneumonia, tracheitis, air sac infections, and pericarditis. This bacterium could cause sudden death in young birds due to meningitis [4]. The presence of ORT in poultry as well as wild birds has been

reported worldwide, indicating a main source of this bacterium in the world. There are numerous reports of infection of various birds, especially poultry and turkeys, by this bacterium in Iran and the world. The bacterium was first isolated from turkeys, and it seems that the disease is more important in turkeys than in other birds. The seroprevalence of ORT is high and variable in turkey farms of many countries where the breeding of this bird is highly prevalent. For instance, 6.5% [8] of turkey farms in Belgium, 11.3% [9] in Turkey, 55% [4] in Germany, 83% [10] in Austria, 72.6% [11] in Poland, and 91% [21] in Slovenia have been reported to be infected by ORT. In terms of turkeys infection with this bacterium in Iran, Doosti et al. (2011) [12] studied the prevalence of ORT in turkey flocks in Isfahan province using the PCR method. The results indicated that 19.93% of swaps obtained from the orbital sinus of turkeys harbored the 16srRNA gene of ORT.

**Objectives:** Since ORT, as a disease known in turkeys, causes great economic losses to the turkey breeding industry, this study aimed to identify and estimate the rate of ORT infection in turkey flocks and also to examine the tissue distribution of the bacterium in different organs of infected turkeys in Isfahan province.

## Materials and Methods

**Sampling and study design:** Totally, 30 traditional and industrial turkey flocks with respiratory signs and mortality were sampled in Isfahan province. After necropsying the turkeys, samples were taken from the trachea, air sacs, lungs, whole head (for sampling of orbital sinuses, nasal mucosa, and brain), liver, spleen, hock joint, jejunum, kidneys, and blood clot in the heart. The samples were transferred to the laboratory close to the ice. The bacterial genome was extracted using a commercial DNA extraction kit (CinnaGen,

Iran) and stored at -20 ° C.

The primary target organ for detecting and determining ORT infection was tracheal tissue, and if the trachea was negative, the lung tissue was used to evaluate ORT infection. The negative samples were excluded from the study. In ORT-positive turkeys (based on the trachea or lung harboring 16S rRNA gene of ORT), all tissue samples were examined for the presence of ORT by PCR.

**Genome extraction:** The bacterial DNA was extracted from tissues and blood using a commercial kit (CinnaGen, Iran) according to the manufacturer's instructions.

**PCR:** The specific primers were synthesized based on the 16S rRNA gene of ORT according to the sequence published by Empel et al. (1999) as follows [5, 13]:

Ornitho-F:5'-GAGAAATTAATTTACGGATTAAG-3'

Ornitho-R:5'-TTCGCTTGGTCTCCGAAGAT-3'

The PCR reaction was achieved in a final volume of 25 µL, including 1 µg of DNA sample, 1 µL of each primer, 2 µL of magnesium chloride, 200 µL of dNTPs, 2.5 µL of buffer 10X, and 1 µL of Taq Polymerase (Fermentas, Germany) by a Mastercycler Gradient device (Eppendorf, Germany). The temperature program included a cycle of 94 °C for 5 min, 45 replicative cycles consisting of denaturation at 94 °C for 30 s, annealing at 52 °C for 1 min, extension at 72 °C for 90 s, and a final extension at 72 °C for 7 min [13].

The PCR product was electrophoresed on 1%

agarose gel at 80 volts for 30 min, and then the gel was stained with ethidium bromide and observed using a UV doc.

**Statistical analysis:** Finally, the infection in each turkey was reported as positive based on the detection of 16S rRNA in the trachea and lung. The difference in the levels of infectivity in tissue samples was analyzed at a confidence level of 95% using Sigma Plot statistical software and one way ANOVA method.

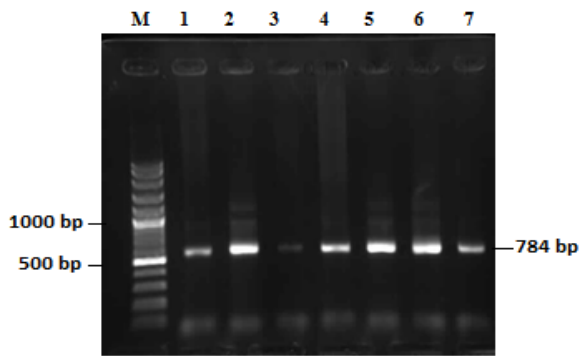
### Findings

The results indicated that 16 out of 30 flocks harbored 16S rRNA gene of ORT in the trachea or lungs (53%), which was demonstrated by amplification of 784 bp fragment of 16S rRNA gene (Figure 1). The detection rate of 16S rRNA gene of ORT in each sample is presented in Table 1. In five out of 16 (31.25%), all respiratory tissues, including the trachea, lungs, orbital sinuses, and nasal mucosa were positive. In 68.75% of turkeys, at least one sample of these 5 respiratory tissues was negative for 16srRNA gene of ORT. In most turkeys, the trachea was positive (87.5%), exception for two turkeys in which the trachea was negative, and the lung was positive. In one turkey, only the lung was positive, and the other organs were negative for 16S rRNA gene of ORT. The 16s rRNA gene of ORT was detected in the lungs and nasal mucosa of one turkey, but not in the trachea, air sacs, and sinuses.

**Table 1)** Percentage of 16SrRNA detection in each tissue in ORT-infected turkeys

	Kidney	Intestine	Brain	Blood	Spleen	Liver	Hock joint	Orbital sinus	Nasal mucosa	Air sac	Lung	Trachea
Number of positive samples	0	0	2	3	2	3	6	9	11	10	11	14
Percentage of positive samples	0	0	12.5e	18.75d	12.5e	18.75d	37.5c	56.25b	68.75b	62.5b	68.75b	87.5a

Different t letters in each cell indicate a significant difference ( $p < .05$ )



**Figure 1)** Electrophoresis of PCR products of 16S rRNA gene of *Ornithobacterium rhinotracheale* in the samples M: Marker with a size of 100 bp DNA (CinnaGen, Iran), 1: Positive control, 2: Positive liver sample, 3: Positive tracheal sample, 4: Positive blood sample, 5: Positive lung sample, 6: Positive air sac sample, and 7: Positive sinus tissue sample.

### Discussion

ORT infection could cause respiratory and musculoskeletal lesions and affect a large number of birds. Although the disease could be observed in 2-week-old and older turkeys, the severe disease appears usually after 14 weeks and more in breeders, especially males. The causative agent spreads horizontally and vertically, directly and indirectly. Although there are many doubts about the pathogenicity of this bacterium in birds, and some researchers have named this factor as a secondary factor, recent studies have found that ORT could be a primary pathogen. Symptoms of this disease are very diverse in turkeys, including unilateral or bilateral pneumonia along with fibrinous exudate and mild to severe tracheitis, fibrinous purulent inflammation of the air sacs, liver and spleen lesions, heart muscle degeneration, and vertebrae and joint infection.

This research results indicated that ORT was involved in complicating respiratory symptoms in about 53% of respiratory syndrome cases in turkeys in Isfahan. Even though the autopsy of birds indicates pneumonia, tracheitis, and sometimes fibrinous purulent inflammation of the air sacs, liver, and even heart, attributing the

symptoms to ORT might be wrong; however, ORT-associated infections should not be overlooked. The existence of this bacterium and the infection of 20% of broiler flocks by this bacterium have been reported in slaughterhouses of Isfahan province using PCR, but the present study specifically focused on the prevalence of ORT infection in turkeys with respiratory symptoms. Despite the lack of similar reports on turkeys, Roepke et al. [14] reported the isolation rate of ORT from poultry flocks with respiratory symptoms as 57.5% using the culture method, indicating a high prevalence of ORT infection in flocks with respiratory symptoms. A great number of studies have been conducted to identify ORT in poultry flocks in Iran, but they have been mainly conducted for epidemiological purposes of the disease in different provinces. According to the available data, there are some reports of the disease outbreaks in broiler chickens in Gilan, Babol, Qazvin, Tabriz, Ahvaz, Shahrekord, and Isfahan [15-16]. There are only two reports on the disease prevalence in turkeys in Isfahan and different regions of Iran, both cases have been conducted on slaughterhouses to detect ORT using PCR. In these two reports, the rate of ORT infection has been reported to be about 20%. The difference between the infection rate in this study and the other studies mentioned is due to the fact that in this study, birds with respiratory symptoms were sampled. The present study showed for the first time in Iran that the rate of ORT infection in turkeys with respiratory symptoms, as the main host of ORT, is high. Previous studies have revealed that there are common pathogenic serotypes between chicken and turkey. These serotypes could be easily transferred from one host to another. Thus, it is necessary to monitor the bacterium in each region in order to control this infection.

In this study, the identification of ORT

infection was based on the detection of the 16S rRNA gene in the trachea and lung. In the present study, only in two turkeys, the trachea was negative for ORT, and the lung was examined to detect ORT. The question is whether other respiratory organs are suitable samples for detecting ORT infection. The results of the present study showed that the lung or trachea was the best tissue sample for detecting ORT infection in turkeys, and ORT was less likely to be detected in other tissues. There is no significant difference in detection rate of ORT 16SrRNA gene between the tissues of the nasal mucosa, air sacs, and orbital sinus in turkeys, while there is a significant difference between ORT detection rate in respiratory tissues and other tissues such as liver, spleen, joints, blood, and brain. There are various reports about the possibility of ORT detection in different organs [17]. Kilic et al. (2009) reported that despite lesions observed in 50% of the sinuses, 40% of the larynxes, 40% of the lungs, and 40% of the air sacs of broilers infected with ORT, the detection of ORT genome was possible only in the trachea and lungs in the first and second weeks after infection [17]. In the present study, ORT genome was detected in other respiratory tissues of more than 50% of chickens, such as nasal mucosa, orbital sinuses, and air sacs. A study by Tachil et al. (2009) [18] on poultry showed that ORT could not be isolated from the lungs, while less than 50% of ORT could be isolated from the trachea and air sacs, and ORT could be isolated from the sinuses up to 28 days after infection. Ozbey et al. (2004) found that although ORT was isolated from the trachea of 5 chickens, simultaneous isolation of ORT from the trachea and lungs was observed only in one chicken [13]. Roepke et al. (1998) reported the possibility of isolating ORT from the trachea (40%), lungs (59%), air sacs (63%), and sinuses (37.5), while in their study, the ORT bacterium was

not isolated from the blood of the heart, pericardium, liver, and eye [14]. This report is inconsistent with the results of the present study and another study by Thachil et al. (2009), as they showed that ORT could be isolated from the liver and spleen of infected birds [18]. In this study, the ORT genome was detected in 19% of liver and 12% of spleen samples. No regular pattern in ORT genome detection in organs indicated that the samples were not taken at a certain stage of the disease, and different samples were taken at different stages of the disease because the distribution of ORT bacterial genome in various organs varies from the involvement of the trachea and lungs to the involvement of all respiratory tissues; some visceral organs, such as the liver and spleen; and distant non-respiratory organs, such as the brain and joints.

According to the tissue distribution of ORT genome, it is a respiratory bacterium that tends to spread vertically or systematically so that its distribution is evident in other non-respiratory organs such as the brain and joints. Furthermore, lack of detection of ORT infection in the intestine and kidney indicates the impossibility of ORT pathogenicity in the gastrointestinal tract; thus, there is no the possibility of its transmission through the gastrointestinal tract. There is no report about the transmission of this bacterium through feces. Zbikowski et al. (2013) failed to detect ORT in these two organs by experimental studies and continuous monitoring of the bacterium in the intestine and kidneys [19].

### **Conclusion**

The present study indicated that the tissue distribution of ORT was not the same in all infected turkeys probably due to the method, dose, infection route, and the duration of infection. The serotype diversity of the bacterium, the type of common serotypes,

immunological status of birds, and possibly individual differences might be involved in ORT tissue distribution.

**Acknowledgements:** The authors would like to appreciate all persons that help them in this research specially the staffs of Shahrekord branch of Azad university.

**Ethical Permission:** This study was confirmed by Ethics committee of Azad university of Sharekord Branch.

**Conflicts of Interests:** The authors declare that they have no competing interests.

**Authors Contribution:** Conceptualization: MGA & MKD; Data curation and formal analysis: MGA, MKD, MHS; Investigation: HH & MGA; Methodology and project administration: HH & MGA; Supervision: MGA, MKD & AAD; Validation: MHS & MKD; Writing of original draft: MKD, AAD; Writing, reviewing, and editing: AAD & MHS.

**Fundings:** Self-Funding.

**Consent to participate:** Consent was obtained from each turkey farm owner.

## References

1. Vandamme P, Segers P, Vancanneyt M, van Hove K, Muters R, Hommez J, et al. *Ornithobacterium rhinotracheale* gen. nov., sp. nov., isolated from the avian respiratory tract. *Int J Syst Bacteriol.* 1994;44(1):24-37.
2. Tahseen A. *Ornithobacterium rhinotracheale* developing into a serious infection. *World Poult Misset.* 1997;13: 47-8.
3. Kursa O, Tomczyk G, Sawicka-Durkalec A, Giza A, Słomiany-Szwarc M. Bacterial communities of the upper respiratory tract of turkeys. *Sci Rep.* 2021;11(1):1-1.
4. Van Empel P, Hafez H. *Ornithobacterium rhinotracheale*: A review. *Avian Pathol.* 1999;28(3):217-27.
5. van Empel P, Vrijenhoek M, Goovaerts D, van den Bosch H. Immunohistochemical and serological investigation of experimental *Ornithobacterium rhinotracheale* infection in chickens. *Avian Pathol.* 1999;28(2):187-93.
6. Chin RP, Droual R. *Ornithobacterium rhinotracheale* infection. In: Calnek BW, editor. *Diseases of poultry.* 10<sup>th</sup> ed. Iowa State University Press, Ames, IA; 1997, pp. 1012-5.
7. van Veen L, van Empel CP, Fabria T. *Ornithobacterium rhinotracheale*, a primary pathogen in broilers. *Avian Dis.* 2000;44(4):896-900.
8. Suzuki K, Petrucci M, Trenchi G, Giossa G, Rodríguez G, Trenchi H. Flock-level seroprevalence against *Ornithobacterium rhinotracheale* among broilers in Uruguay. *Int J Poult Sci.* 2010; 9(2):167-70.
9. Allymehr M. Seroprevalence of *Ornithobacterium rhinotracheale* infection in broiler and broiler breeder chickens in West Azerbaijan Province, Iran. *J Vet Med A Physiol Pathol Clin Med.* 2006;53(1):40-2.
10. Asadpour Y, Bozorgmehrifard MH, Pourbakhsh SA, Banani M, Charkhkar S. Isolation and identification of *Ornithobacterium rhinotracheale* in broiler breeder flocks of Guilan province, north of Iran. *Pak J Biol Sci.* 2008;11(11):1487-91.
11. Ghanbarpour R, Salehi M. Sero-prevalence and identification of *Ornithobacterium rhinotracheale* in broiler flocks in south-eastern Iran. *Trop Anim Health Prod.* 2009;41(8):1679-83.
12. Doosti A, Sharifzadeh A, Ghasemi H, Vaez J. Molecular identification of *Ornithobacterium rhinotracheale* in turkeys in Isfahan province of Iran. *Afr J Biotechnol.* 2011;10(40):7911-4.
13. Ozbey G, Ongor H, Turgut-Balik D, Celik V, Kilic A, Muz A. Investigations on *Ornithobacterium rhinotracheale* in broiler flocks in Elazig province located in the East of Turkey. *Vet Med.* 2004;49(8):305-11.
14. Roepke DC, Back A, Shaw DP, Nagaraja

- KV, Sprenger SJ, Halvorson DA. Isolation and identification of *Ornithobacterium rhinotracheale* from commercial turkey flocks in the upper Midwest. *Avian Dis.* 1998;42(1):219-21.
15. Asadi J, Gholami-Ahangaran M, Momtaz H. Molecular detection of *Ornithobacterium rhinotracheale* in quails of Isfahan province. *Iran Clinical Pathol.* 2018;12(1):1-7.
16. Shabani A, Gholami-Ahangran M, Momtaz H. Molecular detection of *Ornithobacterium rhinotracheale* and Newcastle disease virus in ostriches of Isfahan province. *Vet Clin Pathol.* 2017;11(2):97-105.
17. Kilic A, Timurkaan N, Ertas H, Yilmaz F. Pathological examination and bacterial reisolation by culture and PCR of experimental *Ornithobacterium rhinotracheale* infection in broiler chickens. *Revue Méd Vét.* 2009;160(3):140-4.
18. Thachil A, Velayudhan B, Shaw D, Halvorson D, Nagaraja K. Pathogenesis of *Ornithobacterium rhinotracheale* in egg-laying hens with coexisting infectious bronchitis virus and *Escherichia coli* infections. *J Appl Poult Res.* 2009;18(4):780-8.
19. Zbikowski A, Szeleszczuk P, Binek M. Tissue tropism of *Ornithobacterium rhinotracheale* in chickens determined by culture and nucleic acid detection. *Pol J Microbiol.* 2013;62(2):205-9.