

## Case Report

DOI: 10.22114/ajem.v0i0.114

**An Effective Method for Controlling Bleeding in a Ruptured Hepatic Hemangioma: A Case Report**Mohammad Talebpour<sup>1</sup>, Hossein Zabihi-Mahmoudabadi<sup>1\*</sup>, Pooya Payandemehr<sup>2</sup>, Maryam Momen<sup>1</sup>, Zahra Zali<sup>3</sup>

1. Department of Surgery, Sina Hospital, Tehran University of Medical Sciences, Tehran, Iran.

2. Department of Emergency Medicine, Sina Hospital, Tehran University of Medical Sciences, Tehran, Iran.

3. School of Medicine, Shahid Beheshti University of Medical Sciences, Tehran, Iran.

\*Corresponding author: Hossein Zabihi-Mahmoudabadi; Email: h.zabihi.dr@gmail.com

**Abstract**

**Introduction:** Hepatic hemangioma is the most common benign tumor in the liver. Although intra-abdominal bleeding associated with its rupture is rare, but life-threatening. Here we report a case of ruptured hepatic hemangioma and applied method for controlling its bleeding.

**Case Report:** The patient was a 45-year-old man who was referred after crashing his motorcycle into a car. The patient's primary survey revealed intra-abdominal free fluid, but stable vital signs. Thirty minutes later, the patient's systolic blood pressure dropped to 85 mmHg. Laparotomy was performed a large hemangioma was observed involving almost the entire left lobe of the liver. Using a liver needle and 2-0 chromic suture, we entered the hemangioma at the perforation site of the lower portion of the liver and exit from the upper part. Then, we entered the upper part of the liver and exited from the lower part, and then it was tied. According to this approach, hemangioma was packed from the lower segment of the liver.

**Conclusion:** In this case, the patient's abdomen was primarily closed without extra packing and embolization. The proposed method thus may be more effective compared to conventionally used methods.

**Key words:** Accidents, Traffic; Hemangioma; Hemorrhage; Surgical Procedures, Operative

**Cite this article as:** Talebpour M, Zabihi-Mahmoudabadi H, Payandemehr P, Momen M, Zali Z. An Effective Method for Controlling Bleeding in a Ruptured Hepatic Hemangioma: A Case Report. *Adv J Emerg Med.* 2019;3(\*): e\*.

**INTRODUCTION**

Hepatic hemangioma is the most common benign tumor in the liver, and is often diagnosed using computed tomography (CT) scan or magnetic resonance imaging (MRI). A hemangioma larger than 4 cm is referred to as a giant hemangioma. In rare cases, a hemangioma can rupture spontaneously or as a result of traumas (1). While most hemangiomas (59.1%) are found in the right lobe of the liver, 13.6% occur in the left lobe and 27.3% in both lobes. Moreover, the perforation of hemangiomas occurs in the left lobe 40%, the right lobe 56% and both lobes 4% of the time. Although intra-abdominal bleeding associated with the rupture of a hepatic hemangioma is rare, but life-threatening (2). Here we report a case of ruptured hepatic hemangioma and applied method for controlling its bleeding.

**CASE PRESENTATION**

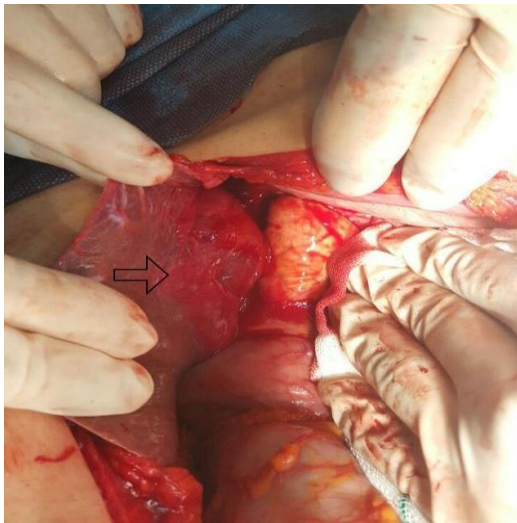
The patient was a 45-year-old man who was referred to Sina hospital, Tehran, Iran by ambulance after crashing his motorcycle into a car.

The patient's airway and breathing examination

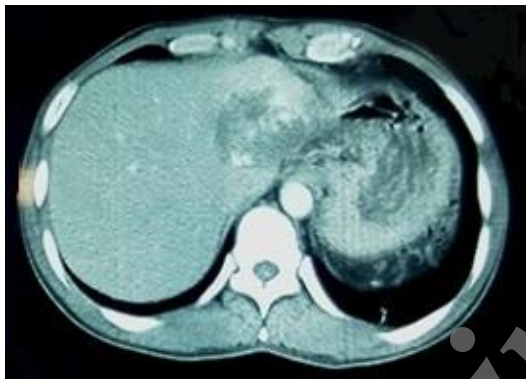
suggested no problems. Moreover, no external bleeding was observed. His focused assessment with sonography in trauma (FAST) was positive. The patient's Glasgow Coma Scale (GCS) was 15. Upon hospital admission, his blood pressure (BP) was 110/75 mmHg, pulse rate 84 beats/minute, and respiratory rate 18 breaths/minute.

The patient was candidate for the CT scan of abdomen and pelvis. Thirty minutes after applying the initial intravenous fluid therapy, the patient's systolic blood pressure dropped to 85 mmHg. The transfusion of packed red blood cells (PRBCs) began by transferring the patient to the surgery room.

A laparotomy was performed and about 3 L of blood and clots were found in the patient's abdomen. After the blood suction, a partial splenic rupture (grade II injury) was identified in the inferior pole and controlled by packing. However, widespread bleeding was observed in the liver, which could not be controlled by packing. A large hemangioma was observed involving almost the entire left lobe of the liver. The hemangioma was ruptured at two points, including segments II and



**Figure 1:** The ruptured hepatic hemangioma is indicated by the arrow



**Figure 2:** The axial view of patient's abdominal CT scan two weeks after the surgery

III of the liver, with lacerations extending 2-3 cm (Figure 1). A horizontal mattress suture was done to control bleeding.

Using a liver needle and 2-0 chromic suture, we entered the hemangioma at the perforation site of the lower portion of the liver and exit from the upper part. Then, we entered the upper part of the liver and exited from the lower part, and then it was tied. According to this approach, hemangioma was packed from the lower segment of the liver. The whole liver was not circled to repair the second perforation owing to the large size of the liver. We entered from the perforation and circled half of the liver thickness with a horizontal mattress suture. Then, the intra-abdominal area was totally re-examined. Oozing was observed from the inferior pole of spleen, so splenectomy was conducted. A drainage tube was inserted around the hepatic hemangioma, and the abdomen was closed. The patient received 4 units of PRBC and 4 units of fresh frozen plasma (FFP)

during the surgery. The patient's BP was 110/70 mmHg at the end of the surgery.

The patient was transferred from the intensive care unit (ICU) to the ward after 2 days and he was discharged from the hospital in a good general health condition after 5 days. Around 2 weeks after the surgery, a CT scan was performed (Figure 2). The patient's status was stable during the 8 weeks' follow-up.

#### DISCUSSIONS

Although the rupture of a hepatic hemangioma is rare, it is fatal in 60–75% of the cases. According to the studies conducted on patients with ruptured hemangiomas in 1989-2002, 59.1% of the cases underwent surgical resection, bleeding was controlled by suture in 22.7% of them, and 18.2% of the cases were packed and received a tamponade. Mortality rates were 23.1%, 45%, and 75%, in these three groups respectively. It is worth noting that all the patients who underwent embolization before surgery survived (3). It is likely that packing and using a tamponade is not reliable method for controlling bleeding, as packing failed to control bleeding in our patient.

Beatty et al. reported a case with abdominal compartment syndrome following embolization. An emergency laparotomy was performed and 6 L of blood was removed from the patient's abdomen. A GIA™ stapler was used to remove the mass. The present case involved an open abdomen, which was closed with mesh after several days of hospitalization (4).

Similar to the presented case, Lung-Yun Kang et al. studied the control of intra-abdominal bleeding using a Teflon suture and packing, followed by drain insertion and temporarily closing the abdomen. The abdomen was, however, reopened due to bleeding, and a splenectomy was performed as a result of a missed splenic laceration. Due to the lack of liver packing, a Teflon suture was reused for the liver. According to the report, the patient's abdomen was then closed with mesh (5).

Some reported patient death due to bleeding and incomplete hemostasis. In contrast, some other reported that patients underwent a second surgery and hemostasis as incomplete hemostasis was associated to a high morbidity rate (6).

#### CONCLUSIONS

In this case, the patient's abdomen was primarily closed without extra packing and embolization. The proposed method thus may be more effective compared to conventionally used methods.

**ACKNOWLEDGMENTS**

None.

**CONFLICTS OF INTEREST**

None declared.

**AUTHORS' CONTRIBUTION**

All authors passed four criteria for authorship contribution based on recommendations of the International Committee of Medical Journal Editors.

**FUNDING**

None declared.

**REFERENCES**

1. Zinner MJ, Schwartz S, Ellis H. Maingot's abdominal operations. *J Am Coll Surg.* 1997;3(185):307.
2. Mannino M, Toro A, Palumbo V, Carlo ID. Hepatic hemangiomas of the liver: when operate and with which vascular exclusion. *Ann Laparosc Endosc Surg.* 2018;3:9.
3. Corigliano N, Mercantini P, Amodio PM, Balducci G, Caterino S, Ramacciato G, et al. Hemoperitoneum from a spontaneous rupture of a giant hemangioma of the liver: report of a case. *Surg today.* 2003;33(6):459-63.
4. Beatty JS, Mitchell JW, Holsten SB, Ferdinand CH. Traumatic rupture of a previously undiagnosed giant hepatic hemangioma. *Am Surg.* 2013;79(9):e314-5.
5. Kang LY, Huang FD, Liu YY. Blunt abdominal injury with rupture of giant hepatic cavernous hemangioma and laceration of the spleen. *Hepatobiliary Pancreat Dis Int.* 2015;14(1):109-10.
6. Guillen-Paredes MP, Martinez Fernandez J, Morales Gonzalez A, Pardo-Garcia JL. Spontaneous rupture of a liver hemangioma. A case report. *Rev Esp Enferm Dig.* 2016;108(7):431.