

Case Report

DOI: 10.22114/ajem.v0i0.287

Bidirectional Ventricular Tachycardia in a Women with Dilated Cardiomyopathy: A Case Report

Dalton Argean Norwood^{1*}, Lucia Belem Dominguez¹, Ricardo Leonel Dominguez¹, Walter Tyler Winders²

1. Hospital de Occidente, Santa Rosa de Copan, Honduras.

2. Department of Emergency Medicine, Medical University of South Carolina, Charleston, USA.

*Corresponding author: Dalton Argean Norwood; Email: daltonnorwood1@gmail.com

Published online: 2019-10-31

Abstract

Introduction: Bidirectional ventricular tachycardia (BVT) is a rare arrhythmia characterized by QRS complexes with an axis in the frontal plane alternating polarity in the precordial leads and right bundle branch block (RBBB) morphology. To the best of our knowledge, there is no previous report in dilated cardiomyopathy or in the context of a probable peripartum cardiomyopathy.

Case Presentation: A 26-year-old, 9-month female patient, with no significant past medical history (the patient denies medication intake, herbs like aconite, trouble during delivery, any heart issues or family history of sudden death or cardiomyopathies) who presents to the emergency room due to 11 days of dyspnea, exacerbated by daily activities, orthopnea, and paroxysmal nocturnal dyspnea. She presented with ventricular bigeminy and systolic dysfunction with left ventricular ejection fraction (LVEF) <20%. The patient later developed a stable ventricular tachycardia (VT) treated with amiodarone, which resulted in hemodynamic instability and BVT rhythm with VT paroxysms. Without the possibility of ablation, the use of high dose beta blockers and an implantable cardioverter defibrillator resulted in the same rhythm with a lower heart rate, better NYHA functional class, and less episodes of VTs.

Conclusion: BVT is a rare type of tachycardia that can be present in dilated cardiomyopathy. In the absence of ablation capabilities, decreasing the heart rate with beta-blockers may reduce the rate of paroxysmal VTs.

Key words: Arrhythmias, Cardiac; Bidirectional Tachycardia; Cardiomyopathy, Dilated; Tachycardia, Ventricular

Cite this article as: Norwood DA, Dominguez LB, Dominguez RL, Winders WT. Bidirectional Ventricular Tachycardia in a Women with Dilated Cardiomyopathy: A Case Report. *Adv J Emerg Med.* 2020;4(1):e12.

INTRODUCTION

Bidirectional ventricular tachycardia (BVT) is a rare type of ventricular (wide complex) tachyarrhythmia characterized by QRS complexes with an axis in the frontal plane alternating polarity between -60 to -90 and +120 to +130 in the precordial leads and right bundle branch block (RBBB) morphology (1). In other words, it is defined as ventricular tachycardia (VT) with a regular rate and 2 QRS morphologies with opposite polarities (2).

BVT is usually due to digoxin toxicity, aconite poisoning, hypokalemic periodic paralysis, catecholaminergic polymorphic ventricular tachycardia, and Anderson-Tawil syndrome (3). There have also been case reports of BVT in patients with acute myocarditis, myocardial infarction, severe aortic stenosis, left ventricular hypertrophy, cardiac sarcoidosis, and ischemic cardiomyopathy in the absence of acute coronary syndrome (ACS) (4-7).

The pathogenesis is unknown, although the

proposed arrhythmia mechanism is a triggered activity arising alternately from the left anterior and posterior fascicle (8, 9). This results in an alternating left and right frontal-plane axis, giving rise to a typical "bidirectional" appearance.

One of the proposed mechanisms postulated for BVT include elevated intracellular calcium, causing delay after depolarization in anatomically separate parts of the conducting system (10). When the ventricular rate exceeds the lower threshold, bigeminy develops. This would effectively double the heart rate, increasing the overall ventricular rate above the second threshold. Subsequently, the two competing sites would simply alternate on a beat-to-beat basis. This is likely the mechanism underlying BVT observed with digitalis toxicity and catecholaminergic polymorphic VT (11). As the natural history of the disease, there have been reports of sustained monomorphic VT occurred intermittently with bidirectional VT (8).

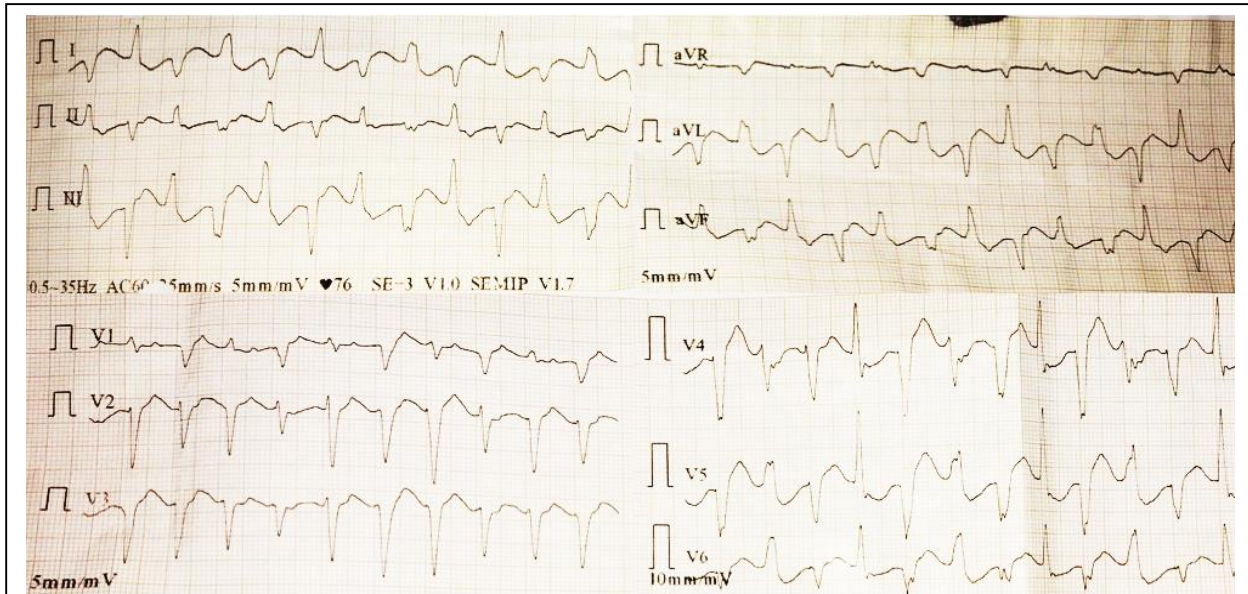


Figure 1: A 12 lead ECG of a 26-year-old female with Bidirectional Ventricular Tachycardia [Note: A 12 lead ECG with a regular rhythm wide complexes (0.12ms) tachycardia (+/-200bpm) with alternating with a right deviation of 120° (DI: -5 and DIII: +10) and a left deviation of -45° (DI: +8 and DIII: -11) with an image of right bundle branch block].

In this article, we discuss a case of BVT in a 9-month postpartum woman with a new diagnosis of dilated cardiomyopathy in rural Honduras. To our knowledge, this has not been described previously in the literature.

CASE PRESENTATION

A 26-year-old, 9-month postpartum female, with no significant past medical history (the patient denies medication intake, herbs like aconite, trouble during delivery, any heart issues or family history of sudden death or cardiomyopathies) who presents to the emergency room due to 11 days of dyspnea, exacerbated by daily activities, orthopnea, and paroxysmal nocturnal dyspnea (PND). Vital signs found on clinical examination were blood pressure of 90/60 mmHg, respiratory rate of 20 breaths per minute, and heart rate of 126 beats per minute. An irregular heart rhythm was noted with associated elevated jugular venous pressure (JVP). The chest x-ray on admission showed biventricular cardiomegaly and bilateral pleural effusion. The 12 lead electrocardiogram (ECG) reported irregular rhythm with bigeminy premature ventricular contractions (PVC). Echocardiography showed four chamber enlargement, systolic dysfunction with left ventricular ejection fraction (LVEF) <20%, severe mitral insufficiency, and pulmonary hypertension. Bloodwork was notable for a negative Chagas test and no electrolyte imbalance.

The second day after admission, the patient developed sustained VT. This was treated with

amiodarone bolus 150 mg over 10 minutes, shortly after she became hemodynamically unstable (hypotension and shock signs) without neurologic disturbance. The patient refused electrical cardioversion. We completed the amiodarone infusion (1mg/min over 6 hours) with no improvement in patient’s cardiac rhythm. The ECG presented a BVT rhythm with alternating axis and a RBBB image as shown in figure 1 and 2. Two days later with no change on patient rhythm or symptoms, the patient suffered a cardiac arrest. During cardiopulmonary resuscitation (CPR), the

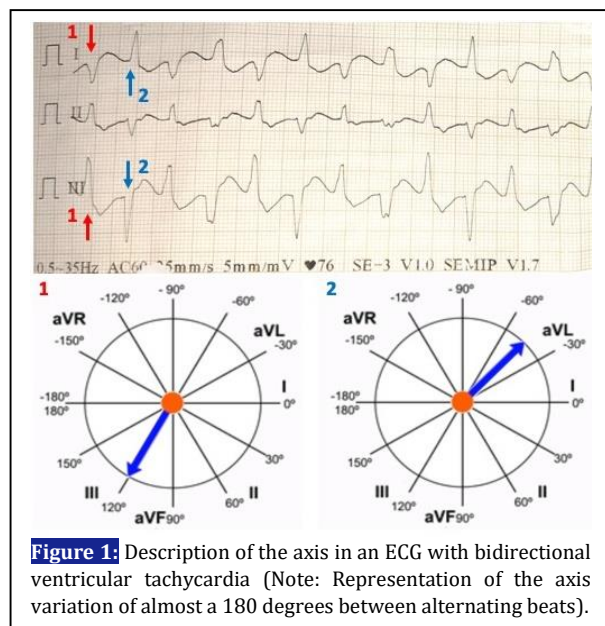


Figure 1: Description of the axis in an ECG with bidirectional ventricular tachycardia (Note: Representation of the axis variation of almost a 180 degrees between alternating beats).

patient had ventricular fibrillation (VF) that defibrillated with 360 J. Return of spontaneous circulation (ROSC) achieved after 8 minutes of CPR. Post ROSC, norepinephrine sustained adequate blood pressures. Patient had a normal heart rate persisting with the BVT rhythm.

A lidocaine trial as antiarrhythmic agent shows no improvement. Patient persisted with the BVT rhythm and multiple paroxysms of sustained VT. Without the possibility of ablation in the country and no financial capability to travel, staff placed an implantable cardioverter defibrillator (ICD) (programmed to deliver shock with a >200 bpm and >0.12ms QRS) and initiated propranolol until a maximal dose of 40 mg by mouth (PO) every 6 hours. This resulted in the same BVT rhythm with a lower heart rate and less episodes of paroxysmal monomorphic VTs. After 15 days of relative stability, staff discharged the patient from the hospital.

On the follow-up visits, patient had the same BVT rhythm with a slower pace rate of about 130 bpm, improvement of her NYHA functional class from class IV to class II, no symptoms on rest or minimal activity, and fewer instances of VTs.

DISCUSSIONS

There are well described cases of BVT due to aconite poisoning, digitalis toxicity, and other structural cardiac conditions; but we are unaware of any prior report in a postpartum patient or a dilated cardiomyopathy. In this case, there was no history of digitalis or herbal (aconite) compounds ingestion. The clinical circumstance of exercise or stress induced tachycardia in a usually young individual without structural heart disease was not present ruling out catecholaminergic polymorphic VT. There was no evidence of ischemic heart disease, tumor, or potassium

imbalance. Also, there was no history of familiar cases of sudden death or cardiac disease.

However, we made the diagnosis of dilated cardiomyopathy of unknown etiology. The context of 9 months after delivery rules out the diagnosis of peripartum dilated cardiomyopathy as a possible cause.

Finally, in many cases of BVT, staff is unable to identify the actual cause was not identified. Some case reports describe how improvement was obtained with amiodarone, but in our case amiodarone proved deleterious for the patient (causing hypotension) which is a frequent side effect. Electrical cardioversion is the preferred choice unstable tachycardia per advanced cardiac life supports (ACLS) guideline, however this patient refused this therapy

CONCLUSIONS

BVT is a rare type of tachycardia that can be present in patients with dilated cardiomyopathy. In absence of ablation capabilities, reducing heart rate with beta-blockers can reduce the rate of paroxysmal VTs.

ACKNOWLEDGMENTS

None.

AUTHORS' CONTRIBUTION

The author passed four criteria for authorship contribution based on recommendations of the International Committee of Medical Journal Editors.

CONFLICTS OF INTEREST

None declared.

FUNDING

None declared.

REFERENCES

1. Zipes DP, Jalife José. Cardiac electrophysiology: from cell to bedside. Philadelphia: Elsevier Saunders; 2014.
2. Wagner G: Morriott's Practical Electrocardiography, 9th ed. Baltimore: Williams and Wilkins, 1994.
3. Chakraborty P, Kaul B, Mandal K, Isser H, Bansal S, Subramanian A. Bidirectional ventricular tachycardia of unusual etiology. Indian Pacing Electrophysiol J. 2015;15(6):296-9.
4. Park YH, Kim J. Bidirectional ventricular tachycardia in a patient with acute myocardial infarction and aortic stenosis. Int J Cardiol. 2013;162(2):e41-2.
5. Bonnemeier H, Barantke M. It Is Not Always Digitalis: Bidirectional Ventricular Tachycardia in Left Ventricular Hypertrophy. Ann Noninvasive Electrocardiol. 2008;13(2):208-10.
6. Benjamin MM, Hayes K, Field ME, Scheinman MM, Hoffmayer KS. Bidirectional ventricular tachycardia in cardiac sarcoidosis. J Arrhythm. 2017;33(1):69-72.

7. Yeo C, Green MS, Nair GM, Birnie DH, Nery PB, Sadek MM. Bidirectional ventricular tachycardia in ischemic cardiomyopathy during ablation. *HeartRhythm Case Rep.* 2017;3(11):527-30.
8. Richter S, Brugada P. Bidirectional Ventricular Tachycardia. *J Am Coll Cardiol.* 2009;54(13):1189.
9. Cohen SI, Deisseroth A, Hecht HS. Infra-His Bundle Origin of Bidirectional Tachycardia. *Circulation.* 1973;47(6):1260-6.
10. Baher AA, Uy M, Xie F, Garfinkel A, Qu Z, Weiss JN. Bidirectional ventricular tachycardia: Ping pong in the His–Purkinje system. *Heart Rhythm.* 2011;8(4):599-605.
11. Lien WC, Huang CH, Chen WJ. Bidirectional ventricular tachycardia resulting from digoxin and amiodarone treatment of rapid atrial fibrillation. *Am J Emerg Med.* 2004;22(3):235-6.