

Original Article

DOI: 10.22114/ajem.v0i0.322

MRI Findings in Children with the First Unprovoked Seizure Presenting to the Emergency Department; Does Developmental Delay Suggest the Importance of Brain MRI Evaluation?

Niloofer Ayoobi-Yazdi¹, Mehran Beiraghi-Toosi², Farzad Ashrafi^{3*}, Athena Aliabadi¹, Mehran Arab-Ahmadi¹

1. Advanced Diagnostic and Interventional Radiology Research Center, Tehran University of Medical Science, Tehran, Iran.

2. Department of Pediatric Neurology, Mashhad University of Medical Science, Mashhad, Iran.

3. Department of Neurology, Shohada Tajrish Hospital, Shahid Beheshti University of Medical Science, Tehran, Iran.

*Corresponding author: Farzad Ashrafi; Email: farzad.ashrafi@gmail.com

Published online: 2020-02-17

Abstract

Introduction: The first unprovoked seizure (FUS) in children is a convulsive seizure with an unknown cause, which may be due to an underlying neurological disease or a manifestation of epilepsy.

Objective: The aim of this study was to evaluate the findings of brain magnetic resonance imaging (MRI) in pediatric patients with FUS, presenting to the emergency department (ED).

Methods: In this cross-sectional study, all children with FUS (age: >1month and <14 years), who were referred to the ED of Qaem Hospital, Mashhad, Iran from 2016 to 2019, were investigated. Medical records, brain MRI findings, electroencephalography (EEG) results, and developmental status of children were reviewed retrospectively.

Results: The brain MRI findings of 56 children with FUS were reviewed. The mean age of children was 3.92±6.05 years, and the sex distribution was equal. Seventeen (30.4%) patients had abnormal EEG findings, while 13 (23.2%) patients had non-specific EEG findings. Neurological examination of 4 (7.1%) children was abnormal. Overall, 6 (10.7%) patients had non-specific abnormal brain MRI findings for seizure, while 3 (5.4%) patients had specific abnormal findings. A significant relationship was observed between the developmental status of children and abnormal MRI findings (P=0.04). However, MRI findings had no significant relationship with EEG or neurological findings (P>0.05).

Conclusion: It may be useful to perform brain MRI for children with FUS presenting to ED, especially those who are suspected of developmental disorders.

Key words: Emergency Service, Hospital; Magnetic Resonance Imaging; Pediatrics; Seizures

Cite this article as: Ayoobi-Yazdi N, Beiraghi-Toosi M, Ashrafi F, Aliabadi A, Arab-Ahmadi M. MRI Findings in Children with the First Unprovoked Seizure Presenting to the Emergency Department; Does Developmental Delay Suggest the Importance of Brain MRI Evaluation? Adv J Emerg Med. 2020;4(3):e75.

INTRODUCTION

Epilepsy is a relatively common disease in childhood. The prevalence of epilepsy has been estimated at 5 per 1000 people in developed countries and 7.5 to 44.3 per 1000 children in developing countries (1). Seizures account for 1-2% of all emergency department (ED) visits, and approximately one-fourth of these cases are first seizures (2). The first unprovoked seizure (FUS) is a seizure with no history or known precipitating cause, which may be due to an underlying neurological disease or a manifestation of epilepsy (3). Accurate history-taking, clinical examination and use of appropriate paraclinical methods can improve identification of the cause. Previous studies on the value of imaging evaluations in FUS patients have reported abnormal brain imaging findings, with a prevalence of 10-33% (4-9).

However, there is no consensus on the importance of brain magnetic resonance imaging (MRI) for children with FUS, without a motivating reason. On the one hand, unnecessary use of MRI in children may increase the costs, and on the other hand, delayed diagnosis of brain lesions due to lack of brain MRI can lead to adverse consequences, such as recurrent seizures or status epilepticus. In this study, we aimed to evaluate the brain MRI findings of pediatric patients with FUS presenting to ED.

Methods

Study design

This cross-sectional study was conducted from March 20, 2016 to March 20, 2019 at the ED of Qaem Hospital in Mashhad, Iran. All collected data were used anonymously, and required permission

was obtained from the ethics committee of Mashhad University of Medical Sciences (Code: IR.MUMS.FN.REC.1394.585)

Study population

All children with FUS (>1 month and <14 years), who were referred to the ED were investigated. The exclusion criteria were as follows: 1) presence of fever with seizure; 2) history of an underlying genetic, metabolic, or anatomical brain disorder; 3) history of a major psychiatric disorder; and 4) history of drug ingestion or intoxication. Consecutive sampling method was applied in this study retrospectively.

Data collection

Using a pre-made checklist, the patients' records were evaluated. Clinical symptoms (based on neurological examination and dysmorphic appearance), medical history including the type of seizure (focal, generalized, tonic-clonic, myoclonic and nondescript), developmental status, family history of seizure, age, and also findings of electrocardiography (ECG) and brain MRI were evaluated. Seizure-related and unrelated findings of brain MRI were reported by an expert neuroradiologist with at least ten years of experience and divided into three groups including normal, non-specific abnormal findings for seizure (e.g., arachnoid cyst and extra-ventricular obstructive hydrocephalus) and specific abnormal findings (e.g., mesotemporal gliosis, heterotopia, and Chiari I malformation).

Statistical analysis

Data are presented as frequency and percentage, mean and standard deviation (SD), or median and quartile, as appropriate. We used the Venn diagram to demonstrate the abnormal distribution of clinical and imaging findings. We also used Chi-square and Fisher's exact tests to compare the relationship between two categorical variables, such as MRI finding and another categorical variable. In addition, we used student's t-test to assess the mean differences between the two groups or its non-parametric equivalent (Mann-Whitney U test), as appropriate. P-value less than 0.05 was considered statistically significant. All statistical analyses were conducted using SPSS version 25.0.

RESULTS

Fifty-six children were finally enrolled in this study. The mean age of subjects was 3.92±6.05 years (minimum= 1 month; maximum= 14 years). The mean age of the patients in the two groups based on presence or absence of abnormal MRI findings were not statistically significant

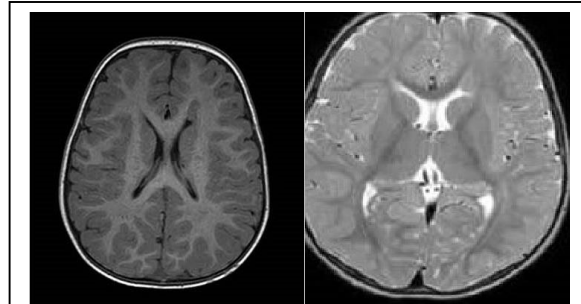


Figure 1: Sub endymal nodule and signal line left lateral ventricle follows gray matter intensity in both T1 weighted and proton density sequences typical of periventricular heterotopia

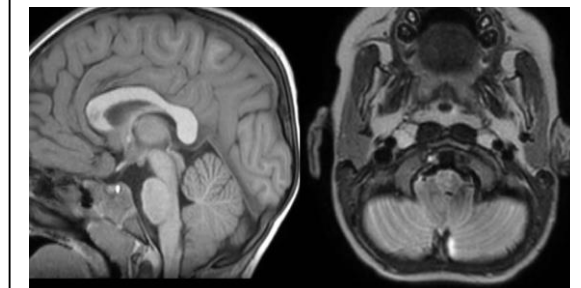


Figure 2: Axial T2 and sagittal T1 images reveal Caudal herniation of cerebral tonsils through foramen magnum: Chiari I malformation

(p=0.742). In terms of sex, the number of girls and boys was equal. Considering the clinical type of seizure, 26 (44.6%) cases were tonic, 21 (37.5%) cases were generalized tonic-clonic, 8 (14.3%) cases were focal clonic, 1 (1.8%) case was generalized clonic, and 1 (1.8%) case was myoclonic. Based on the EEG findings of children, 25 (44.6%) cases were normal, 17 (30.4%) cases

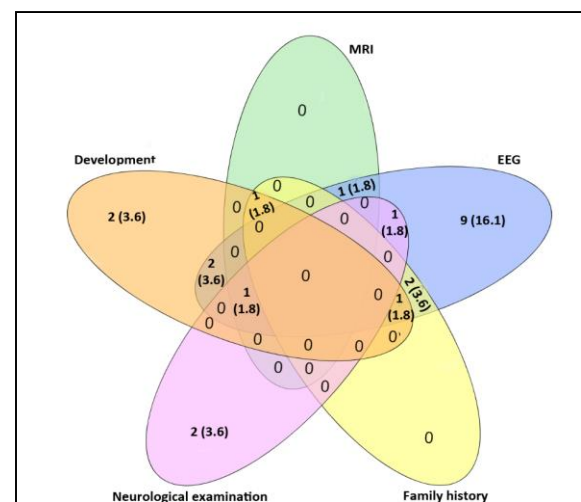


Figure 3: Venn diagram of abnormality distribution of clinical and historical criteria of first unprovoked seizure in child patients

were abnormal, and 13 (23.2%) cases were non-specific. With respect to brain MRI findings, 47 (38.9%) children had normal MRI, 6 (10.7%) children had non-specific findings for seizure, and 3 (5.4%) children had proven abnormal brain MRI findings for seizure, such as periventricular heterotopia (Figure 1).

Among subjects with a normal developmental status, 49 children had normal MRI findings, and only one child had an abnormal MRI finding. In children with an abnormal development (n=7), five had normal or non-specific MRI findings, and two

had specific MRI findings such as Chiari I malformation (Figure 2). Overall, one child with abnormal EEG, one child with abnormal development and positive family history, and one child with abnormal EEG, development, and neurological findings showed abnormal MRI results. Therefore, MRI alone could not detect an abnormality, which was not identified using other four clinical and historical criteria (Figure 3).

Overall, 22 (39.3%) patients had at least one positive clinical sign or family history of seizure. These patients were older than those without any

Table 1: The demographical characteristic, type of seizure and clinical sign in FUS patients with at-last one positive clinical sign or family history of epilepsy

	Sex	Age	Seizure type	EEG	MRI finding	Development status	Neurological examination	Family history
1	Boy	8	Clonic	Specific abnormal	Normal	Normal	Normal	Negative
2	Boy	3	Focal-clonic	Borderline	Specific abnormal	Abnormal	Normal	Positive
3	Boy	5	Focal-clonic	Specific abnormal	Accidental abnormal	Normal	Normal	Negative
4	Boy	6	Focal-clonic	Specific abnormal	Normal	Abnormal	Normal	Positive
5	Boy	10	TCG	Borderline	Normal	Normal	Abnormal	Negative
6	Boy	1	TCG	Normal	Normal	Abnormal	Normal	Negative
7	Boy	9	TCG	Specific abnormal	Normal	Abnormal	Normal	Negative
8	Boy	11	TCG	Specific abnormal	Normal	Normal	Normal	Positive
9	Boy	8	TCG	Specific abnormal	Specific abnormal	Normal	Normal	Negative
10	Boy	8	Tonic	Normal	Normal	Abnormal	Normal	Negative
11	Boy	7	Tonic	Normal	Normal	Normal	Abnormal	Negative
12	Boy	14	Tonic	Specific abnormal	Accidental abnormal	Normal	Abnormal	Negative
13	Boy	3	Tonic	Specific abnormal	Normal	Normal	Normal	Negative
14	Boy	6	Tonic	Specific abnormal	Normal	Normal	Normal	Negative
15	Boy	10	Tonic	Specific abnormal	Normal	Normal	Normal	Positive
16	Girl	4	Focal-clonic	Specific abnormal	Normal	Normal	Normal	Negative
17	Girl	8	TCG	Specific abnormal	Accidental abnormal	Abnormal	Normal	Negative
18	Girl	5	TCG	Specific abnormal	Normal	Normal	Normal	Negative
19	Girl	4	TCG	Specific abnormal	Normal	Normal	Normal	Negative
20	Girl	12	Tonic	Specific abnormal	Normal	Normal	Normal	Negative
21	Girl	10	Tonic	Specific abnormal	Normal	Normal	Normal	Negative
22	Girl	9	Tonic	Specific abnormal	Specific abnormal	Abnormal	Abnormal	Negative

TCG: Tonic clonic generalized

Table 2: The relationship between MRI findings with ECG results, neurological examination, developmental status and family history of first unprovoked seizure in child patients

Variable	Total (n=56)	MRI findings		P-value
		Normal or non-specific (n=53)	Abnormal (n=3)	
Number (%)				
Gender				
Boy	28 (50)	26(49.1)	2(66.7)	1.0
Girl	28 (50)	27(50.9)	1(33.3)	
Family history of epilepsy				
No	52 (92.9)	50(94.3)	2(66.7)	0.203
Yes	4 (7.1)	3(5.7)	1(33.3)	
Neurological examination				
Normal	52 (92.9)	50 (94.3)	2 (66.7)	0.203
Abnormal	4 (7.1)	3(5.7)	1 (33.3)	
Development status				
Normal	49 (87.5)	48(90.5)	1(33.3)	0.038
Abnormal	7 (12.5)	5(9.5)	2(66.7)	
EEG				
Normal	25 (45.5)	25 (48.1)	0 (0.0)	0.155
Borderline	13 (23.6)	12 (23.1)	1 (33.3)	
Specific abnormal	17 (30.9)	15 (28.8)	2 (66.7)	

Table 3: The relationship between EEG findings with neurological examination, developmental status and family history of first unprovoked seizure in child patients

Variable	EEG findings			P-value
	Normal (n=25)	Borderline (n=13)	Abnormal (n=17)	
	Number (%)			
Family history of epilepsy				
No	25 (100)	12 (92.3)	14 (82.4)	0.070
Yes	0 (0.0)	1 (7.7)	3 (17.6)	
Neurological examination				
Normal	24 (96.0)	12 (92.3)	15 (88.2)	0.806
Abnormal	1 (4.0)	1 (7.7)	2 (11.8)	
Development status				
Normal	23 (92.0)	12 (92.3)	13 (76.5)	0.808
Abnormal	2 (8.0)	1 (7.7)	4 (23.5)	

positive criteria (7.32 ± 3.3 vs. 5.24 ± 4.1), and the difference was statistically significant ($P=0.041$). Also, the prevalence of at least one positive clinical sign or family history in boys was significantly higher than girls (53.6% vs. 25.0%; $P=0.029$).

Based on the findings, 38.2% and 61.8% of patients without any positive criteria for seizures ($n=34$) were boys and girls, respectively. The prevalence of tonic, generalized tonic-clonic, focal-clonic, and myoclonic seizures in patients without any positive criteria ($n=34$) was 47.1%, 38.2%, 11.8%, and 2.9%, respectively. There was no significant difference regarding the type of seizure between patients with and without the positive criteria ($P=0.746$). Table 1 presents the demographic characteristics, type of seizure, and clinical signs of patients with at least one positive clinical sign or family history.

A significant association was observed between the developmental status of children and MRI findings ($P=0.038$). However, MRI findings had no significant relationship with EEG findings, neurological results, or family history of patients (Table 2). Of 48 children with a normal developmental status, 35 children had normal EEG findings, and 13 children had abnormal EEG findings. Of seven children with developmental delay, four had abnormal EEG findings, and three had normal EEG findings. There was no significant association between EEG results and children's developmental status ($P=0.185$) or neurological examination ($P=0.580$). However, the prevalence of positive family history was higher in patients with abnormal EEG findings (17.6% vs. 2.6%), and the difference was marginally significant (Table 3).

DISCUSSION

The FUS is a seizure with no history or known precipitating cause, which may be due to an underlying neurological disease or a manifestation of epilepsy (10). The importance and value of brain

MRI in children with FUS who had referred to ED is under debate. The results of the current study revealed a significant relationship between the evolution status of children and abnormal MRI findings. This finding implies the importance of performing brain MRI in children with FUS who are presented to ED, especially in patients who are suspicious for evolution disorders.

In the current study, 16.1% of children had abnormal MRI results, 10.7% of whom had non-specific findings for seizure. According to previous studies on the value of MRI in FUS, the frequency of abnormal findings ranged between 10% and 33% (3-8), which is consistent with our results. In the present study, the prevalence of at least one positive clinical sign or family history was significantly higher in boys than girls, although the sex ratio of boys and girls was equal. It should be noted that in previous studies, the frequency of girls was higher than boys (10), and in some studies, the number of boy's was higher than girls (8).

In a study by Amirjalali et al. on 200 children with epilepsy, 196 children (98%) had abnormal EEG findings (9). In contrast, in our study, 25 (44.6%) children had normal findings, 17 (30.4%) children had abnormal findings, and 13 (23.2%) children had non-specific findings. The discrepancy between the findings can be attributed to the fact that Amirjalali et al. considered all non-specific EEG findings to be abnormal. Moreover, there was a referral error in their study, because they performed the study in a pediatric neurology clinic, while our study was performed in the ED of a general hospital. In the study by Amirjalali et al., 57 (28.5%) children had abnormal MRI findings, which included cerebral atrophy (10%), increased signal intensity of cerebral white matter (8%), benign cysts (5%), brain tumors (4%), and vascular abnormalities (1.5%). In contrast, in our study, 47 (83.9%) children had normal MRI findings, 6

(10.7%) children had non-specific findings, and 3 (5.4%) children had abnormal findings. It should be noted that in our study, random findings were isolated, and there was no referral error.

Furthermore, in a study by Sharma et al. (11) on 500 children with FUS (<16 years), imaging was carried out in 95% of cases (91% CT scan and 4% MRI). Overall, 9% of imaging findings were non-specific, while 8% were specific, which is somewhat similar to our study. In the study by Amirsalari et al., there was a significant relationship between abnormal MRI findings and abnormal EEG findings, age, positive family history of epilepsy, dysmorphic appearance, and physical examination. However, in our study, there was only a significant relationship between abnormal development and specific MRI findings for seizure. In fact, MRI alone could not detect an abnormality, which was negative in other clinical, neurological, or family history evaluations.

Limitations

This study had some limitations, including the low sample size, inaccuracies in collecting data from some records, and lack of MRI performance for some patients. In this study, brain MRI was interpreted by a radiologist and a neurologist, which increased the accuracy of MRI findings. Moreover, non-specific MRI findings were isolated from specific findings, thereby increasing the accuracy of our results. However, it is

recommended to conduct further multi-center, cohort studies on a larger sample size in the future.

CONCLUSIONS

Management of FUS patients based on clinical examinations in the ED setting, without imaging studies, may not be adequate. MRI alone could not detect abnormalities, which appeared normal in other clinical and neurological evaluations. According to our findings, it seems that brain MRI should be performed in FUS children with an abnormal developmental status.

ACKNOWLEDGEMENTS

None.

AUTHORS' CONTRIBUTION

Conception, design and supervision: N-AY, M-BT and F-A; Data collection and processing and literature review: M-BT, A-A and M-AA; Drafting the manuscript: N-AY, F-A, A-A and M-AA; Critical review: N-AY and F-A.

CONFLICT OF INTEREST

None declared.

FUNDING

None declared.

REFERENCES

1. Pressler RM, Robinson RO, Wilson GA, Binnie CD. Treatment of interictal epileptiform discharges can improve behavior in children with behavioral problems and epilepsy. *J Pediatr.* 2005;146(1):112-7.
2. Huff JS, Morris DL, Kothari RU, Gibbs MA, Emergency Medicine Seizure Study Group. Emergency department management of patients with seizures: a multicenter study. *Acad Emerg Med.* 2001;8(6):622-8.
3. Bluestein JS, Moshe SL. First unprovoked seizure. In: Maria BL, editor. *Currents in management in child neurology.* 3rd ed. Hamilton: BC Decker; 2005. p. 89-92.
4. Khodapanahandeh F, Hadizadeh H. Neuroimaging in children with first afebrile seizures: to order or not to order. *Arch Iran Med.* 2006;9(2):156-8.
5. Alawaneh H, Bataineh H. Urgent neuroimaging in children with first nonfebrile seizures. *Middle East J Fam Med.* 2008;6(1):24-6.
6. Shinnar S, O'Dell C, Mitnick R, Berg AT, Moshe SL. Neuroimaging abnormalities in children with an apparent first unprovoked seizure. *Epilepsy Res.* 2001;43(3):261-9.
7. Kalnin AJ, Fastenau PS, deGrauw TJ, Musick BS, Perkins SM, Johnson CS, et al. Magnetic resonance imaging findings in children with a first recognized seizure. *Pediatr Neurol.* 2008;39(6):404-14.
8. Mollamohammadi M, Tonekaboni SH, Khatami A, Azargashb E, Tavasoli A, Javadzadeh M, et al. Neuroimaging findings in first unprovoked seizures: A multicentric study in Tehran. *Iran J Child Neurol.* 2013;7(4):24-31.
9. Al-Shami R, Khair AM, Elseid M, Ibrahim K, Al-Ahmad A, Elsetouhy A, et al. Neuro-imaging evaluation after the first afebrile seizure in children: A retrospective observational study. *Seizure.* 2016;43:26-31.

10. Amirsalari S, Saburi A, Hadi R, Torkaman M, Beiraghdar F, Afsharpayman S, et al. Magnetic resonance imaging findings in epileptic children and its relation to clinical and demographic findings. *Acta Med Iran.* 2012;50(1):37-42.
11. Sharma S, Riviello JJ, Harper MB, Baskin MN. The role of emergent neuroimaging in children with new-onset afebrile seizures. *Pediatrics.* 2003;111(1):1-5.