

## Case Report

DOI: 10.22114/ajem.v0i0.340

## Spontaneous Rupture of Urinary Bladder Diagnosed by Bedside Ultrasound; a Case Report

Ateeq Ur. Rahaman\*, Al-Nuaimi Saad-Abdullah, Kumar Suresh

Department of Emergency Medicine, Hamad General Hospital, Doha, Qatar.

\*Corresponding author: Ateeq Ur. Rahaman; Email: drateeqrahaman@gmail.com

Published online: 2020-02-23

### Abstract

**Introduction:** Spontaneous rupture of the urinary bladder (SRUB) is rare condition. It is often difficult to diagnose particularly in busy emergency department (ED). SRUB is usually secondary to an underlying pathology, but in extremely rare condition, it can be idiopathic. Significant morbidity and mortality can result from a missed or delayed diagnosis.

**Case presentation:** We report a case of idiopathic SRUB in a young male presented with inability to pass urine and abdominal pain in the absence of prior trauma or alcohol intoxication. A bedside ultrasound was performed by the emergency physician (EP) to confirm his suspicion, which demonstrated free intra-peritoneal fluid. This expedited further workup and management. Emergency consultation to urologist on call was initiated, the diagnosis was confirmed by computed tomography (CT) scan and the patient was taken to the theatre.

**Conclusion:** We report this case as it is unique in presentation, very rare in occurrence and bedside US had expedited further workup and management.

**Key words:** Emergency Service, Hospital; Rupture, Spontaneous; Ultrasonography; Urinary Bladder

**Cite this article as:** Rahaman AU, Saad-Abdullah AN, Suresh K. Spontaneous Rupture of Urinary Bladder Diagnosed by Bedside Ultrasound; a Case Report. Adv J Emerg Med. 2020;4(3):e80.

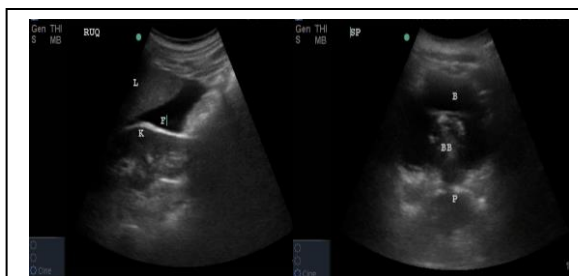### INTRODUCTION

Spontaneous rupture of the urinary bladder (SRUB) is a rare condition and is often secondary to an underlying pathology (1). Cases of SRUB secondary to alcohol intoxication were reported uncommonly (2). Extremely rare cases were reported in literature as being idiopathic (3). The diagnosis of SRUB often difficult and mandating a high index of suspicion as the patients might be presented with nonspecific symptoms adding more challenges to emergency department (ED) physician in the diagnosis and subsequent urgent management. However bedside ultrasound can be useful in expediting the diagnosis and management (4). Here, we report a case of idiopathic SRUB in a young male presented with inability to pass urine and abdominal pain in the absence of prior trauma or alcohol intoxication.

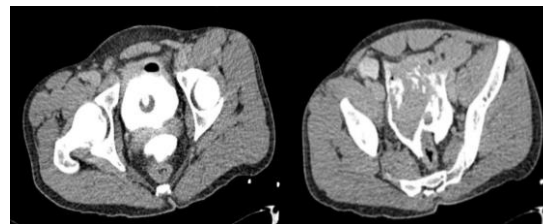
### CASE PRESENTATION

A 27-year-old male patient presented to the ED of Hamad general hospital, Doha, Qatar with inability to pass urine since last night associated with abdominal pain. The pain initially started in suprapubic region, and then became generalized all over the abdomen hours later. There were not any other symptoms and no history of previous abdominal trauma. His past medical history was

unremarkable with no particular urinary symptoms. He is neither smoker nor alcoholic. On examination patient was conscious and oriented;



**Figure 1:** Left image: Bedside Ultrasound of abdomen revealed positive free fluid right upper quadrant. Right image: Bedside Ultrasound of abdomen post catheterization showed catheter bulb in the bladder and irregular bladder wall



**Figure 2:** Axial enhanced pelvic CT scan views of the patient revealed irregular bladder contour with contrast extravasation

**Table 1:** Demographic and clinical characteristics of idiopathic SRUB patients in different studies

Study	Age	Gender	Co-morbidity	Mortality
Al-Qassim et al. (3)	33	Female	No	No
Wieloch et al. (10)	84	Female	Hypertension with atrial fibrillation	Yes
Uysal E et al. (11)	78	Female	Hypertension	Yes
Albino G et al. (12)	73	Male	No	Yes
Cusano et al. (13)	60	Female	No	No
Limon et al. (14)	52	Female	Diabetes mellitus	Yes
Current	27	Male	No	No

however, he was in severe distress and diaphoretic. Initial vital signs were as follow: heart rate=154/min, respiratory rate=26/min; blood pressure=156/98mmHg, O<sub>2</sub>saturation=99% on room air and auxiliary temperature=36.6°C. Abdominal examination revealed soft abdomen with diffuse tenderness all over with audible bowel sounds. Bedside ultrasound showed positive free intra-peritoneal fluid (figure 1). Urinary catheter (G14) was inserted which revealed frank haematuria. Blood tests showed Hgb=15g/dL, white blood cell (WBC) count=22.6X10<sup>3</sup>/uL, Neutrophil=19.4X10<sup>3</sup>/uL, Urea=6.4mmol/L, sodium level=116 mmol/L. A provisional diagnosis of rupture bladder was made with emergency consultation to urologist on-call. Emergency contrast-enhanced abdominopelvic computed tomography (CT) scan was ordered. It showed intra-peritoneal bladder rupture with moderate intra-peritoneal fluid and pelvic hematoma (figure 2). Patient was shifted to theater for emergency laparotomy. Operative notes mentioned that 2 liters of urine, blood and clots were evacuated upon opening the peritoneum. Bladder tear was noticed at the dome around 5 to 6 cm in length which was closed. Postoperatively patient was admitted to intensive care unit (ICU). He was found to have hyponatremia which improved gradually over 48 hours from 116 to 134 mmol/L. Patient had good amount of urine out, urine was clear, so urinary catheter was removed on 2<sup>nd</sup> postoperative day. His condition was progressed uneventfully and discharged home 3 days later with urology outpatient follow up in one week.

## DISCUSSION

SRUB is often secondary to an underlying pathology. Multiple pathological conditions had been reported to predispose to SRUB, including pregnancy and labour, alcohol intoxication, neurogenic bladder secondary to Tabes Dorsalis,

## REFERENCES

1. Ahmed J, Mallick IH, Ahmad SM. Rupture of urinary bladder: a case report and review of literature. Cases J. 2009; 2: 7004.

invasive tumour to bladder wall, gonococcal infection, and chronic outlet obstruction with urinary retention (2, 5-9). However, SRUB is a very rare life-threatening clinical condition. It is not always possible to diagnose by radiological imaging (10). Small number of cases had been reported in literature summarized in table 1 (11). It is likely that, bedside ultrasound is a useful diagnostic tool during the initial assessment of the patient with nonspecific abdominal pain even without history of trauma. Any free intra-peritoneal fluid observed in views of the right and left upper quadrants, or pelvic view should raise the suspicion of bladder rupture in appropriate clinical context (4, 15, 16). Additional research on the sensitivity and specificity of bedside ultrasound for bladder rupture is still needed.

## CONCLUSIONS

We recommend that although SRUB is a rare diagnosis, emergency physicians should consider it in the differential diagnosis of any patient with nonspecific abdominal pain in appropriate clinical context. Bedside ultrasound is a useful tool in initial assessment of such patients that may expedite patient management.

## ACKNOWLEDGEMENTS

None.

## AUTHORS' CONTRIBUTION

All the authors fulfil the criteria of authorship based on the recommendations of the International Committee of Medical Journal Editors (ICMJE).

## CONFLICT OF INTEREST

None declared

## FUNDING

None declared

2. Muneer M, Abdelrahman H, El-Menyar A, Zarour A, Awad A, Al-Thani H. Spontaneous atraumatic urinary bladder rupture secondary to alcohol intoxication: a case report and review of literature. *Am J Case Rep.* 2015;16:778-81.
3. Al-Qassim Z, Mohammed A, England R, Khan Z. Idiopathic spontaneous rupture of the urinary bladder (SRUB). A case report and review of literature. *Cent European J Urol.* 2012;65(4):235-7.
4. Daignault MC, Saul T, Lewiss RE. Bedside ultrasound diagnosis of atraumatic bladder rupture in an alcohol-intoxicated patient: a case report. *Crit Ultrasound J.* 2012;4(1):9.
5. Torpin R. Spontaneous rupture of the urinary bladder in labor case report literature and new Classification. *Urol Cutaneous Rev.* 1940;44:553-7.
6. Wilson L. Spontaneous rupture of the urinary bladder in a tabetic patient. *Med Bull Vet Admin.* 1940;17:93-5.
7. Stone E. Spontaneous bladder rupture. *Arch Surg.* 1931;23:129.
8. Falk HC, Hochman S. Rupture of pelvic inflammatory masses into the urinary bladder. *Am J Obst Gynec.* 1939;38(4):654-61.
9. Kivlin D, Ross C, Lester K, Metro M, Ginsberg P. A case series of spontaneous rupture of the urinary bladder. *Curr Urol.* 2015;8(1):53-6.
10. Wieloch M, Bazylińska K, Ziemniak P. Spontaneous, idiopathic urinary bladder perforation—case report. *Pol Przegl Chir.* 2013;85(12):727-9.
11. Dokur M, Ikidag MA, Kirdak T. Idiopathic spontaneous bladder perforation: a rare case. *Urol J.* 2015;12(2):2119-21.
12. Albino G, Bilardi F, Gattulli D, Maggi P, Corvasce A, Marucco EC. Spontaneous rupture of urinary bladder: a case report and review. *Arch Ital Urol Androl.* 2012;84(4):224-6.
13. Cusano A, Abarzua-Cabezas F, Meraney A. Spontaneous bladder perforation unrelated to trauma or surgery. *BMJ Case Rep.* 2014; 2014: bcr2014204161.
14. Limon O, Unluer EE, Unay FC, Oyar O, Sener A. An unusual cause of death: spontaneous urinary bladder perforation. *Am J Emerg Med.* 2012;30(9):2081.e3-5.
15. Wu TS, Pearson TC, Meiners S, Daugharthy J. Bedside ultrasound diagnosis of a traumatic bladder rupture. *J Emerg Med.* 2011;41(5):520-3.
16. Ford D, Palma J, Robinson J. Traumatic bladder rupture in a paratrooper. *Mil Med.* 2009;174(6):662-5.