



## Magnetic resonance spectroscopy in the management of tophaceous gout: A case report

Patricia Khashayar<sup>1</sup>, Hossein Ghanaati<sup>2</sup>,  
Seyed Mohammad Tavangar<sup>3</sup>, Bagher Larijani<sup>4</sup>

1 Osteoporosis Research Center, Endocrinology and Metabolism Research Institute, Tehran University of Medical Sciences, Tehran, Iran

2 Department of Radiology, Imam Khomeini Hospital, Tehran University of Medical Sciences, Tehran, Iran

3 Shariati Hospital, Tehran University of Medical Sciences, Tehran, Iran

4 Endocrinology and Metabolism Research Center, Endocrinology and Metabolism Research Institute, Tehran University of Medical Sciences, Tehran, Iran

### Abstract

Development of chronic tophaceous arthritis with marked joint impairment may follow repeated acute attacks. We present a 60 year-old man with huge urate deposits and severe gouty arthropathy with underlying hypothyroidism. During the past years, he had undergone several surgeries with different degrees of amputation to remove the tophus. Magnetic resonance spectroscopy (MRS) of foot finger revealed high peak of lactate, suggesting that high lactate levels is linked with chronic gout and frequent attacks. The patient was treated with levothyroxine along with gout medication, and his thyroid-stimulating hormone (TSH) and urate levels were soon normal, suggesting that the underlying hypothyroidism had aggravated his gout condition.

**KEYWORDS:** Gout, Urate, Magnetic Resonance Spectroscopy, Tophaceous Gout

### Case Report

**Date of submission:** 18 Nov 2013, **Date of acceptance:** 25 Jan 2014

**Citation:** Khashayar P, Ghanaati H, Tavangar SM, Larijani B. **Magnetic resonance spectroscopy in the management of tophaceous gout: A case report.** Chron Dis J 2015; 3(1): 31-6.

### Introduction

Gout is a metabolic disease that can manifest as acute arthritis or chronic arthropathy, which is also called tophaceous gout, and deposition of monosodium urate crystals in joint, bones, connective tissue, and kidneys.<sup>1,2</sup> All patients with gout have hyperuricemia at some point of their disease, and this elevated uric acid levels are linked with urate crystal formation, which is the underlying pathology for gout.<sup>3</sup>

Development of chronic tophaceous arthritis with marked joint impairment may follow repeated acute attacks and this might be aggravated with existing comorbidities such as thyroid problems. Some studies have shown that

untreated thyroid disorders may promote hyperuricemia as thyroid hormone increases serum urate levels through regulation of glomerular filtration rate.<sup>4</sup>

Many studies have shown that certain imaging techniques are useful in detecting urate deposition even prior to the first clinical symptoms, and thus, can be used to evaluate the extent of deposition and provide objective measurement of crystal depletion during urate-lowering treatment.<sup>5</sup> Magnetic resonance spectroscopy (MRS), however, has never been used in this regard. We present a patient with huge urate deposits and severe gouty arthropathy resistant to treatment.

### Case Report

A 60-year-old man came to our attention as a

### Corresponding Author:

Bagher Larijani,

Email: emrc@tums.ac.ir

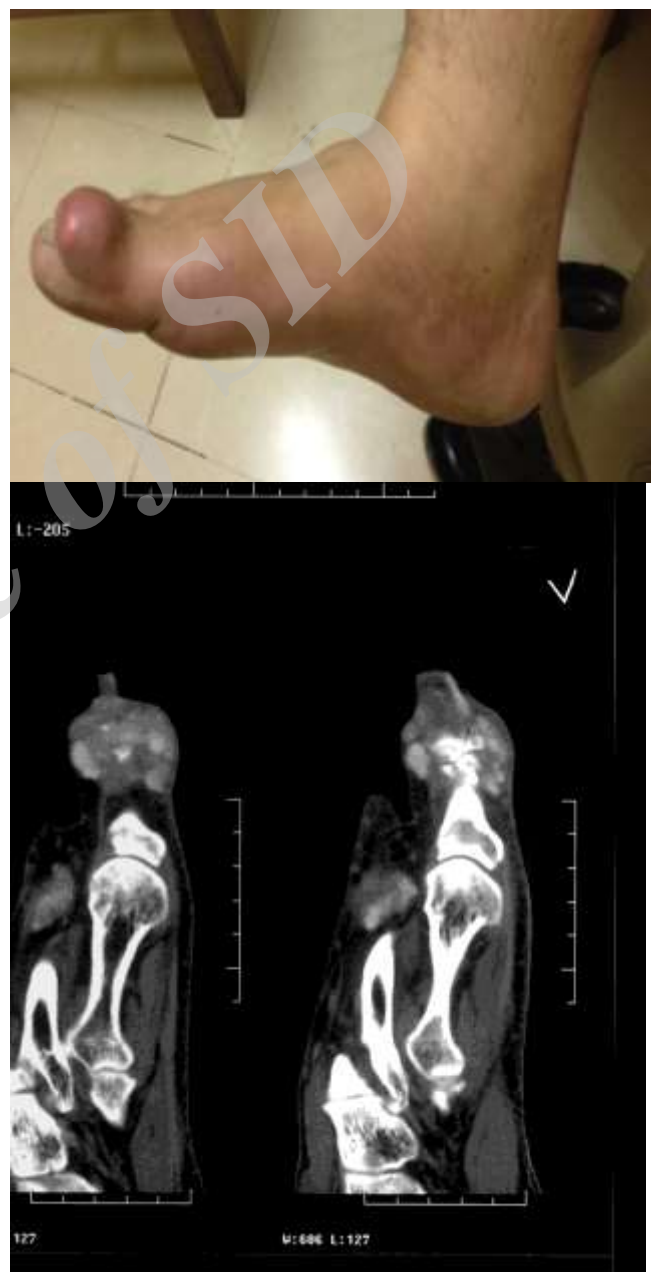resistant case of tophaceous gout. He had been diagnosed with gout several years ago and had been treated with allopurinol 100 mg/day and colchicine 0.5 mg/day for a long time. On laboratory examination, slightly elevated uric acid (10.6 mg/l) was attributed to untreated hypothyroidism. In addition to hypothyroidism, he had a positive history of ischemic heart disease and mild hypertension. Cardiac stress test had revealed mild stress-induced ischemia in apex. He had a normal left ventricular ejection fraction of 50% associated with trivial mitral and tricuspid regurgitation in echocardiography. Coronary angiography detected one-vessel disease (1-VD). He was, thus, treated with various anti-hypertensive drugs.

During the course of many years, he has had multiple acute gout flares, resulting in the development of multiple tophi localized to his feet. He had undergone several surgeries because of these tophi, which resulted in the amputation of his right big toe. As for his left foot, similarly, the tophus located on the lateral malleolus was excised. In a recent surgery, a tophus on the dorsal aspect of the extensor tendon extended to the plantar surface was excised as possible. The very tophus had caused erosion of second to fifth metatarsal bones to some extent; however, none of them were fractured.

He was noted to have a multilobular, solid, tender, enlarged subcutaneous nodule of the distal metatarsal of right big toe, causing severe deformation (Figure 1). There was also a small tophus on his right ear. The tophus on the big toe had progressively increased in size and had limited his movements to the point that he could barely walk unaided. He was told that at this stage no medication or surgery could help him. Physical examination disclosed an obese man, with no goiter, and marked deformities of feet.

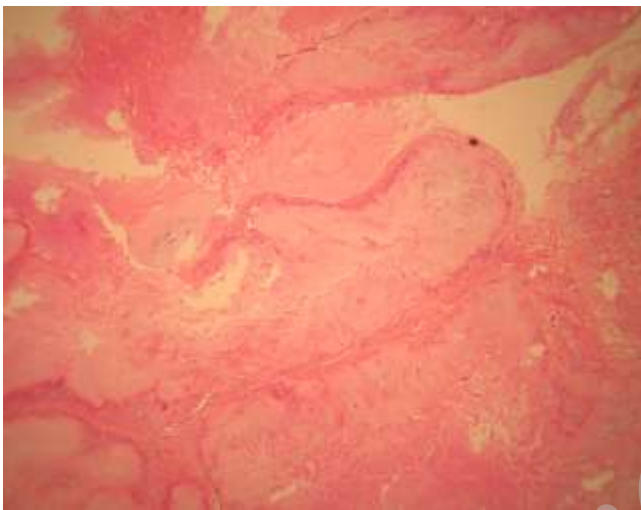
Laboratory evaluation revealed a serum uric acid level of 10.6 mg/dl. Erythrocyte sedimentation rate had increased to 37 mm/h. Serum creatinine was 1.36 mg/dl and fasting blood sugar was 107 mg/dl. Urinary protein was

2.28 g/day. Thyroid-stimulating hormone (TSH) was 40.1  $\mu$ UI/ml, T4 and T3 were 1.7 ng/dl and 0.7 pg/ml, respectively. Liver function test was also performed, and the results were unremarkable. Kidney ultrasound and cardiac echocardiography did not identify any uric acid deposition.



**Figure 1. Multilobular, solid, tender, enlarged subcutaneous nodule of the distal metatarsal of right big toe (a) X-ray (b)**

Considering the unusual size of the tophus and its resistant nature, diagnostic arthrocentesis was performed and yielded white, chalky particulate material. Light microscopy of Hematoxylin and Eosin-stained smears disclosed amorphous material (urate crystals) surrounded by inflammatory giant cells on histopathologic examination (Figure 2). Calcium-containing compounds or apatite crystals were not found.



**Figure 2. Hematoxylin and eosin-stained smears disclosed amorphous material (urate crystals) surrounded by inflammatory giant cells on histopathologic examination**

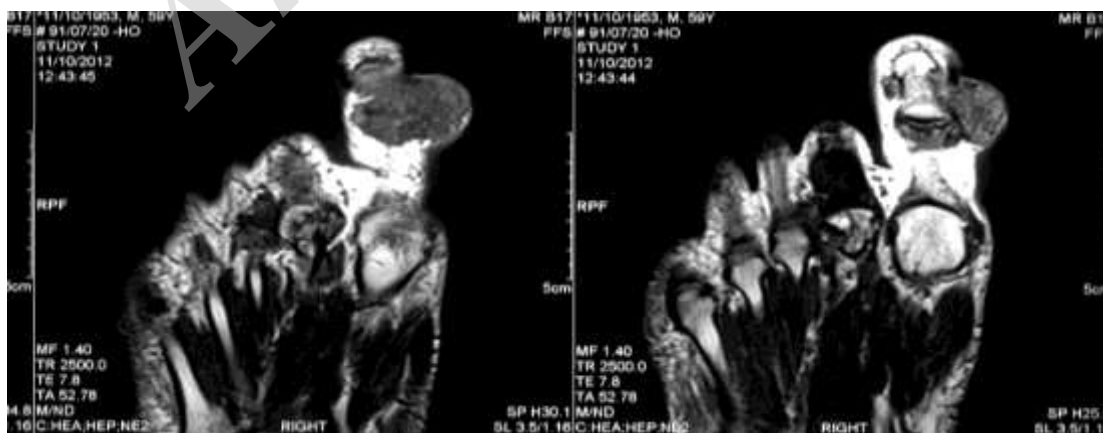
The radiographic examination of the feet showed eccentric soft tissue thickening in the absence of any calcifications or ossifications and

well-defined intra- and extra-articular bone destruction. The first metatarsophalangeal joints of the feet seemed to have disappeared. Tars metatarsal joints of the third, fourth, and fifth rays were also destroyed.

These findings led to magnetic resonance imaging (MRI) studies, obtained with a 1.5 T magnetom (Siemens, Munich, Bavaria, Germany), which revealed a well-defined soft tissue abnormality of intermediate signal on T1 weighting and of intermediate to low intensity on T2 weighting (Figure 3). In the obtained images, there was soft tissue expansion containing tiny calcified tophi adjacent to distal phalanx of toe without evident bony destruction. On the obtained multiplanar MR images of right foot, there was soft tissue expansion with low signal in T1 and high signal in T2 weighted images without evident phalangeal destruction.

The MRS of toe revealed high peak of lactate in the 1 ppm region of curve (Figure 4). Cho-Cr and NAA levels were in normal range.

Due to his huge urate deposits, allopurinol dose was gradually increased to 200 mg/day with prophylactic colchicine. Low dose indomethacin was also prescribed to reduce marked joint inflammation. He was initially treated with thyroid hormone (25 µg/day), which was gradually increased to 200 µg/day, based on TSH levels. As a result, serum TSH and urate progressively decreased to normal levels.



**Figure 3. Magnetic resonance imaging (MRI) of right foot**

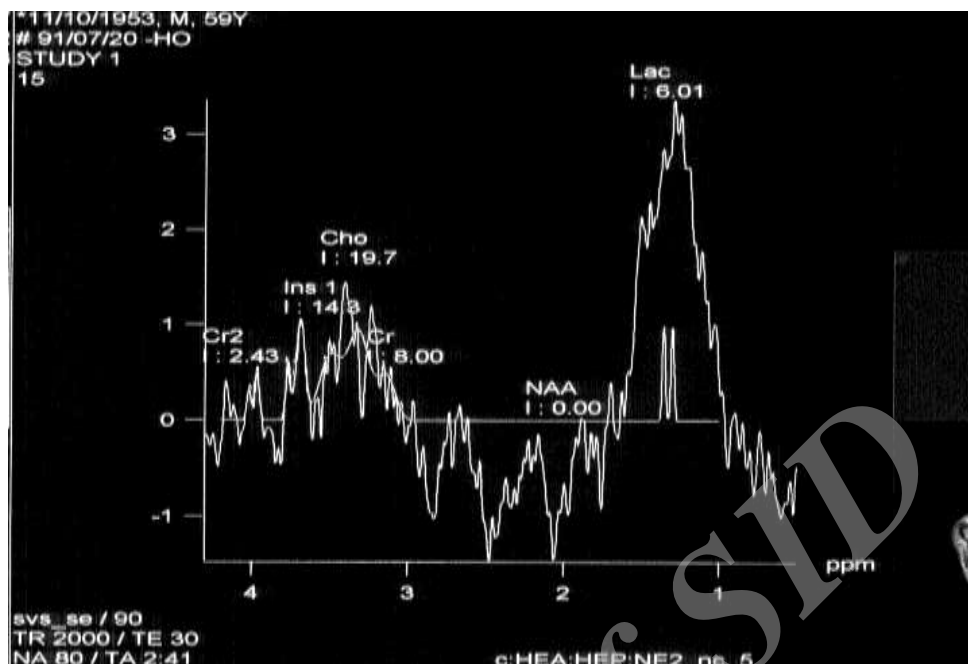


Figure 4. Magnetic resonance imaging (MRS) of right toe

## Discussion

Gout, one of the several crystal arthritides, is caused by persistent chronic hyperuricemia. It is characterized clinically by relapsing and remitting attacks of joint pain and swelling, usually monoarticular, and monosodium urate crystal deposition (tophi), typically found in and around joints on fingers, toes, wrists, and knees, on the olecranon bursae, on the Achilles tendons and rarely on the helix of the ears, the sclerae, subconjunctivally, and on the cardiac valves.<sup>6-8</sup>

The development of these chalky-appearing tophaceous deposits generally occurs several months to years after the episodic arthritic attacks and may not be recognized by the patient as soft-tissue tophi and may be painless and nontender.<sup>9</sup>

Gout can coexist with many diseases such as thyroid problems.<sup>10</sup> Both hyperthyroidism and hypothyroid states are reported to be associated with gout and hyperuricemia.<sup>11</sup> Many studies have linked long-standing hypothyroidism with several biochemical abnormalities, including increased serum creatinine and uric acid levels.<sup>12</sup> Hyperuricemia, in these cases, is believed to be

secondary to increased production due to myopathy associated with hypothyroidism or decreased renal plasma flow and impaired glomerular filtration.<sup>13</sup> High TSH levels were similarly a complicating factor in our patient. In our patient, similarly, treating the underlying hypothyroidism was associated with reduced uric acid levels (serum uric acid = 9.4 mg/dl; urine uric acid = 250  $\mu$ mol/l). This illustrates the need to screen patients with gout and even asymptomatic hyperuricemia and joint pain for underlying hypothyroidism.

Generally, the clinical diagnosis of gouty tophus is easily rendered, even in the absence of pathologic material, if the classic clinical and radiologic features are present. Fine-needle aspiration biopsy (FNAB) can be extremely helpful and yield diagnostic findings in distinguishing gout from pseudogout. Polarizing microscopy using red filter is, therefore, necessary to establish a correct diagnosis.<sup>14</sup> Histopathologic studies, on the other hand, show aggregates of urate crystals with surrounding macrophages, lymphocytes, and giant cells.<sup>15</sup>

The radiographic features of gouty arthritis



including soft tissue swelling, bony erosion, and solid soft tissue masses (tophi) are not entirely specific and may be seen in a variety of benign and malignant disorders.<sup>16,17</sup> Calcifications as well as ossification may be present.

Traditionally, tophi was detected and monitored by palpation, or by standard radiography or ultrasonography. Reports suggest that radiography may underestimate the size of and extent of soft tissue and osseous tophi, while a recent ultrasonography study characterized tophi as compared to nodules or lipomas and cysts.<sup>18,19</sup> MRI has been shown to be a more sensitive, accurate, and reproducible technique to measure tophus volume and consequently monitor the efficacy of long-term urate-lowering therapy in patients with tophaceous gout.<sup>20,21</sup>

Although the evaluation of tophi using FNAB, CT-scan, ultrasound, and MRI has been described as a potential diagnostic aid, to our knowledge, there is no report of MRS in this regard. MRS is a noninvasive diagnostic test for measuring biochemical changes in different tissues. While MRI identifies the anatomical location of a mass, MRS compares the chemical composition of normal tissue with abnormal tissue. This test can also be used to detect tissue changes in different diseases. There are several different metabolites or products of metabolism that can be measured to detect the chemical composition of a tissue; amino acids, lipid, lactate, alanine, n-acetylaspartate (NAA), choline, creatinine, and myo-inositol. Choline (Cho) is the precursor to acetylcholine and cell membrane components. In MRS, it is a marker of cellular membrane turnover and is, therefore, elevated in neoplasms, demyelination, and gliosis. Creatinine (Cr), which is commonly found in metabolically active tissues (brain, muscle, heart), is important in storage and transfer of energy. The creatinine level tends to be maintained at a relatively constant level, and thus, is predominantly used as a convenient internal standard. NAA is an acetylated amino acid which is found in high concentrations in

neurons and is a marker of neuronal viability. The reduced NAA levels show the processes that destroy neurons. Lactate (Lac) is the marker of anaerobic metabolism (no peak is seen in normal spectra). It is, therefore, elevated in necrotic areas, infections, and inflammatory infiltrates. The high lactate peak in our patient illustrates the inflammatory nature of the mass.

### Conflict of Interests

Authors have no conflict of interests.

### Acknowledgments

We would like to thank the patient for their cooperation in the study.

### References

1. Dhoble A, Balakrishnan V, Smith R. Chronic tophaceous gout presenting as acute arthritis during an acute illness: a case report. *Cases J* 2008; 1(1): 238.
2. Logan JA, Morrison E, McGill PE. Serum uric acid in acute gout. *Ann Rheum Dis* 1997; 56(11): 696-7.
3. Mikuls TR, Saag KG. New insights into gout epidemiology. *Curr Opin Rheumatol* 2006; 18(2): 199-203.
4. Mariani LH, Berns JS. The renal manifestations of thyroid disease. *J Am Soc Nephrol* 2012; 23(1): 22-6.
5. Perez-Ruiz F, Dalbeth N, Bardin T. A review of uric acid, crystal deposition disease, and gout. *Adv Ther* 2015; 32(1): 31-41.
6. Falidas E, Rallis E, Bournia VK, Mathioulakis S, Pavlakis E, Villias C. Multiarticular chronic tophaceous gout with severe and multiple ulcerations: a case report. *J Med Case Rep* 2011; 5: 397.
7. Sarma P, Das D, Deka P, Deka AC. Subconjunctival urate crystals: a case report. *Cornea* 2010; 29(7): 830-2.
8. Iacobellis G, Iacobellis G. A rare and asymptomatic case of mitral valve tophus associated with severe gouty tophaceous arthritis. *J Endocrinol Invest* 2004; 27(10): 965-6.
9. Neogi T. Clinical practice. Gout. *N Engl J Med* 2011; 364(5): 443-52.
10. Forbess LJ, Fields TR. The broad spectrum of urate crystal deposition: unusual presentations of gouty tophi. *Semin Arthritis Rheum* 2012; 42(2): 146-54.
11. See LC, Kuo CF, Yu KH, Luo SF, Chou IJ, Ko YS, et al. Hyperthyroid and hypothyroid status was strongly associated with gout and weakly associated with hyperuricaemia. *PLoS One* 2014; 9(12): e114579.

12. Khan AH, Majumder I, Hoque M, Forhadul F, Mollah H, Arslan I. Serum Creatinine and Uric Acid Levels in Hypothyroid Patients: A Cross Sectional Study. *J Enam Med Col* 2013; 3(2): 84-7.
13. Giordano N, Santacroce C, Mattii G, Geraci S, Amendola A, Gennari C. Hyperuricemia and gout in thyroid endocrine disorders. *Clin Exp Rheumatol* 2001; 19(6): 661-5.
14. Shidham V, Chivukula M, Basir Z, Shidham G. Evaluation of crystals in formalin-fixed, paraffin-embedded tissue sections for the differential diagnosis of pseudogout, gout, and tumoral calcinosis. *Mod Pathol* 2001; 14(8): 806-10.
15. Shidham V, Shidham G. Staining method to demonstrate urate crystals in formalin-fixed, paraffin-embedded tissue sections. *Arch Pathol Lab Med* 2000; 124(5): 774-6.
16. Peh WC. Tophaceous gout. *Am J Orthop (Belle Mead NJ)* 2001; 30(8): 665.
17. Gentili A. Advanced imaging of gout. *Semin Musculoskelet Radiol* 2003; 7(3): 165-74.
18. Schueller-Weidekamm C, Schueller G, Aringer M, Weber M, Kainberger F. Impact of sonography in gouty arthritis: comparison with conventional radiography, clinical examination, and laboratory findings. *Eur J Radiol* 2007; 62(3): 437-43.
19. Thiele R, Schlesinger N. Ultrasonography is a reliable, non-invasive method for diagnosing gout. *Arthritis Rheum* 2005; 52(suppl 9): S809.
20. Schlesinger N. Diagnosis of gout: clinical, laboratory, and radiologic findings. *Am J Manag Care* 2005; 11(15 Suppl): S443-S450.
21. Schumacher HR, Jr., Becker MA, Edwards NL, Palmer WE, MacDonald PA, Palo W, et al. Magnetic resonance imaging in the quantitative assessment of gouty tophi. *Int J Clin Pract* 2006; 60(4): 408-14.