



Comparing the Diagnostic Accuracy of Two Different Resolutions of Radiographs Captured with PSP Digital Intraoral Receptors in Detection of Secondary Caries (In Vitro)

Mehralizade S¹, Nemati Anaraki S², Sakhdari S¹, Miraba S³, Bayat S⁴, Amiri Siavashani M^{4*}

¹Assistant Professor, Oral and Maxillofacial Radiology Dept, Dental Branch of Tehran, Islamic Azad University, Tehran, Iran.

²Assistant Professor, Restorative Dept, Dental Branch of Tehran, Islamic Azad University, Tehran, Iran.

³Dentist.

⁴Post Graduate Student, Oral and Maxillofacial Radiology Dept, Dental Branch of Tehran, Islamic Azad University, Tehran, Iran.

ARTICLE INFO

Article Type
Original Article

Article History

Received: April 2015

Accepted: August 2015

ePublished: January 2016

Keywords:

Dental Radiography

Digital Radiography

Diagnosis

Dental Caries

Composite resin

ABSTRACT

Background and Aim: Considering the importance of detection of secondary caries, the adverse consequences of false positive and false negative diagnoses and the gap of information in the diagnostic efficacy of digital sensors in detection of secondary caries, this in vitro study sought to compare the diagnostic efficacy of two different resolutions of radiographs obtained by photostimulable phosphor (PSP) plate intraoral sensors in detection of secondary caries in class II composite resin restorations using a standard technique.

Methods and Materials: This diagnostic study was conducted on 40 extracted human second premolars. A classic class II cavity was prepared on one proximal surface of each tooth and restored with composite resin. Intraoral digital radiographs were obtained and saved in High and Super resolutions. Secondary caries were artificially created using a round bur mounted on a high-speed handpiece, and the teeth were radiographed again. Radiographs were saved with the mentioned two resolutions. All the radiographs were evaluated by three observers. Caries detection was classified using the yes/no dichotomous scale and data were statistically analyzed using kappa coefficient.

Results: No significant differences were found in sensitivity, specificity, positive predictive value (PPV), negative predictive value (NPV) and accuracy of the two resolutions in caries detection ($P > 0.05$).

Conclusion: The High and Super resolutions of radiographs taken with digital intraoral PSP plates showed no significant differences in detection of artificially created secondary caries.

Please cite this paper as:

Mehralizade S, Nemati Anaraki S, Sakhdari S, Miraba S, Amiri Siavashani M, Bayat S. Comparing the Diagnostic Accuracy of Two Different Resolutions of Radiographs Captured with PSP Digital Intraoral Receptors in Detection of Secondary Caries (In Vitro). J Res Dentomaxillofac Sci.2016;1(1):40-44.

*Corresponding author:

Mehdi Amiri Siavashani.

Tel: 22566471-3;

E-mail: Dr_mas7@yahoo.com

Introduction:

Secondary carious lesions are challenging for clinicians and often occur adjacent to an existing restoration due to microleakage, inadequate extension of the restoration's margins or insufficient caries removal.⁽¹⁾ Replacement of restorations due to the occurrence of secondary caries is among the most commonly performed clinical procedures in dentistry.⁽²⁾ Secondary caries were defined as reversible recurrence of caries at the margins of a restoration by GV Black.⁽³⁾ Currently, secondary caries are often detected through clinical examination in a clean and dry environment under adequate lighting by visual inspection and tactile sense of the clinician using the sharp tip of a dental explorer, by use of caries detectors and dental floss, or by radiography.⁽⁴⁾ According to the literature, 25-42% of carious lesions are missed during clinical examinations without the use of radiography.⁽⁵⁾ Consequently, replacement of restorations due to suspected secondary caries is often postponed until approved by radiography. However, controversy exists regarding the accuracy of the diagnoses based on radiography, and misinterpretations may occur due to the presence of radiolucent base and liner dental materials that resemble secondary caries.⁽¹⁾ Moreover, cervical burnouts and the Mach bands (the contrast between dark and light areas) in some regions can also result in diagnostic errors and misdiagnosis of caries.^(1,2,4) In some cases, radiopaque restorations mask the radiolucent dentinal caries.⁽⁵⁾ Optical resolution is defined as the ability of a sensor to reconstruct the details of the original model, and it depends on the quality of optics and sensors as well as the spatial density (number of pixels in a digital image).⁽⁶⁾ Spatial resolution is defined as the ability to detect fine details in an image. Spatial resolution is expressed in line pairs per millimeter. Cheng et al in 2012 reported that increasing the resolution of images directly affects the detection of proximal dentinal caries.⁽⁷⁾ Whereas, Haiter-Neto et al stated that enhancing the resolution has no effect on the detection of proximal or occlusal caries.⁽⁸⁾ Thus, the diagnostic efficacy of digital radiography in detection of secondary caries is a

matter of controversy.⁽⁹⁾ Consequently, this in vitro study sought to assess the diagnostic efficacy of two different resolutions of the radiographs obtained by PSP sensors in detection of secondary caries artificially created in class II composite restorations compared to the gold standard.⁽¹⁰⁾

Methods and Materials:

In this diagnostic In vitro study, the sample size was calculated to be 40 teeth according to previous diagnostic studies.⁽¹¹⁾ Thus, 40 permanent premolars with no clinically visible cracks, caries or restorations were collected (age and sex of the patients and the reason for tooth extraction were not important). The teeth were disinfected with 0.1% thymol solution. Radiographs were obtained before and after creating the artificial secondary caries. Class II cavities with the dimensions of 1.25×2.5×3mm (axial depth of the gingival wall, occlusogingival width, mesiodistal width, respectively)⁽¹²⁾ were prepared using a 008 bur (D & Z, Switzerland) mounted on a high-speed handpiece (Kavo, Brazil) and were restored with composite resin (P60, 3M ESPE, St. Paul, MN, USA). First, the prepared cavity was dried and isolated. Afterwards, the cavity was etched with 37% phosphoric acid for 15 seconds, rinsed for 30 seconds and dried. Two layers of bonding agent (Single Bond, 3M, ESPE, St. Paul, MN, USA) were applied using a microbrush and were light cured for 10 seconds with LED light-curing unit (Starlight Pro; Mectron SpA, Carasco, Italy). Composite resin was applied incrementally and each layer was cured for 40 seconds. The restoration was then finished using flame-shaped composite finishing burs (D&Z, Switzerland) and was polished with paper discs.

Radiographing the teeth:

Digital radiographs were obtained using PSP plate sensors (Orion Crop #2, Soredex, Digora@Optime, Helsinki, Finland) with the exposure settings of 70 kVp, 0.3 seconds and 8mA. The sensor-tooth distance was 1cm and the distance from the X-ray tube to the sensor equaled 20cm. This distance was adjusted using a Kerr sensor holder (Kerr, USA). The teeth were posi-

tioned in the dental sockets of a dry human skull. The X-ray tube was adjusted at zero-degree faciolingual angle. Radiographs were saved with two different resolutions of High and Super (High resolution: 675×1350 pixels, image size=40Mm 1078MB capacity, Super resolution: 844×422 pixels, image size=64Mm 695KB capacity) using SCANORA Lite Viewer software (Soredex, Finland).⁽¹²⁾

Simulating the secondary caries:

After obtaining the primary radiographs, secondary caries were artificially created using #1 round bur (D&Z) and a high-speed handpiece with 1mm depth in the gingival wall at the cementoenamel junction, in a way that the prepared cavity did not extend to the margins of the restoration. This cavity was filled with red wax.⁽¹⁰⁾ (Figure 1)

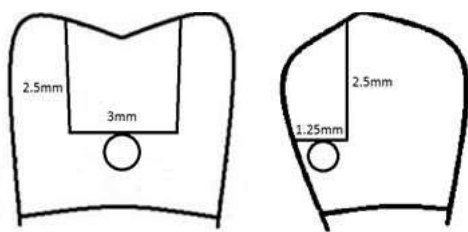


Fig. 1. The illustration shows the artificial caries prepared in the gingival floor and sealed with red wax.

Obtaining radiographs from the simulated secondary caries:

The samples were radiographed again using PSP plate sensor with the same exposure settings.

Observation and assessment of the radiographs: Three observers including two oral and maxillofacial radiologists and a specialist in restorative dentistry⁽¹⁴⁾ observed the radiographs in PowerPoint software (Microsoft office 2010, NK, USA)⁽¹⁵⁾ on a 15-inch monitor (TOSHIBA, Japan) in a semi-dark room. The observer-monitor distance was 20-30cm. No time limit was set for observation. Observers viewed the radiographs randomly and recorded their opinions in a data sheet using the yes/no dichotomous scale.

Kappa statistics were computed to assess the intra- and inter-rater agreement and the results were analyzed using the correlation tests. Diagnostic parameters including the sensitivity, specificity,

PPV, NPV and accuracy were separately calculated and analyzed for each method.

Results:

The present study was conducted on 40 teeth and 160 radiographs. Kappa statistics revealed no difference between High and Super resolutions considering the intra- and inter-examiner reliability of the three observers (P=1). The intra- and inter-observer agreement coefficient was 1 for both resolutions. Table 1 presents the sensitivity, specificity, PPV, NPV and accuracy for the two resolutions.

Table 1- . Sensitivity, Specificity, PPV, NPV and Accuracy of High and Super resolution images

Resolution	Sensitivity	Specificity	PPV	NPV	Accuracy
High	0.9	0.92	0.92	0.9	0.91
Super	0.9	0.97	0.97	0.9	0.93
P value	=1	=0.4	=0.4	=0.9	=0.5

No difference in sensitivity was found between the two resolutions (P=1). The Super resolution showed the highest specificity, PPV, NPV and accuracy, but Chi-square test showed that the differences were not significant. The statistical power of the test was 0.06-0.16. Overall, no significant differences were found between the two resolutions in detection of secondary caries.

Discussion:

The Super resolution showed slightly (but not significantly) higher values than the High resolution, and since sensitivity is more important than specificity in detection of secondary caries, this finding is worthy of consideration and might be of clinical significance.

Few articles have assessed the efficacy of two different image resolutions in detection of secondary caries. Thus, we discuss other relevant factors reported in the literature. Cheng et al compared cone beam computed tomography (CBCT) scans (Promax 3D, DCT Pro scanner) with three different resolutions of high, normal and low with digital images captured by PSP sensor. They showed that different resolutions of

CBCT scans had no significant effect on caries detection ($P=0.989$), but a significant difference was noted in the detection of dentinal caries between PSP plates and CBCT ($P<0.001$).⁽⁷⁾ Their results regarding the different resolutions were comparatively in accordance with our findings. Hellen-Halme evaluated the effect of two different voltages on the detection of proximal caries. No significant differences were noted between 60 and 70 kV in detection of proximal caries.⁽¹⁶⁾ Therefore, it seems that the exposure settings of radiographic units such as voltage or the image resolution have no significant effect on caries detection. Haiter-Neto et al compared original and enhanced (Fine, Caries1, and Caries2 filters) PSP digital radiographs and showed that the Fine filter was not significantly different from the original radiographs in terms of sensitivity, specificity and accuracy, which is in line with our findings. However, the Fine filter showed the highest sensitivity in a narrow range. Also, the Fine filter had significantly higher sensitivity and specificity than Caries 1 and Caries 2 modalities.⁽¹⁷⁾ Nair et al, compared conventional films with PSP and CCD digital sensors in detection of secondary caries and showed that unenhanced PSP radiographs yielded the worst and CCD and enhanced PSP images yielded the best results.⁽¹⁸⁾ Another study compared intraoral film-based radiography, digital radiography and unprocessed, iteratively restored tuned aperture computed tomography (TACT) images in diagnosis of secondary caries, and showed that iteratively restored TACT images yielded the best results in terms of sensitivity (82.50) and specificity (96.25).⁽¹⁹⁾ Haiter-Neto et al compared the diagnostic accuracy of CBCT (NewTom, Accuitomo) with that of intraoral film-based and digital radiography and found no significant differences among the different resolutions of NewTom CBCT in terms of sensitivity and specificity, which concurs with our findings.⁽⁷⁾ Ilguy et al assessed the detection of secondary decay on digital PSP and conventional radiographs using two types of LCD monitors, and showed that the radiographs displayed on the conventional monitor had the poorest and PSP images

displayed on a medical monitor had the highest diagnostic value.⁽²⁰⁾ Prapayastok et al assessed different resolutions of digital camera for detection of proximal caries and found no significant differences among the different resolutions.⁽²¹⁾ Overall, it may be concluded that variables such as voltage and different resolutions of radiographic units do not significantly affect the detection of caries by different observers; but some studies show that significant differences may be found between different radiography systems such as CBCT, CCD and PSP in caries detection. Perhaps, the two studied resolutions are physically similar and the human eye would not be able to perceive their difference; which explains the clinically insignificant differences between these two resolutions. However, the High resolution showed slightly but not significantly higher values compared to the Super resolution, and since sensitivity is more important than specificity in detection of secondary caries, this finding is worth considering. Furthermore, Super resolution images occupy less space than High resolution images and thus they can be more easily saved and transferred. Further evaluations are required to assess the efficacy of other options of radiographic units in detection of oral and dental conditions.

Conclusion:

No significant differences were found between High and Super resolution images captured with PSP plate sensors in detection of secondary caries.

Acknowledgments

The authors would like to thank the Dental research center of Tehran university of medical sciences and The AFM center of Iran university of science and Technology for the laboratory work.

Conflict of interests

Authors report no conflict of interest related to this study.

References:

1. Hintze H, Wenzel A, Danielsen B. Behaviour of approximal carious lesions assessed by clinical examination after tooth separation and radiography: a 2.5-year longitudinal study in young adults. *Caries Res* 1999;33(6):415-22.
2. Lachowski KM, Botta SB, Lascalea CA, Matos AB, Sobral MA. Study of the radio-opacity of base and liner dental materials using a digital radiography system. *Dentomaxillofac Radiol* 2013;42(2):20120153.
3. Mjör IA, Toffenetti F. Secondary caries: A literature review with case reports. *Quintessence Int* 2000;31(3):165-79.
4. Topping GVA, Pitts NB. International caries detection and assessment system committee. Clinical visual caries detection. *Monogr Oral Sci* 2009;21:15-41.
5. Haak R, Wicht MJ, Noack MJ. Conventional, digital and contrast-enhanced bite-wing radiographs in the decision to restore proximal carious lesions. *Caries Res* 2001;35(3):193-9.
6. Van der Stelt PF. Principles of digital imaging. *Dent Clin North Am* 2000;44(2):237-48.
7. Cheng JG, Zhang ZL, Wang XY, Zhang ZY, Ma XC, Li G: Detection accuracy of proximal Caries by phosphor plate and Cone – beam computerized tomography images Scanned with different resolutions. *Clin oral Investig* 2012;16(4):1015-21.
8. Haiter-Neto F, Wenzel A, Gotfredsen E. Diagnostic accuracy of cone beam computed tomography scans compared with intraoral image modalities for detection of caries lesions. *Dentomaxillofac Radiol* 2008;37(1):18-22.
9. Bahrami G; Hagström C; Wenzel A: bitewing examination with four digital receptor :dentomaxillofac Radiol 2003;32(5):317-21.
10. Goorabjavari NM, Talaeipour A, Ezoddini-Ardakani F, Safi Y, Shamloo N. Evaluation of Diagnostic Efficacy of Digital Subtraction Radiography in the Diagnosis of Simulated External Root Resorption: An In Vitro Study. *Health* 2015;7(4):439-48.
11. Charuakkra A, Prapayastok S, Janhom A, Pongsiriwet S, Verochana K, Mahasantiapiya P. Diagnostic performance of cone-beam computed tomography digiton detection of mechanically-created artificial secondary caries. *Imaging Sci Dent* 2011;41(4):143-50.
12. Moosavi H, Sadeghi S. Short-term evaluation of resin sealing and rebonding on amalgam microleakage: an SEM observation. *J Contemp Dent Pract* 2008;9(3):32-9.
13. Shahidi S, Zaeh NK, Sharafeddin F, Shahab S, Bahrampor E, Hamedani S. An in vitro comparison of diagnostic accuracy of cone beam computed tomography and phosphor storage plate to detect simulated occlusal secondary caries under amalgam restoration. *Dent Res J* 2015;12(2):161-6.
14. Alkurt MT, Peker I, Bala O, Altunkaynak B. In vitro comparison of four different dental X-ray films and direct digital radiography for proximal caries detection. *Oper Dent* 2007;32(5):504-9.
15. Kamburo lu K, Murat S, Yüksel SP, Cebeci AR, Paksoy CS. Occlusal caries detection by using a cone-beam CT with different voxel resolutions and a digital intraoral sensor. *Oral Surg Oral Med Oral Pathol Oral Radiol Endod* 2010;109(5):e63-9.
16. Hellén – Halme K. Effect of two X-ray tube voltages on detection of approximal caries in digital radiographs. An in vitro study. *Clin Oral Investig* 2011;15(2):209-13.
17. Haiter – Neto F, Casanova MS, Frydenberg M, Wenzel A. Task-specific enhancement filters in storage phosphor images from the Vistascan system for detection of proximal caries lesions of known size. *Oral Surg Oral Med Oral Pathol Oral Radiol Endod* 2009;107(1):116-21.
18. Nair MK, Ludlow JB, May KN, Nair UP, Johnson MP, Close JM. Diagnostic accuracy of intraoral film and direct digital images for detection of simulated recurrent decay. *Oper Dent* 2001;26(3):223-30
19. Nair Mk. Diagnostic accuracy of Tuned Aperture Computed Tomography (TACT). *Swed Dent J Suppl* 2003;(159):1-93.
20. Ilgüy M, Dinçer S, Ilgüy D, Bayirli G. Detection of artificial occlusal caries in a phosphor imaging plate system with two types of LCD monitors versus three different films. *J Digit Imaging* 2009;22(3):242-9.
21. Prapayastok S, Janhom A, Verochana K, Pramajanee S. Digital camera resolution and proximal caries detection. *Dentomaxillofac Radiol* 2006;35(4):253-7.