

Detection of Congenital Mullerian Anomalies by Real-time 3D Sonography

Firoozeh Ahmadi*, Hadiieh Haghighi

- Department of Reproductive Imaging, Reproductive Biomedicine Research Center, Royan Institute, ACECR, Tehran, Iran

Corresponding author: Firoozeh Ahmadi, Department of Reproductive Imaging, Reproductive Biomedicine Research Center, Royan Institute, ACECR, P.O. Box: 19395-4644, Tehran, Iran
E-mail: f_ahmadi@royaninstitute.org

Mullerian duct anomalies (MDAs) are relatively common disorders that are particularly responsible for obstetrical complications and have a prevalence of about 3%–4% in the general population (1, 2).

Uterine malformations may result from arrested development of the mullerian ducts, failure of fusion of the mullerian ducts or failure of resorption of the median septum (1, 2).

Several classification systems have been used to describe MDAs. The most accepted system is the American Fertility Society (AFS) classification system. This classification is based on the embryologic etiologies behind MDAs. In this classification, class I consist of hypoplasia and agenesis of the uterus. Class II consists of unicornuate uterus. Class III is composed of uterus didelphys and class IV is characterized by bicornuate uteri. Class V anomalies are made up of septate uterus. Class VI includes an arcuate uterus and class VII is diethylstilbestrol-related anomaly (3, 4).

Accurate characterization of MDAs is crucial to the treatment process. As a result, screening for uterine anomalies forms a part of routine clinical investigations of woman with a history of infertility, recurrent miscarriages and early preterm labors (5). Various imaging modalities have been used in the evaluation of MDAs. Despite being invasive, hysterosalpingography (HSG), hysteroscopy and laparoscopy are the conventional methods for the assessment of uterine morphology.

Technologic advances in imaging modalities have revolutionized the evaluation of MDAs by noninvasive tools such as two-dimensional (2D US) and three-dimensional ultrasounds (3DUS) and MRI.

Despite the fact that two-dimensional sono-

graphy is in routine use because of its flexibility and moderate costs, but it has some limitations. The sensitivity of 2DUS especially for the demonstration of fundal contour is relatively low compared with other methods (6). On the other hand, 3DUS is a valuable tool for the assessment of uterine morphology because of its increased spatial awareness and the ability to visualize the coronal plane. The coronal view depicts both endometrial cavity and the serosal surface of the

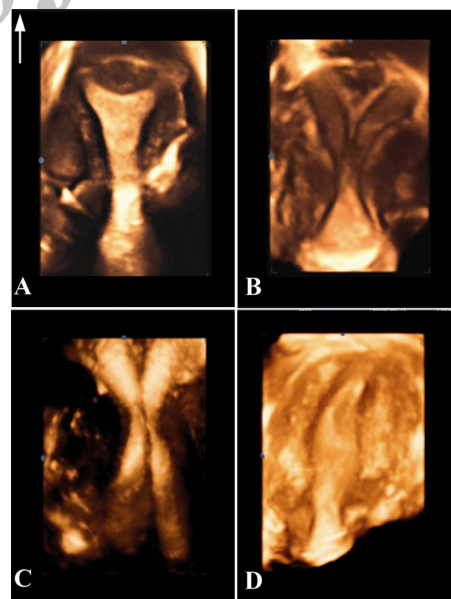


Figure 1. Three-dimensional sonography has become the gold standard tool for the diagnosis of congenital uterine anomalies; A: An arcuate uterus showing concave external uterine contour and smooth fundal indentation of the endometrial cavity. B: Incomplete septate uterus represents concave external contour with division of the uterine cavity (septum extending from the fundus to the lower part of uterine cavity). C: 3D image of a didelphys uterus illustrates duplication of endometrial cavities and cervical canals. D: 3D image of a unicornuate uterus shows a fusiform-shaped endometrial cavity

uterine fundus. Therefore, this view is a valuable problem-solving tool helping differentiate between various MDAs, including bicornuate, septate, unicornuate, and didelphys. Moreover, data acquisition time is short and images can be stored for later evaluation and analyzed as many times as needed (7).

In conclusion, endovaginal three-dimensional ultrasonography (3DUS) is a non-invasive, outpatient diagnostic modality, which enables a detailed assessment of the uterine morphology. Because of the high level of agreement between 3D ultrasonography and hysterosalpingography, MRI, hysteroscopy and laparoscopy, 3DUS has recently become the only mandatory step in the initial investigation of MDAs before resorting to invasive procedures such as hysteroscopy.

References

1. Salem S, Wilson SR. Gynecologic Ultrasound. In: Rumack CM, Wilson SR, Charboneau JW, editors. Diagnostic ultrasound, Vol. 1. Calgary: Elsevier; 2005. p. 527-87.
2. Raga F, Bauset C, Remohi J, Bonilla-Musoles F, Simón C, Pellicer A. Reproductive impact of congenital Müllerian anomalies. *Hum Reprod.* 1997;12(10):2277-81.
3. Troiano RN, McCarthy SM. Mullerian duct anomalies: imaging and clinical issues. *Radiology.* 2004; 233(1):19-34.
4. Deutch TD, Abuhamad AZ. The role of 3-dimensional ultrasonography and magnetic resonance imaging in the diagnosis of müllerian duct anomalies: a review of the literature. *J Ultrasound Med.* 2008;27(3):413-23.
5. Rai R, Clifford K, Regan L. The modern preventative treatment of recurrent miscarriage. *Br J Obstet Gynaecol.* 1996;103(2):106-10.
6. Caliskan E, Ozkan S, Cakiroglu Y, Sarisoy HT, Corakci A, Ozeren S. Diagnostic accuracy of real-time 3D sonography in the diagnosis of congenital Mullerian anomalies in high-risk patients with respect to the phase of the menstrual cycle. *J Clin Ultrasound.* 2010;38(3):123-7.
7. Dahiya N. Three-dimensional ultrasound: technique and applications revisited. *Ultrasound Clin.* 2009;4 (3):291-306.

Archive 03