

The Anti-fertility Effects of *Acacia nilotica* in Male Wistar Rats

Fanuel Lampiao *

- Department of Basic Medical Sciences, Division of Physiology, College of Medicine, Blantyre, Malawi

Abstract

Background: A bulk of contraceptives on the market is women-oriented today. The aim of this study was to investigate the effect of a medicinal herb, *Acacia nilotica* on various parameters of male fertility using a rat model.

Methods: Male Wistar rats (n=40) were randomly divided into two groups. One group received *Acacia nilotica*, while the other acted as controls. Ten animals from each group were sacrificed after 16 weeks. Treatment was withdrawn for the remaining animals for 8 weeks. Blood was collected for hormonal analysis. The testis was removed for histological examination, while epididymal spermatozoa were retrieved for motility and morphological analysis. The data were analyzed using ANOVA and Bonferroni post hoc test. A value of $p < 0.05$ was considered statistically significant.

Results: Sperm motility, progressive motility and sperm concentration significantly decreased in treated animals compared to the controls ($p < 0.05$). Withdrawing the treatment did not restore these parameters ($p < 0.05$). Abnormal sperm morphology significantly increased in both the treated and treatment withdrawn groups when compared to the controls ($p < 0.05$). Testosterone concentrations were significantly lower in the treated group when compared to the controls ($p < 0.05$) and no significant differences were observed between the controls and the treated animals when treatment was withdrawn. Histological observations showed that *Acacia nilotica* treatment disrupted semeniferous tubule architecture and consequently the spermatogenesis process.

Conclusion: These results show that *Acacia nilotica* severely affects sperm morphology, progressive motility and sperm concentration irreversibly in Wistar rats.

Keywords: *Acacia nilotica*, Contraceptives, Family planning, Fertility, Herbal medicines.

To cite this article: Lampiao F. The Anti-fertility Effects of *Acacia nilotica* in Male Wistar Rats. *J Reprod Infertil.* 2013;14(1):39-42.

* Corresponding Author:
Fanuel Lampiao, Department of Basic Medical Sciences, Division of Physiology, College of Medicine, P.O. Box 360, Blantyre 3, Malawi
E-mail:
flampiao@medcol.mw

Received: Aug. 8, 2012
Accepted: Oct. 21, 2012

Introduction

Population growth is a great concern worldwide. Therefore, numerous methods are being used to reduce the total fertility rate in both men and women, especially in developing countries. Overpopulation continues to be a significant contributor to environmental degradation and human suffering worldwide. Much of the current growth in the population is unintended. Most of the poorest countries, especially in sub-Saharan Africa, are characterized by rapid population growth (1).

It is estimated that half of all conceptions are unplanned and half of the resulting pregnancies are

undesired (2). In most cases, half of the unintended pregnancies are due to failure to use contraception, and the other half to difficulties with contraceptive usage or method failure (3). In poor nations, contraceptive use is further limited by restricted access to many available methods, both economically and culturally. Undesired pregnancies result in unwanted children who disproportionately suffer from poverty and neglect (4, 5).

Women have a wide range of contraceptive choices ranging from daily oral medications to intrauterine devices implanted every 5 years to sterilization. Research and family planning organ-

izations have, for a long time, focused upon female methods of contraception because women bear a disproportionate portion of the health and economic consequences of childbearing and rearing.

The consequence of this long neglect of developing acceptable and reliable male contraceptives in poor developing countries has been the lack of or lower participation of males in family planning. Recently, it has become apparent that neglecting men in matters of family planning is a losing strategy with adverse consequences for both men and women (6).

Men around the world and in Africa are showing willingness to actively participate in family planning despite the drawbacks of the currently available male contraceptive methods. The two most common male contraceptive methods are vasectomy and condoms. The disadvantages of these methods are that vasectomy is not readily reversible and condoms have a high typical failure rate.

There are many references to plants with anti-fertility properties in the literature (7, 8) and numerous plants and their products have also been shown to possess antispermatic activities (9, 10). The aim of this study was to investigate the effect of a medicinal herb, *Acacia nilotica* (*A. nilotica*), on various male fertility parameters. Since the toxicity of this plant is not yet known, a rat model was used.

Methods

Plant collection: Dried pods of *A. nilotica* were obtained from a local forest in Blantyre, Malawi in the same winter season between May and July. Botanical identification was done at the Malawi National Herbarium and Botanical Gardens and the specimen was given voucher number 1MAL. The dried pods of the plant were grounded into homogenous thin powder using an electric grinder.

Plant crude extract preparation: The crude extract was prepared by making a suspension of 100 g of the powder in 500 ml of water to make an aqueous extract. The suspension was left to stand overnight at room temperature, with constant agitation and then filtered. The solution was concentrated in a vacuum at 40°C using a rotor vapour until crystals were formed. The crude extract yield was 6.35% (6.35 g/100 g raw material).

Animals and animal treatment: This study was approved by the Ethics Committee Board of the College of Medicine. Sexually mature male Wistar

rats (284–430 g body weight) were housed in standard rat cages and maintained under standard conditions (12 hr light/dark cycle; 25±3°C temperature; 35%–60% relative humidity), provided with a standard laboratory chow and water ad libitum. The drug and/or vehicle were administered to all animals by oral intubation.

The rats (n=40) were randomly divided into two equal groups. One group received *A. nilotica* treatment (200 mg/kg rat, daily), while the other group acted as a control. Ten animals from each group were randomly selected and sacrificed after 16 weeks. *A. nilotica* treatment was withdrawn for the remaining animals for 8 weeks before being sacrificed.

Body and organ weight measurement: After the last day of treatment, the body weight of each animal was recorded and they were killed along with control animals. Blood was collected in sterile tubes by cardiac puncture. Testis and cauda epididymis of each animal were excised from the surrounding tissue and blotted free of blood for weighing.

Sperm density and motility determination: The cauda epididymis was separated and minced using a pair of small scissors, to release the sperm into 10 ml of warmed physiological saline. The sperm suspension was placed in an incubator at 37°C for 10 min prior to total motility and progressive motility assessment. The aliquot of the sperm suspension was further diluted 5 times with warm physiological saline and then placed on Makler counting chamber and motile sperm were counted under a light microscope. Nine microscopic fields were observed per sample and averaged. Progressive and total sperm motility were expressed as a percent of motile sperm of the total sperm count. For sperm count, five counts per sample were made and averaged. Sperm count was expressed as sperm/ml of suspension solution.

Sperm morphology: Drops of rat sperm were placed on slides and smears were prepared. The smears were left to air dry before stained by Rapid Diff staining (Australian Biostain, Australia). Briefly, smears were submerged for 6 one-second dips in Rapid Diff fixative. The smears were then dipped six times for one second each in Rapid Diff Stain 1 followed by six dips in Rapid Diff Stain 2. Finally, the slides were rinsed in phosphate buffer (pH=6.8) and air dried. Morphology was assessed under light microscopy with at least 200 cells assessed per slide.

Testicular histology: The right testes from both control and experimental groups were dissected

out and fixed in formal saline. The tissues were processed for histological examination and paraffin sections were stained with hematoxylin and eosin and qualitative microscopic examination was made.

Serum testosterone: Serum concentration of total testosterone were determined using the Coat-A-Count Total Testosterone assay kit (Diagnostic Products Co., USA), per manufacturer's instruction. All samples were analyzed in a single assay. Assay sensitivity was 0.2 ng/ml.

Statistical analysis: The results were analyzed on the Prism 4 statistical program (GraphPad, USA). All data are expressed as mean \pm SEM. Data were tested for normality with the Kolmogorov–Smirnov test. One-way ANOVA (with Bonferroni post hoc test if $p < 0.05$) was used for statistical analysis. Differences were regarded statistically significant if $p < 0.05$.

Results

The sperm motility results showed that rats treated with *A. nilotica* had significantly low total motility compared to the control rats ($p < 0.05$). Withdrawing the treatment did not improve the total motility back to control level ($p < 0.05$, Table 1). Progressive motility significantly decreased in the *A. nilotica* treated group as well as the treatment withdrawn group when compared to the controls ($p < 0.05$, respectively, Table 1). Sperm concentration significantly decreased in *A. nilotica* treated group, as well as when treatment was withdrawn, compared to the control group ($p < 0.05$, respectively, Table 1). Abnormal sperm morphology significantly increased in both the treated and the treatment withdrawn groups when compared to the controls ($p < 0.05$, respectively, Table 1). On the other hand, testosterone levels were only significantly lower in the treated group when compared to the controls ($p < 0.05$, Table 1).

In the testicular histology study, seminiferous

tubules of control animals showed clear organization of cells at various stages of spermatogenesis with clear spermatozoa maturation occurring near the lumen (Figure 1). In treated rats, the seminiferous tubules had very few spermatozoa. In some tubules the lumen was filled with debris. Most of the seminiferous tubules were azoospermic (Figure 2).

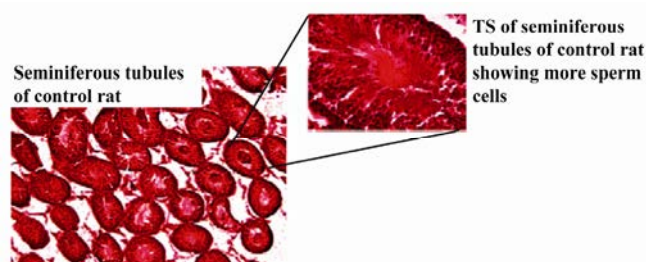


Figure 1. Transverse sections (TS) of the seminiferous tubules of control rats

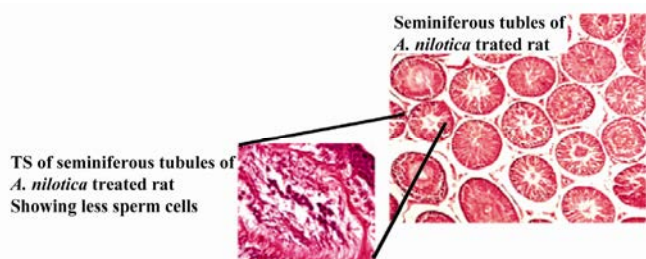


Figure 2. Transverse sections (TS) of the seminiferous tubules of rats treated with *Acacia nilotica*

Discussion

This study showed that treating rats with *A. nilotica* for 16 weeks leads to decreased total sperm motility, as well as progressive motility. Withdrawing the treatment for 8 weeks does not reverse the situation. Normal sperm morphology also seems to be adversely affected by *A. nilotica* treatment. The study also shows that *A. nilotica* treatment in rats reduces testosterone level; however, when the treatment is withdrawn, testos-

Table 1. The effects of *Acacia nilotica* treatment on total sperm parameters and plasma testosterone levels in Wistar rats

	Control (Mean \pm SEM)	<i>A. nilotica</i> treated (Mean \pm SEM)	<i>A. nilotica</i> withdrawn (Mean \pm SEM)
Total motility (%)	33 \pm 4% ^a	19 \pm 4% ^b	21 \pm 3% ^b
Progressive motility (%)	16 \pm 2% ^a	9 \pm 2% ^b	11 \pm 1% ^b
Concentration (millions/ml)	63 \pm 5 \times 10 ^{6a}	34 \pm 5 \times 10 ^{6b}	49 \pm 2 \times 10 ^{6b}
Abnormal morphology (%)	15 \pm 2% ^a	43 \pm 5% ^b	38 \pm 5% ^b
Plasma testosterone levels (pg/ml)	8220 \pm 130.6 ^a	7700 \pm 178.6 ^b	7913 \pm 192.9 ^a

a, b) Values in rows are means \pm SEM. Means followed by the same letter in the row do not differ significantly. If the letter in the same row differs from that of the control, then $p < 0.05$

terone levels return to normal values. We speculate that *A. nilotica* affects the spermatogenesis by lowering testosterone concentration. This was indicated by histological study of the testis of extract-fed animals, which exhibited partial depletion of the spermatogenic process. This finding is similar to that reported by Chinoy et al., in which Carica papaya seed extract caused androgen deprivation in male rats leading to alterations in the internal milieu of the cauda epididymis (7).

Development of effective, safe and acceptable male contraceptive is challenging. To be embraced by males, it must have no effect on libido or sexual function, and it must be reversible. The approach to the development of a male contraceptive can be either to inhibit the production of sperm, interfere with sperm function and structure, interrupt sperm transport, interrupt sperm deposition or prevent sperm-egg interaction (9, 10). Our study showed that *A. nilotica* is able to demonstrate most of these properties.

Finding an oral herbal contraceptive would allow couples control their fertility without consulting a health worker, which in turn would markedly increase the number of couples practicing family planning. Other advantages of such a contraceptive would include the familiarity rural people in Africa have with herbal medicines, the fewer side effects associated with herbal preparations, their availability from local sources, and protection of privacy (11).

Trees of *A. nilotica* in Africa are already recognized for their use in traditional medicine as well as a gum with potential food and pharmaceutical applications. It has been reported that the bark of *A. nilotica* is able to treat headaches, while the leaves can treat constipation (12).

Conclusion

From this study, it is evident that *A. nilotica* severely affects male animal fertility parameters. It is, however, not yet clear whether its antifertility effects are reversible.

Acknowledgement

This study was funded by the Wellcome Trust and DFID through the Health Research Capacity Strengthening Initiative grant.

Conflict of Interest

The author declares no conflict of interest.

References

1. Ezeh AC, Bongaarts J, Mberu B. Global population trends and policy options. *Lancet*. 2012;380(9837):142-8.
2. Henshaw SK. Unintended pregnancy in the United States. *Fam Plann Perspect*. 1998;30(1):24-9.
3. Finer LB, Henshaw SK. Abortion incidence and services in the United States in 2000. *Perspect Sex Reprod Health*. 2003;35(1):6-15.
4. Besculides M, Laraque F. Unintended pregnancy among the urban poor. *J Urban Health*. 2004;81(3):340-8.
5. Goto A, Yasumura S, Yabe J, Reich MR. Addressing Japan's fertility decline: influences of unintended pregnancy on child rearing. *Reprod Health Matters*. 2006;14(27):191-200.
6. Ringheim K. Factors that determine prevalence of use of contraceptive methods for men. *Stud Fam Plann*. 1993;24(2):87-99.
7. Chinoy NJ, D'Souza JM, Padman P. Contraceptive efficacy of Carica papaya seed extract in male mice (*Mus musculus*). *Phytother Res*. 1995;9(1):30-6.
8. Zhen QS, Ye X, Wei ZJ. Recent progress in research on Tripterygium: a male antifertility plant. *Contraception*. 1995;51(2):121-9.
9. Rao MV. Effects of alcoholic extract of Solanum xanthocarpum seeds in adult male rats. *Indian J Exp Biol*. 1988;26(2):95-8.
10. Arjmand M, Malini T, Aruldas MM, Govindarajulu P. Effect of Solasonine, A plant alkaloid, on the epididymis. I Histology and specific activity of enzymes involved in carbohydrate metabolism. *J Reprod Biol Com Endocrinol*. 1992;4:46-56.
11. Singh D, Gupta R, Saraf SA. Herbs-are they safe enough? an overview. *Crit Rev Food Sci Nutr*. 2012;52(10):876-98.
12. Mbuna J, Mhinzi GS. Evaluation of gum exudates from three selected plant species from Tanzania for food and pharmaceutical applications. *J Sci Food Agr*. 2003;83(2):142-6.