

## Ovarian Malignant Mixed Germ Cell Tumor: A Case of Unusual Presentation as Molar Pregnancy

Soheila Aminimoghaddam\*, Iman Mohseni, Azadeh Afzalzadeh, Shooka Esmaeeli

- Gynecology Oncology Department, Iran University of Medical Sciences, Tehran, Iran

### Abstract

**Background:** This research was conducted to introduce a patient with rare ovarian mixed germ cell tumor, presented as molar pregnancy.

**Case Presentation:** The patient was a 16 year old woman admitted with diagnosis of molar pregnancy. Abdominal enlargement was the only complaint. She had a large pelvic mass in physical examination. The first diagnosis was molar pregnancy due to previous ultrasonic reports and positive beta HCG. Urine pregnancy test was positive. As suction curettage was performed for her, surprisingly, the size of uterus was normal and no molar tissue was found in pathologic examination. At intraoperative ultrasound exam, an extra-uterine heterogeneous mass was found. Extra-uterine mass was confirmed by CT and MRI done after suction curettage. Mixed germ cell tumor was confirmed by histological examination after laparotomy and removing tumoral mass. Finally, she received Bleomycin, Etoposide and Cisplatin (BEP) regimen in four courses and Vincristine, Actinomycin D (Dactinomycin) and Cyclophosphamide (VAC) regimen in two courses and Diphereline for saving the other ovary.

**Conclusion:** Some young patients misinterpret the early symptoms of an ovarian neoplasm as those of pregnancy which can lead to a delay in the diagnosis.

**Keywords:** BEP, Embryonal carcinoma, Germ cell tumor, Molar pregnancy, Tumor marker, VAC, Yolk sac tumor.

**To cite this article:** Aminimoghaddam S, Mohseni I, Afzalzadeh A, Esmaeeli Sh. Ovarian Malignant Mixed Germ Cell Tumor: A Case of Unusual Presentation as Molar Pregnancy. *J Reprod Infertil.* 2016;17(2):133-136.

\* Corresponding Author:  
Soheila Aminimoghaddam,  
Gynecology Oncology  
Department, Firoozgar  
Hospital, Iran University  
of Medical Sciences,  
Valiasr Square, Tehran,  
Iran  
E-mail:  
Dr\_aminimoghaddam@  
yahoo.com

Received: May. 5, 2015

Accepted: Aug. 4, 2015

### Introduction

Germ cell tumors are derived from the primordial germ cells of the ovary. Although 20 to 25% of all benign and malignant ovarian neoplasms are of germ cell origin, only about 3% of these tumors are malignant. In the first two decades of life, almost 70% of ovarian tumors are of germ cell origin, and one-third of these are malignant (1).

In contrast to the slow-growing epithelial ovarian tumors, germ cell malignancies grow rapidly and are characterized by subacute pelvic pain related to capsular distention (2), hemorrhage or necrosis. The rapidly enlarging pelvic mass may produce pressure symptoms on the bladder or rectum, and menstrual irregularities may occur in menarcheal patients. Some young patients misinterpret

the early symptoms of a neoplasm as those of pregnancy which can lead to a delay in diagnosis. These ovarian tumors account for about 1% of ovarian malignancies. Mixed germ cell tumors contain at least two components of malignant germ cell tumors. Literature reports the most common components of such tumors as dysgerminoma (80%), EST (Endodermal Sinus Tumor) (70%), immature teratoma (53%), choriocarcinoma (20%), and embryonal carcinoma (16%). The most common combination is dysgerminoma and EST and also the most common presenting symptom in ovarian germ cell tumors is abdominal pain with or without pelvic pain that could be seen in 75% of cases (3).

Endodermal Sinus Tumors occur in patients with

a median age of 16 to 18 years (4). About one-third of the patients are in pre-menarche age at the time of diagnosis. Abdominal or pelvic pain is the most frequent initial symptom, occurring in about 75% of patients, whereas an asymptomatic pelvic mass is documented in 10% of patients. Approximately, 10% of patients present with an acute abdomen secondary to intracapsular hemorrhage, torsion and/or rupture. Ovarian germ cell tumors occur at a relatively early stage; stage I (75%) and only few cases occur at stage IV (5%) (3). Mixed germ cell tumors may secrete either  $\alpha$ FP,  $\beta$  HCG, both or neither depending on components of the tumor. These lesions should be managed with combination chemotherapy, preferably BEP (Bleomycin, Etoposide and Cisplatin).

### Case Presentation

The 16 year old, nulliparous woman was referred to Firoozgar hospital in September 2013 with diagnosis of molar pregnancy due to previous ultrasonic reports and positive  $\beta$  HCG. She married about 1 year ago and came with menstrual retardation for about 3 months. Her complaint was menstrual retardation and sudden increase in abdominal circumference size.

In her physical examination, her overall condition was good, vital sign was stable but with pallor in conjunctiva. On abdominal examination, a huge mass from pubis to umbilicus could be palpated without guarding or rebound tenderness. In pelvic examination, external genitalia was normal and in speculum examination, cervix was normal and in bimanual exam, a mass was palpable in pelvis but the differentiation between enlarged uterus or adnexal was not possible.

Differential diagnosis was the enlarged uterus due to normal pregnancy or abnormal (mole) and adnexal mass (ovarian).

$\beta$  HCG was 622 *mIU/ml* and prior to laparotomy, it rised to 918. Serum biochemistry for liver and kidney function test was normal but Hb was 9.4 *mg/dl*.

Ultra sonography revealed (4) a solid cystic mass in uterus and left ovary was not seen but right ovary was normal.

Due to retarded menstruation and positive  $\beta$  HCG and diagnosis of sonography, the gynecologist's first diagnosis was molar pregnancy.

Suction curettage and hysteroscopy were done with the diagnosis of molar pregnancy but the uterus was empty and in normal size. No evidence of molar pregnancy was seen by hysteroscopy.

Endometrial tissue was sent for pathology and the report was not neoplastic tissue, not molar tissue and proliferative endometrium.

In intra-operative abdominal ultrasound examination, a huge mass was revealed, seemed to be extra-uterine. Abdominal and pelvic CT-scan and pelvic MRI showed a large (17\*16\*10 centimeters) abdominal solid and cystic mass adjacent to anterior wall of uterus but it was not possible to distinct left ovary.

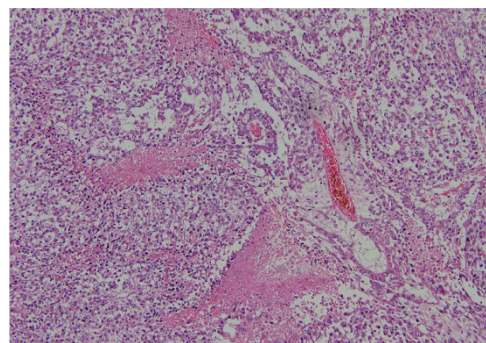
Serum tumor markers were measured as  $\beta$  HCG=622 *mIU/ml*, CA19-9: 131/4 *mIU/ml* (up to 37), CA125: 137/1 *mIU/ml* (up to 35), and alpha fetoprotein: more than 1000 *mIU/ml* (up to 5/5).

Therefore, with the diagnosis of mixed germ cell tumors, laparotomy was performed.

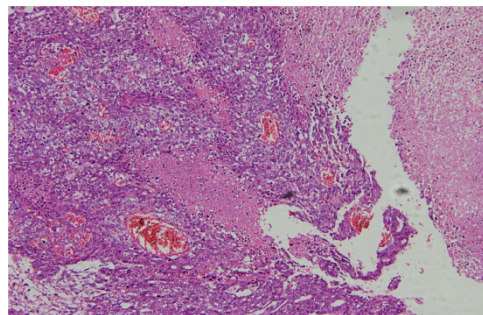
A large necrotic mass 20\*12\*6 *cm* arising from left ovary and 300 *ml* bloody ascites were found. Tumoral mass was removed intact without rupture. Unilateral salpingoophorectomy, retroperitoneal exploring and infracolic omentectomy were done. Some lymph nodes less than 2 *cm* in omentum were resected.

Mixed germ cell tumor with components of Endodermal Sinus Tumor and embryonal carcinoma were reported by histological examination (Figures 1 and 2). Omentum was free of tumor.

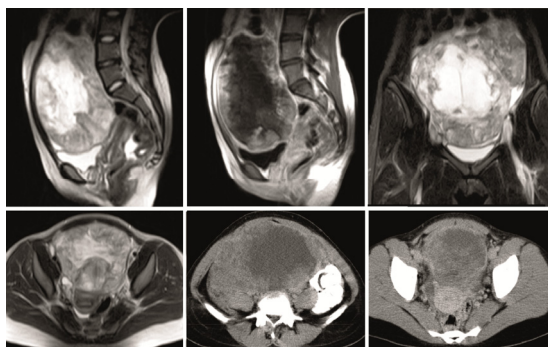
BEP regimen chemotherapy is suggested in pa-



**Figure 1.** Pathology report, embryonal carcinoma component of the ovarian germ cell tumor



**Figure 2.** Pathology report, yolk sac tumor component of the ovarian germ cell tumor



**Figure 3.** CT and MR images show a huge pelvic mass, just anterior to the uterus, with upward extension to the abdomen. The mass is solid and enhancing at periphery, and centrally necrotic zone. Uterus is obviously separated from the mass on sagittal MR images, favoring non uterine lesion. Right ovary is evident, but left ovary is obscured, suggesting left ovarian origin. Mild ascites is also seen

tients with germ cell tumor. After administration of one dose of Diphereline 3/75 mg for fertility preservation of right ovary, BEP regimen was given to the patient as follows: Bleomycin 20 mg/m<sup>2</sup> IV day 1 q 3 weeks×4, Etoposide 100 mg/m<sup>2</sup> IV daily 1-5 q 3 weeks×4, Cisplatin 20 mg/m<sup>2</sup> IV daily 1-5 q 3 weeks×4. After four courses of chemotherapy with BEP regimen, for preventing Bleomycin toxicity, two more courses of chemotherapy with VAC regimen (Vincristine, Actinomycin D and Cyclophosphamide) was given. After 4 courses of chemotherapy, αFP and βeta HCG were both decreased to normal measurement (βeta HCG <5). Two courses of VAC regimen chemotherapy were received by the patient after negative βeta HCG due to BEP regimen toxicity, Vincristine 1 mg/m<sup>2</sup> IV day 1, Actinomycin 0.5 mg/m<sup>2</sup> IV daily×5, and Cyclophosphamide 500 mg/m<sup>2</sup> IV daily×5.

About 6 months after surgery, the patient was under observation and follow up with checking tumor markers monthly and CT scanning each 3 months for at least 2 years.

### Discussion

This case is important to be reported for different causes. First, it was a rare case of mixed germ cell tumors with components of Endodermal Sinus Tumor and embryonal carcinoma which is the least common (16%) component of germ cell tumors (5). Second, it was presenting as molar pregnancy due to ultrasonic reports and positive βeta HCG.

Cases of mixed embryonal carcinoma and Endodermal Sinus Tumor (EST) are rare and reported just in a few case reports (6).

Many points are mimicking this case as a molar pregnancy; first, the patient was nulliparous and about 29% of molar pregnancies are among nulliparous patients (7).

Secondly, in previous patient's ultrasonic report, a cystic heteroechoic mass was reported in uterine cavity with the positive βeta HCG and molar pregnancy was at the top of diagnosis. The classic ultrasonographic appearance of a complete mole is described as snowstorm appearance, consisting of a heterogeneous solid collection of echoes within the endometrium (8).

The most common presenting symptom in molar pregnancy is abnormal vaginal bleeding (93.5%) but molar pregnancy can have different symptoms which make the diagnosis a complicated process (7).

To the author's knowledge, there are not many reports of germ cell tumors presenting as molar pregnancy in literature which make this case novel and important.

Mixed germ cell tumors containing Endodermal Sinus Tumor elements have elevated serum αFP levels, ranging from >100 to far higher than 1000 ng/ml. The titer of serum αFP in this case was higher than common range (9).

EMA-CO regimen (Etoposide, Methotrexate, Actinomycin, Vincristin and Cisplatin) as the first line chemotherapy in management of high risk GTN has showed good response (10). But Cisplatin containing combination chemotherapy such as BEP chemotherapy are recommended in germ cell tumors. Usually 3 to 4 courses of chemotherapy should be performed. In mixed germ cell tumors, other additional courses, after negative results of tumor markers, should be considered (11). Although chemotherapy is the principal step of patient management, it is known that the frequent negative consequence of chemotherapy (CHT) is ovarian damage and premature ovarian failure (POF) which become more important in this case with just one ovary. Functional damage to the ovary is the result of primordial follicles destruction, particularly by the action of some commonly used chemotherapeutics (12). In women, there are several methods of fertility preservation before CHT with heterogeneous outcomes. The most successful ones are ovarian stimulation and oocyte or embryo freezing and ovarian tissue harvesting and cryopreservation. One of the methods for protecting female reproductive function and for preventing ovarian damage is the administration of GnRH analogues (GrRH-a) during CHT. It is assumed

that, due to the administration of GnRH-a, the quiescent (inactive) ovary is less sensitive to the cytotoxic effects of the CHT. The protective effect of GnRH-a has been repeatedly demonstrated in animal models and also in several human studies (12).

### Conclusion

Although the diagnosis of molar pregnancy should be considered in women of reproductive age who have positive  $\beta$  HCG and sonographic report, mixed germ cell tumor also should be considered especially when there is a pelvic mass. BEP regimen should be considered as a good chemotherapy regimen for these mixed germ cell tumors. Another conclusion of this study is the usage of GnRH-a which has a protective effect for ovarian damage caused by CHT in tumor management.

### Conflict of Interest

The authors have no any conflict of interest.

### References

1. Berek JS, Hacker NF. Berek & Hacker's Gynecologic Oncology. 5th ed. New York: Lippincott Williams & Wilkins; 2009. 912 p.
2. Goyal LD, Kaur S, Kawatra K. Malignant mixed germ cell tumour of ovary--an unusual combination and review of literature. *J Ovarian Res.* 2014;7:91.
3. DiSaia PhJ, Creasman WT. Clinical gynecologic oncology. 8th ed. Elsevier Health Sciences; 2012. 342 p.
4. Pagaro PM, Gore CR, Patil T, Chandanwale Sh. Mixed germ cell tumors: report of two cases. *Med J of Dr. DY Patil Univ.* 2013;6(3):298-301.
5. Kurman RJ, Norris HJ. Malignant mixed germ cell tumors of the ovary. A clinical and pathologic analysis of 30 cases. *Obstet Gynecol.* 1976;48(5):579-89.
6. DiSaia Ph J, Creasman WT. Clinical gynecologic oncology. 6th ed. US: Mosby; 2002. 675 p.
7. Igwegbe A, Eleje G. Hydatidiform mole: A Review of Management Outcomes in a Tertiary Hospital in South-East Nigeria. *Ann Med Health Sci Res.* 2013; 3(2):210-4.
8. Lazarus E, Hulka C, Siewert B, Levine D. Sonographic appearance of early complete molar pregnancies. *J Ultrasound Med.* 1999;18(9):589-94.
9. Aoki Y, Kase H, Fujita K, Tanaka K. Dysgerminoma with a slightly elevated alpha-fetoprotein level diagnosed as a mixed germ cell tumor after recurrence. *Gynecol Obstet Invest.* 2003;55(1):58-60.
10. Ghaemmaghami F, Modares M, Arab M, Behtash N, Moosavi AZ, Khanafshar N, et al. EMA-EP regimen, as firstline multiple agent chemotherapy in high-risk GTT patients (stage II-IV). *Int J Gynecol Cancer.* 2004;14(2):360-5.
11. Berek JS, Hacker NF. Practical Gynecologic Oncology. 3rd ed. UK: Lippincott Williams and Wilkins; 2000. Chapter 12, Non epithelial ovarian and fallopian tube cancers; p. 523-51.
12. Huser M, Crha I, Ventruba P, Hudecek R, Zakova J, Smardova L, et al. Prevention of ovarian function damage by a GnRH analogue during chemotherapy in Hodgkin lymphoma patients. *Hum Reprod.* 2008;23(4):863-8.